DEVELOPMENTS IN DIFFERENT SURGICAL SUBJECTS

EDITED BY
Zeliha AYHAN & Mehmet Kenan EROL

AUTHORS
Hülya YILMAZ AK
Meral MEŞE
Nurcahya SETYAWAN
Nuring PANGASTUTI
Ozgur ALTINBAS
Şadan TUTUŞ
Tolga KOYUNCU

İKSAD
Publishing House

DEVELOPMENTS IN DIFFERENT SURGICAL SUBJECTS

EDITED BY

Zeliha AYHAN & Mehmet Kenan EROL

AUTHORS

Hülya YILMAZ AK

Meral MEŞE

Nurcahya SETYAWAN

Nuring PANGASTUTI

Ozgur ALTINBAS

Şadan TUTUŞ

Tolga KOYUNCU

İKSAD Publishing House

(The Licence Number of Publicator: 2014/31220)
TURKEY TR: +90 342 606 06 75
USA: +1 631 685 0 853
E mail: iksadyayinevi@gmail.com
www.iksadyayinevi.com

ISBN: 978-625-8007-01-5
Cover Design: İbrahim KAYA
September / 2021
Ankara / Turkey
Size = 16x24 cm

CONTENTS

PREFACE

My dear colleagues, as we all know, there are theoretical and practical developments in medicine. We are trying to learn the theoretical developments with the help of literature and books.

While creating this book, we aimed to provide the most up-to-date information. Thus, we tried to ensure that our colleagues who are in the process of continuous education can reach more up-to-date information during their busy work schedule. We are grateful to our valuable authors who wrote the chapters.

We would also like to thank all the staff of İksad publishing house who supported us in this project. Hope to meet in the light of science and knowledge always**.**

Edited by

MD Zeliha Ayhan
MD Mehmet Kenan Erol

CHAPTER 1

LIVER DYSFUNCTION AFTER CARDIAC SURGERY

[1]Dr. Hülya YILMAZ AK

[1]Istanbul Medipol Hospital, Istanbul, Turkey. hulyayilmazak@gmail.com, ORCID: 0000-0002-8682-6254

INTRODUCTION

Cardiopulmonary bypass (CPB) is a special perfusion system that has been used for approximately 70 years and enables many heart operations to be performed safely, and it is one of the indispensables of today's cardiac surgery. The first successful CPB was made in 1953 by John Gibbon. Although the off-pump method has been used frequently in cardiac surgery recently, CPB is still widely used. Although it has an important place in cardiac surgery, CPB is not innocent and causes serious adverse effects in the whole body. An acute phase reaction is induced by CPB, which is involved in the pathogenesis of various postoperative complications (Sabzi et al. , 2015). Contact of blood components with the artificial surface of the bypass circuit, presence of laminar blood flow instead of pulsatile flow, formation of global cold ischemia, ischemia-reperfusion injury, endotoxemia and surgical trauma are possible causes of Systemic Inflammatory Response Syndrome (SIRS). This inflammatory reaction may contribute to the development of postoperative complications that cause morbidity and mortality, including myocardial dysfunction, respiratory failure, renal and neurological dysfunction, bleeding disorders, alteration in liver function, and ultimately multi-organ failure (Paparella et al., 2002). Although there are studies showing that the severity of this inflammatory response that develops during and after CPB can be reduced by increasing the biological compatibility of the extracorporeal systems, filtration techniques, the use of anti-inflammatory and antioxidant agents, and

thermoregulation techniques, the information on this subject is still not clear. While most studies on postoperative complications in cardiac surgery have focused on neurological, pulmonary and renal complications, less attention has been paid to gastrointestinal side effects. Among the gastrointestinal side effects, liver complications are especially important for prognosis. It has been reported that approximately 10% of patients with CPB experience varying degrees of liver injury, which can lead to liver failure.

The liver, as the largest internal organ, receives about 25% of cardiac output. The hepatic artery supplies 20% to 25% of the blood flow to the liver, and the portal system 75% to 80%. This dual blood flow relatively protects the liver against necrosis from hypoperfusion (Poelzl et al. , 2015). However, the occurrence of a critical decrease in perfusion or a significant period of hypoxemia during CPB may abrogate protective mechanisms and result in hypoxic liver injury. The decrease in portal venous flow leads to an increase in the levels of adenosine synthesized by liver cells and Kupfer cells, due to the decrease in cardiac blood flow. Increased adenosine levels cause hepatic artery dilatation through an autoregulatory mechanism known as the 'hepatic arterial tampon response'. However, if hypotension persists for a long time, there is a critical decrease in visceral flow and severe hypoxemia develops. This leads to inadequate compensation mechanisms, and then to hepatocellular hypoxia and necrosis. Acute cardiogenic hepatitis is usually asymptomatic and clinical symptoms may appear after a period of 2–24 hours (Birrer et al. , 2007, Naschitz

et al., 1990). Serious consequences of liver failure; It consists of elevation of liver enzymes, hypoalbuminemia, impaired absorption of hepatically metabolized drugs, and disruption of coagulation factors (Karangelis et al. , 2011).

Various studies have shown the relationship between pump and clamp duration and postoperative liver function tests. The risk of liver failure increases as the pump and cross-clamp time increases (Iqbal et al. , 2015). Here, surgical experience and speed are important, and completing the operation in the most reasonable time possible is valuable in terms of protecting the liver, like other organs (Ascione et al. , 2006, Olsson et al. , 1984)).

Heart failure is common in cardiac surgery, especially in valve patients. In heart failure patients, liver dysfunction is common and is an indicator of poor prognosis (Kawahira et al. , 2021, Biegus et al. , 2019). This is because systemic disorders and diseases affect both organs due to complex cardiohepatic interactions. Cardiogenic ischemic hepatitis, also known as acute cardiogenic liver injury, is a clinical and histological syndrome characterized by a rapid and transient rise in serum transaminase levels due to the acute decrease in cardiac output, resulting in decreased hepatic blood flow. It is estimated that cardiogenic ischemic hepatitis occurs in 20-30% of patients with acute heart failure (Biegus et al. , 2019). The pathophysiological mechanisms involved in this acute liver injury are mainly related to changes in hepatic blood flow. Especially in heart failure patients, it should be prepared that liver dysfunction may occur

not only in the postoperative period but also in the preoperative period, and it should not be forgotten that preoperative liver failure is an indicator of poor prognosis.

The time taken for these changes in the splanchnic organs to reflect to the clinic and give symptoms is usually longer than 24 hours. In other words, in an adult patient undergoing open heart surgery, ischemic changes in somatic organs can only be noticed after the postoperative 24th hour and when clinical signs begin to appear (Sato et al. , 2017). This situation shows how necessary and important it is to follow the circulation in the splanchnic organs during open heart surgery. Diaz et al. also drew attention to this issue and argued that early suspicion of liver and kidney damage would help early diagnosis and early prevention (Diaz et al. , 2008, Braun et al. , 2004).

Despite advances in surgical and anesthetic techniques, as well as perioperative management, and modern CPB devices, the incidence of postoperative early hyperbilirubinemia is still high (Zakeri et al.. 2021). The incidence of postoperative hyperbilirubinemia in cardiac surgery ranges from about 8.6% to 40% (Kumle et al. , 2003). Factors such as hemolysis, hypoperfusion or systemic inflammatory response associated with CPB are thought to be involved. The effect of disease and type of surgery on postoperative hyperbilirubinemia varies (Faust et al. , 2004). Current results have shown that postoperative hyperbilirubinemia occurs more frequently in patients who receive valve replacement, especially in mechanical valves, than in patients

who have undergone coronary artery bypass graft surgery (An et al. , 2006).

Severe early (first 48 hours) ischemic liver injury (SIELI) is a rare postoperative complication after cardiac surgery. It is also referred to in the literature as 'ischemic hepatitis' or 'shock liver'. It is manifested by elevated postoperative liver enzymes (>500 IU/l alanine transaminase (ALT)). Its incidence, prognosis, pathogenesis and clinical relevance are not fully understood. It is thought to be associated with low cardiac output and increased filling pressures. SIELI has a high mortality rate after cardiac surgery. A history of heart failure, diabetes and hypertension, female gender, and postoperative low cardiac output are thought to be risk factors for the development and severity of SIELI (Raman et al. , 2002).

Diagnostic approach of liver injury is generally based on laboratory findings and clinical picture. In hepatic failure in the background of heart failure, showing dilation of the suprahepatic veins and inferior vena cava on abdominal ultrasound may be supportive. Pulmonary hypertension and impaired systolic left ventricular function are frequently seen on echocardiography. Other imaging techniques, such as magnetic resonance or computed tomography, may be used to rule out other causes of liver damage. In laboratory tests, rapid, transient increases in serum aspartate aminotransferase (AST) and alanine aminotransferase (ALT) and lactate dehydrogenase (LDH) levels occur, with peaks of 10 to 20 times normal can be observed (Chacon et al. , 2018).

Preoperative risk factors for postoperative hepatic failure include right-sided heart failure, moderate-severe tricuspid regurgitation, low ejection fraction, high preload chronic heart failure, New York Heart Association class II to IV and pulmonary hypertension (Chacon et al. , 2018).

What can be done about the treatment of these complications, which can cause serious mortality, is very limited. The entire team involved in the surgery must clearly communicate and coordinate to provide optimal care. Anesthesiologist has an important role at this stage, except that surgeons should try to keep the cross and bypass times in reasonable times. Patients with elevated liver enzymes in the preoperative period should be examined in more detail. In addition, attention should be paid to hemodynamic stability in the perioperative period (Chacon et al. , 2018). Prolonged hypotension should be avoided, appropriate perfusion should be ensured during CPB, unnecessary blood transfusion and drug use that may be toxic should be avoided. Laboratory and imaging studies should be performed preoperatively and postoperatively for any secondary cause (such as biliary obstruction, viral hepatitis, portal vein thrombosis or hematological diseases).

REFERENCES

An, Y., Xiao, Y. B., & Zhong, Q. J. (2006). Hyperbilirubinemia after extracorporeal circulation surgery: a recent and prospective study. World journal of gastroenterology, 12(41), 6722–6726.

Ascione, R., Talpahewa, S., Rajakaruna, C., Reeves, B. C., Lovell, A. T., Cohen, et al. (2006). Splanchnic organ injury during coronary surgery with or without cardiopulmonary bypass: a randomized, controlled trial. The Annals of thoracic surgery, 81(1), 97–103.

Biegus, J., Demissei, B., Postmus, D., Cotter, G., Davison, B. A., Felker et al. (2019). Hepatorenal dysfunction identifies high-risk patients with acute heart failure: insights from the RELAX-AHF trial. ESC heart failure, 6(6), 1188–1198.

Birrer, R., Takuda, Y., & Takara, T. (2007). Hypoxic hepatopathy: pathophysiology and prognosis. Internal medicine (Tokyo, Japan), 46(14), 1063–1070.

Braun, J. P., Schroeder, T., Buehner, S., Dohmen, P., Moshirzadeh, M., Grosse, J., Streit, F., Schlaefke, A., Armstrong, V. W., Oellerich, M., Lochs, H., Konertz, W., Kox, W. J., & Spies, C. (2004). Splanchnic oxygen transport, hepatic function and gastrointestinal barrier after normothermic cardiopulmonary bypass. Acta anaesthesiologica Scandinavica, 48(6), 697–703.

Chacon, M. M., & Schulte, T. E. (2018). Liver Dysfunction in Cardiac Surgery - What Causes It and Is There Anything We Can Do?. Journal of cardiothoracic and vascular anesthesia, 32(4), 1719–1721.

Diaz, G. C., Moitra, V., & Sladen, R. N. (2008). Hepatic and renal protection during cardiac surgery. Anesthesiology clinics, 26(3), 565–590.

Faust, T. W., & Reddy, K. R. (2004). Postoperative jaundice. Clinics in liver disease, 8(1), 151–166.

Iqbal UJ, Hanif MI, Iqbal N. (2015). Effect of cardiopulmonary bypass on liver function in patients undergoing coronary artery bypass grafting. Biomedica. 31:27–9.

Karangelis D, Oikonomou K, Koufakis T. (2011). Gastrointestinal complications following heart surgery. Eur J Cardiovasc Med 1(4):34-37.

Kawahira, M., Tamaki, S., Yamada, T., Watanabe, T., Morita, T., Furukawa, Y., et al. (2021). Prognostic value of impaired hepato-renal function and liver fibrosis in patients admitted for acute heart failure. ESC heart failure, 8(2), 1274–1283.

Kumle, B., Boldt, J., Suttner, S. W., Piper, S. N., Lehmann, A., & Blome, M. (2003). Influence of prolonged cardiopulmonary bypass times on splanchnic perfusion and markers of splanchnic organ function. The Annals of thoracic surgery, 75(5), 1558–1564.

Naschitz, J. E., Yeshurun, D., & Shahar, J. (1990). Cardiogenic hepatorenal syndrome. Angiology, 41(11), 893–900.

Olsson, R., Hermodsson, S., Roberts, D., & Waldenström, J. (1984). Hepatic dysfunction after open-heart surgery. Scandinavian journal of thoracic and cardiovascular surgery, 18(3), 217–222.

Paparella, D., Yau, T. M., & Young, E. (2002). Cardiopulmonary bypass induced inflammation: pathophysiology and treatment. An update. European journal of cardio-thoracic surgery : official journal of the European Association for Cardio-thoracic Surgery, 21(2), 232–244.

Poelzl, G., & Auer, J. (2015). Cardiohepatic syndrome. Current heart failure reports, 12(1), 68–78.

Raman, J. S., Kochi, K., Morimatsu, H., Buxton, B., & Bellomo, R. (2002). Severe ischemic early liver injury after cardiac surgery. The Annals of thoracic surgery, 74(5), 1601–1606.

Sabzi, F., & Faraji, R. (2015). Liver Function Tests Following Open Cardiac Surgery. Journal of cardiovascular and thoracic research, 7(2), 49–54.

Sato Y, Yoshihisa A, Kanno Y, Watanabe S, Yokokawa T, Abe S, Misaka T, Sato T, Suzuki S, Oikawa M, Kobayashi A, Yamaki T, Kunii H, Nakazato K, Saitoh SI, Takeishi Y. Liver stiffness assessed by Fibrosis-4 index predicts mortality in patients with heart failure. Open Heart 2017; 4: e000598.

Yamada, T., Ochiai, R., Takeda, J., Kikuchi, H., Ishibashi, M., & Watanabe, K. (2005). Off-pump coronary artery bypass attenuates transient hepatocellular damage after myocardial revascularization. Journal of cardiothoracic and vascular anesthesia, 19(5), 603–607.

Zakeri, S., Vafaey, H., Banihashem, N., Alijanpour, A., Gholinia, H., & Behzad, C. (2021). Evaluation of liver function tests after coronary artery bypass surgery (CABG). Caspian journal of internal medicine, 12(1), 45–52.

CHAPTER 2

LAPAROTOMY SIGMOID COLON VAGINOPLASTY SURGERY

Nuring PANGASTUTI[1] & Nurcahya SETYAWAN[2]

[1] (Nuring Pangastuti, MD, Obgyn, Urogynaecology Consultant)
Orcid id: https://orcid.org/0000-0002-0112-6508
Department of Obstetrics and Gynaecology, Faculty of Medicine Public Health and Nursing, Universitas Gadjah Mada, Yogyakarta Indonesia
[2] (Nurcahya Setyawan, MD, Surgeon, Digestive Surgeon Consultant)
Department of Surgeon, Faculty of Medicine Public Health and Nursing, Universitas Gadjah Mada, Yogyakarta Indonesia

INTRODUCTION

Female genital congenital anomaly

Congenital malformations of the female genital tract were defined as embryological Müllerian or paramesonephric ductal malformations. Mullerian duct interruption can result in the formation of Mullerian Duct Anomalies (MDA), and the anomalous features can include vaginal agenesis, uterine agenesis, or renal agenesis (Chandler *et.al*.2009). In the general population, the prevalence of Müllerian duct anomalies is 9.8% and is more common in nulliparous women (Dreisler *et.al.* 2014).

The female reproductive tract develops from a pair of Müllerian ducts that form the fallopian tubes, uterus, cervix and upper two-thirds of the vagina (Chandler *et al*. 2009). Congenital malformations occur when there is agenesis of one or both ducts, or the absence of fusion or reabsorption of the septals between the ducts. Vaginal anomalies often occur together with uterine anomalies (Spencer *et al*. 2012; Grimbizis & Campo, 2010). MDA is an uncommon congenital anomaly, the clinical picture can vary widely, and is generally treatable by surgical procedures (Grimbizis & Campo, 2010).

Mullerian syndrome or agenesis is described as a congenital absence of a uterus and vagina in individuals with a normal female genotype, normal secondary sexual characteristics, and normal ovaries (Beksac *el.al*. 2011). Until now, the cause of this abnormality is not fully understood, but failure of Müllerian duct canalization in the embryological phase of female fetal development is thought to be the

main mechanism (Both *et.al*, 2018). Müllerian malformations have various manifestations of phenotypic defects such as cervicovaginal agenesis and vaginal agenesis/cervical atresia which are thought to result from Müllerian tubercle developmental defects (Minami *et.al.* 2019).

The vaginal canal can be very short, it may even be just a dimple-like shape under the urethra. The ovaries, given their separate embryological sources, usually have normal anatomical structure and function although they can be found in unusual locations (ACOG, 2018). The external genitalia appear normal, the patient usually has normal reproductive function and reaches puberty showing signs of thelarche and normal pubarche. Complaints often occur in adolescence due to complaints of primary amenorrhea, either with abdominal pain or not. In this situation, Müllerian aplasia is the most likely diagnosis (Herlin *et.al*. 2020). In some cases, severe abdominal pain occurs due to menstrual blood not being able to flow out of the normally functioning uterus (Creatsas & Deligeoroglou, 2010).

Vaginal agenesis is a rare congenital anomaly, occurring in approximately 1 in about 4000-4500 women, involving the complete or partial absence of the uterus, vagina, or both. The remaining uterus may or may not be present in the form of a uterine horn, with or without an endometrial cavity. The vagina can be a short canal or a dimple under the urethra (Both *et.al*. 2018; Dabaghi *et.al*. 2019; Pan, 2017; The American College of Obstetrician and Gynecologist, 2018).

Vaginal agenesis can usually be detected in postpubertal girls as primary amenorrhea, despite having an XX karyotype and normally functioning ovaries (Both *et.al*. 2018; The American College of Obstetrician and Gynecologist, 2018; Dabaghi *et.al*. 2019). The most common etiology is Mayer-Rokitansky-Küster-Hauser (MRKH) syndrome, which is divided into two classifications. The first classification is characterized by aplasia of the uterus and upper vagina, while the second classification is associated with anomalies in other organ systems including the urinary tract, skeleton, central nervous system, and heart (Herlin *et.al.* 2020; Morcel & Camboriex, 2007; Pan, 2017).

Classification of female genital congenital anomaly

The most common classification system that developed and had been used were by American Society for Reproductive Medicine (ASRM) and European Society of Human Reproduction and Embriology (ESHRE) and European Society for Gynaecological Endoscopy (ESGE). ASRM divides uterine malformations into seven main groups (The American Fertility Society, 1988). This system does not include vaginal anomalies and certain combined anomalies. Two European societies, ESHRE and ESGE have introduced a classification based on the anatomy of the female genital tract and malformations of the uterine cervix and vagina (Grimbizis *et.al*.2013).

The following is a classification of female genital congenital anomalies which include congenital abnormalities in the uterus, uterine cervix and vagina (Figure 1 and 2):

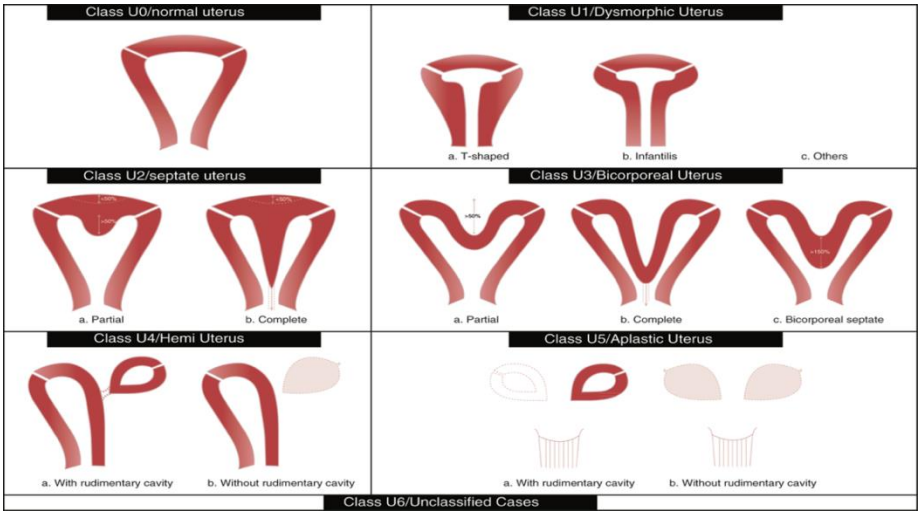

ESHRE/ESGE classification
Female genital tract anomalies

	Uterine anomaly		Cervical/vaginal anomaly
	Main class	***Sub-class***	***Co-existent class***
U0	Normal uterus		
U1	Dysmorphic uterus	**a.** T-shaped **b.** Infantilis **c.** Others	
U2	Septate uterus	**a.** Partial **b.** Complete	
U3	Bicorporeal uterus	**a.** Partial **b.** Complete **c.** Bicorporeal septate	
U4	Hemi-uterus	**a.** With rudimentary cavity (communicating or not horn) **b.** Without rudimentary cavity (horn without cavity/no horn)	
U5	Aplastic	**a.** With rudimentary cavity (bi- or unilateral horn) **b.** Without rudimentary cavity (bi- or unilateral uterine remnants/aplasia)	
U6	Unclassified malformations		

C0	*Normal cervix*
C1	*Septate cervix*
C2	*Double 'normal' cervix*
C3	*Unilateral cervical aplasia*
C4	*Cervical aplasia*
V0	*Normal vagina*
V1	*Longitudinal non-obstructing vaginal septum*
V2	*Longitudinal obstructing vaginal septum*
V3	*Transverse vaginal septum and/or imperforate hymen*
V4	*Vaginal aplasia*

U ***C*** ***V***

Associated anomalies of non-Müllerian origin:

Drawing of the anomaly

Figure 1 and 2. ESHRE/ESGE classification of uterine anomalies: schematic representation (Class U2: internal indentation >50% of the uterine wall thickness and external contour straight or with indentation <50%, Class U3: external indentation >50% of the uterine wall thickness, Class U3b: width of the fundal indentation at the midline >150% of the uterine wall thickness) (Grimbizis *et.al*. 2013).

Neovaginal reconstructive surgery

The reconstruction of a neovagina is indicated in the cases of congenital absence of the vagina, genetic sexual ambiguity and vaginal loss resulting from gynaecologic cancer or post traumatic injury (Nowier *et.al*. 2012). There are a variety of techniques that can be used for the management of vaginal agenesis, both surgically and non-surgically (Carrard *et.al.*2012, Handaya *et.al.* 2020). While the nonsurgical techniques are based on mechanical dilation or self-dilatation, the surgical methods involve intra-abdominal traction or the use of allogenic or autogenic transplants (Kölle *et.al.*2019). Another article states that surgical vaginoplasty is divided into the following categories; (1) fabrication of the perineal pouch (Williams vaginoplasty and its various modifications) (2) the pressure method (Vecchietti vaginoplasty procedure) and (3) lining the neovaginal space with various materials (Handaya *et.al.* 2020).

Neovaginal surgical procedure aims to create a vaginal canal that can function in penile penetration during sexual activity, and serves to drain menstrual blood in cases with a functional uterus. Currently, there is no expert consensus on the best vaginoplasty surgical

technique that can provide the best anatomical and functional results for patients (Pangastuti *et.al.* 2020).

Sigmoid colon vaginoplasty

One technique that can be used in the management of vaginal agenesis is sigmoid colon vaginoplasty. This procedure uses a sigmoid graft to create a neovagina. The aim of this operation is to make the anatomy and function of the neovagina as identical as possible to the normal vagina, including sexual function (Zhang *et.al*. 2019).

The sigmoid colon was chosen because it can create an excellent and aesthetically vaginal canal with a good length that can function both in sexual activity considering the patient who is still in her reproductive age and also as an access of menstrual blood outflow tract for the patient with functional uterus (Pangastuti *et.al.* 2020; (Zhang *et.al*., 2019). Anatomically, the sigmoid colon is in the position closest to the perineum, and generally can be pulled easily into the perineum along with all of its vasculature. The sigmoid colon also has the appropriate diameter to function as the normal vaginal diameter (Nowier *et.al*. 2012). There is no need to dilate regularly which makes the patient uncomfortable and also the sigmoid itself can provide natural lubrication. When the surgery is performed before puberty, the sigmoid graft can grow as the child's physical growth grows, so that it fits the patient's current situation. Surgical sigmoid vaginoplasty also carries minimal risk of stenosis. This surgical therapy is expected to form a neovagina that can function for the rest of the patient's life (Handaya *et.al.* 2020; Pangastuti *et.al*. 2020).

Several segments of the intestine either sigmoid, ileum or ileocecal segment can be used to form a neovagina. In pediatric patients, the use of the ileocecal segment should be avoided because it can result in metabolic disorders (Nowier *et.al*., 2012). When using the ileum, the mucosa is more fragile, so it is easy to bleed during sexual activity. The production of ileal mucus is more but it lacks the ability as a lubricant when compared to the sigmoid colon. Vaginal stenosis is also found to be more common with ileal use than sigmoid vaginoplasty (Hensle & Dean, 1992; Imparato, *et.al*., 2009; Nowier, *et.al*., 2012).

Colon Preparation

It is very important to prepare the condition of the colon itself in order to obtain a satisfactory surgical result, especially to avoid infection and dehiscence of the surgical wound. This preparation has been started since a few days before surgery, at least 2-3 days before surgery with the patient being hospitalized (Mohamed, *et.al*., 2011).

A diet of porridge can be given to the patient during this time, not eating foods that are difficult to digest and require hard work from the intestines, especially the colon. It is recommended to drink only mineral water, do not drink coffee, drinks containing soda, and others. Prior to surgery, fasting for food and drink is carried out for at least 8 hours before surgery.

Efforts to clean the intestines are done by giving fleet phosphosoda at night, or about 12 hours before surgery. Followed by the use of enemas through the anorectal in a few hours before surgery. It is

hoped that the entire contents of the intestine (feces) can come out through the process of defecation, so that all parts of the intestine can be in a clean state during surgery.

Use of antibiotics

In cases with good condition and ready to undergo surgery, the use of antibiotics was started before surgery in the form of prophylactic antibiotics. Broad-spectrum antibiotics can be used, in the form of intravenous injection or drip by infusion at about 30-60 minutes before the operator performs the first surgical incision in the abdomen. It is important to ensure that the patient does not have an allergy to the antibiotics used.

The types of antibiotics that can be used in colorectal surgery prophylaxis are (Ongom & Kijjambu, 2013):

Drug	**Specific characteristic of prophylactic advantage**
Parenteral	
Ampicillin-Sulbactam	Extended antibacterial activity to include β-lactamase-producing strains, including Bacteroidesfragilis; Sulbactam high tissue concentrations – greater stability and less induction of chromosomal β-lactamases than clavulanic acid.
Aztreonam	Resistant to many plasmid-mediated β-lactamases; a monobactam – better stability against many β-lactamases.
Cefazolin	Very effective in clinical trials.
Cefoxitin	A cephamycin; resistant to many plasmid-mediated β-lactamases.

Drug	**Specific characteristic of prophylactic advantage**
Cefotetan	A cephamycin; resistant to many plasmid-mediated β-lactamases.
Ceftriaxone	Extended-spectrum cephalosporins; effective against most enteric gram-negative bacilli.
Ciprofloxacin	More potent against gram-negative organisms than other fluoroquinolones; most active quinolone against Pseudomonas aeruginosa.
Clindamycin	Useful against some MRSA infections; anti-anaerobic.
Ertapenem	A carbapenem; activity retained against most strains with extended-spectrum β-lactamases.
Gentamicin	Bactericidal; wide-spectrum of use especially against gram negatives.
Metronidazole	Excellent anti-anaerobic activity; adjunct to other drugs.
Oral	
Erythromycin base	In combination with neomycin, it is comparably effective, in clinical trials, as IV ceftriaxone-metronidazole preparation in colorectal surgery.
Metronidazole	Reduces anaerobic bacteria load.
Neomycin sulphate	Adjunct to erythromycin.

Cefazolin is most often used for surgical prophylaxis in patients without a history of beta-lactam allergy, a history of MRSA infection, or when consideration is given to surgical sites where the organism is most likely not covered by cefazolin alone, such as in colorectal surgery. The dose used is 2 grams for adult patients, and reaches 3 grams in patients weighing more than 120 kilograms. For patients requiring additional microbe coverage like this sigmoid vaginoplasty surgery, multiple options may be considered, including cefazolin plus metronidazole, cefoxitin, or ertapenem (Crader & Varacallo, 2021).

Repeated doses of intraoperative antibiotics are necessary to ensure that serum and tissue antibiotic concentrations remain at adequate doses, particularly when the duration of surgery exceeds two half-lives of the drug, or when the blood loss is greater than 1500 mL. The dose is usually repeated every 2 to 4 hours intraoperatively, from the time of preoperative dosing. This of course does not apply to patients with renal impairment who have a longer half-life of antibiotics (Crader & Varacallo, 2021; MacGowan, *et.al*., 2020 Ongom & Kijjambu, 2013).

Sigmoid vaginoplasty, which includes colorectal surgery, involves contamination of intestinal products in the abdominal cavity and other organs. In this surgery, further antibiotics need to be given for at least 5 days after prophylactic antibiotics (MacGowan, *et.al*., 2020).

Evaluation must be carried out on the general condition, condition of the surgical wound, and the results of laboratory tests as an evaluation parameter for the presence or absence of postoperative infection. Replacement of antibiotics is possible in the case of suspected

infection or sepsis which requires other types of antibiotics according to the results of the culture and sensitivity test of at least the patient's blood and urine. Culture and sensitivity test can also be performed with samples from the surgical wound if a surgical wound infection is suspected.

How to ensure that a sigmoid graft can be obtained from the patient's sigmoid colon?

Several examinations need to be performed to ensure that part of the patient's sigmoid colon can be used as a sigmoid graft. Generally, a sigmoid colon is required as a graft, 15-20 centimeters long, with a colon diameter of about 3 centimeters. The sigmoid graft must have good vascularity, so that its life is guaranteed for all time, avoiding the risk of tissue damage or death after being implanted as a neovagina in the rectovesical space area.

Pre-surgical examination was carried out including taking a history related to the presence or absence of a history of gastrointestinal disease, especially the intestine, for example a history of ileus, appendicitis, colitis, proctitis, all infections and pathologies in the anorectal area, a history of surgery for intestinal tumors, or previous cutting and grafting of the intestine.

Physical examination of the abdomen was examined for the presence or absence of a tumor mass, or other abnormalities suspected of involving the intestines. An anorectal examination is necessary to ensure that there is no pathology in the anus and rectum that could affect the surgical process in order to obtain a sigmoid graft.

Additional colon in-loop examination should be performed, to determine the length and diameter of the colon, and ensure that there is no pathology in the intestinal area, especially the colon. Radiological examinations for abdominal radiographs and intravenous pyelography were performed to ensure that the entire abdominal and pelvic cavities and urinary tract were within normal limits. If other abnormalities are found, immediately evaluate whether these conditions affect surgery or not. A Magnetic Resonance Imaging (MRI) or Computerized Tomography (CT) scan with contrast is required as the gold standard for female genital congenital anomaly. It should be noted that the presence of a congenital abnormality in the female genitalia should encourage the doctor to evaluate the patient's overall condition, whether there are other congenital abnormalities that occur concurrently.

It is difficult to examine blood vessels specifically to determine which vascularization will be chosen to support the sigmoid graft, due to the large number of vascular that supply the entire intestinal area, as well as various considerations that must be made when cutting the colon to be used as a sigmoid graft.

Laparotomy abdominal incision procedure

An abdominal incision is made in the midline, generally from the level of the pubic symphysis to the lower edge of the umbilicus. This incision allows the operator to view all the intra-abdominal and pelvic organs, which is important for identification at the start of surgery. This choice of incision also facilitates the use of both permanent and

mobile retractors during surgery. If an expansion of the operating field is required, the incision can be easily raised until it reaches the upper edge of the umbilicus and is even more cranial.

Pfanensteel incision can be made but it will be very difficult for the operator to mobilize the bowel. The risk of extending the Maylard incision or adding to the midline incision is a condition that can occur and should be considered before performing surgery.

Sigmoid colon mobilization procedure

The first procedure that must be performed to obtain a sigmoid graft is to ensure that the entire area of the sigmoid colon is sufficiently mobile, free of adhesions. All adhesions must be removed, the tissue mobilized as much as possible.

Mobilization of the mesocolon up to the splenic flexure area, as well as the area of the base of the vascular pedicle, should be carried out in order to obtain a sigmoid colon that is mobile enough to be placed as a neovagina in the rectovesical space. The sigmoid graft will then be pulled medially inferiorly, until it reaches the vaginal vestibule area in the perineum. In conditions without a uterus, these considerations suffice here. However, in the condition of patients who have a uterus, the sigmoid graft will be anastomosed to the uterus so that it requires a more mobile state.

Selecting part of the sigmoid colon to be used as a sigmoid graft

It must be determined that the procedure for excision of a portion of the sigmoid colon to be used as a sigmoid graft is only performed after

the rectovesical space area has been properly created, there is no injury to other organs, there is no bleeding or it has been well controlled, and a sufficient diameter has been established to place the sigmoid graft.

If the rectovesical space area cannot be created properly, or complications occur during its creation, it is not wise to excise the sigmoid colon to form a sigmoid graft. In situations where rectovesical space cannot be created at this time, all bowel surgery including sigmoid colon surgery should be postponed.

In the sigmoid colon to be used as a graft, the operator should be able to see the entire vascular pedicle of the sigmoid colon, as well as the vascular drummond. This procedure can be performed by elevating the sigmoid colon, placing a sufficiently bright light from the back side of the sigmoid colon (light from the front of the operator, directed to the sigmoid colon), so as to display all the vascular pedicles of the sigmoid colon.

After all vascular pedicles are displayed, attempt to mobilize the sigmoid colon medially inferiorly, towards the perineal area. Try this mobilization trial several times, until you can determine which vascular pedicle to use as the vascular pedicle for the sigmoid graft.

Generally, the blood vessel pedicle used is the sigmoid artery and vein. There is some variation in the location of the sigmoid artery and vein, in the middle, or more proximally, or more toward the distal sigmoid colon.

There must be at least one vascular pedicle that is sufficiently well vascularized to provide life for the sigmoid graft when it is used as a neovagina. The part of the sigmoid colon that has good vascularity can be identified from its fresh reddish color when clamped using intestinal clamps on sigmoid colon and mesocolon sigmoid to be cut, accompanied by palpable and visible arterial pulsations in the vascular pedicles and their branches. If the vascularization is not good then the sigmoid colon will be bluish in color, without arterial pulsation.

After determining the vascular pedicle to be used, it can only be decided on which side of the sigmoid colon to be cut, with a length of about 15-20 centimeters. The proximal and distal ends of the sigmoid graft are not always at the same distance from the vascular pedicle. In one case the proximal end may be closer to the vascular pedicle and the distal end further away from the vascular pedicle, and vice versa. Some things to consider are the distance of the vascular pedicle from the perineum, mobilization of the sigmoid mesocolon, maximal mobilization that can be done without vascular tension, and the presence or absence of the uterus.

If the sigmoid colon has been excised, good vascularity can be seen from the presence of bleeding in the excised proximal and distal ends of the sigmoid colon. Evaluation for a while needs to be done to ensure that the sigmoid graft is well vascularized and safe enough to maintain its function as a neovagina.

Figure (A): Isolation of 12-15 cm of sigmoid colon, (B): The bowel segment has been positioned to be anastomosed to vulvar mucosa.

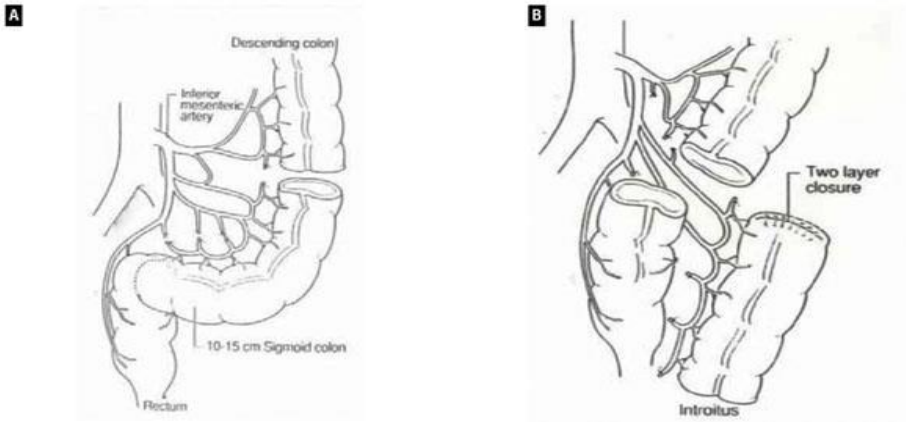

Figure 3A. Isolation of sigmoid colon; 3B. The sigmoid graft has been positioned to be anastomosed to vulva (Pan, 2017).

Anastomosis of the cut ends of the sigmoid colon can be done using manual sutures, or it is much easier to use a disposable curved stapler intraluminal gastrointestinal anastomosis (GIA) of the appropriate size. For example with a Curved Detachable Head (CDH), the diameter of the head has a size of 21, 25, 29 or 33 mm (by Ethicon Endo - Surgery, one Johnson & Johnson Company) in which a grip is inserted from the anus, with moderately minimal anal dilation has been able to incorporate the stapler head in the proximal bowel (Fahmy, *et al*., 2011).

The use of a surgical stapler to make anastomosis intestines shortens the operation time by 60-120 minutes, with an average of 75 minutes. Thus the length of stay in hospital is also reduced to about 5-12 days, with an average of 7 days. Complications in the intestines can also be

reduced as much as possible until there are no complications (Fahmy, *et al*., 2011).

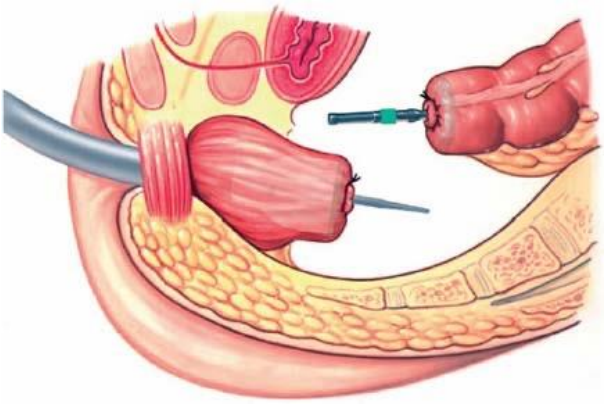

Figure 4. Curved disposable intraluminal GIA stapler for bowel (Fahmy, *et al*., 2011).

Sigmoid graft washing

Before being placed in the rectovesical space, the sigmoid graft must be cleaned first. The trick is to use a normal saline flow from one end of the graft to the other. This procedure can use a 50 mL syringe to drain normal saline, repeated until the liquid is clear, and no digestive products are left behind.

Do not perform the procedure of scrubbing or removing dirt on the mucosal surface of the sigmoid graft, or cleaning it with gauze. This action can result in damage to the sigmoid graft mucosa, which can lead to postoperative adhesions.

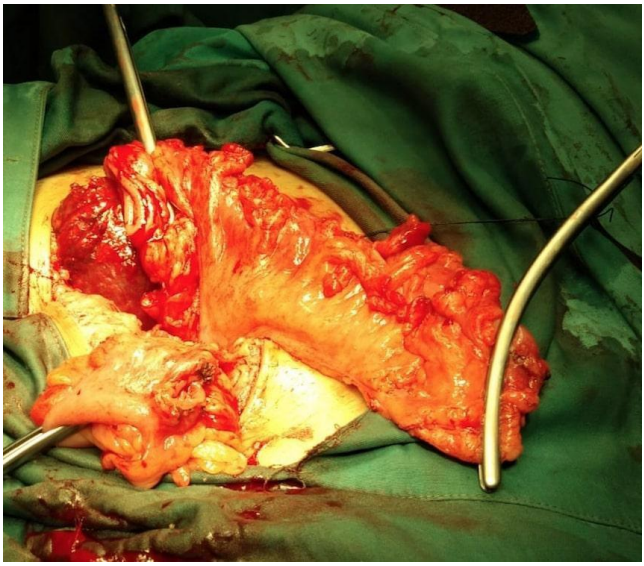

Figure 5. The sigmoid graft (Pangastuti, 2020)

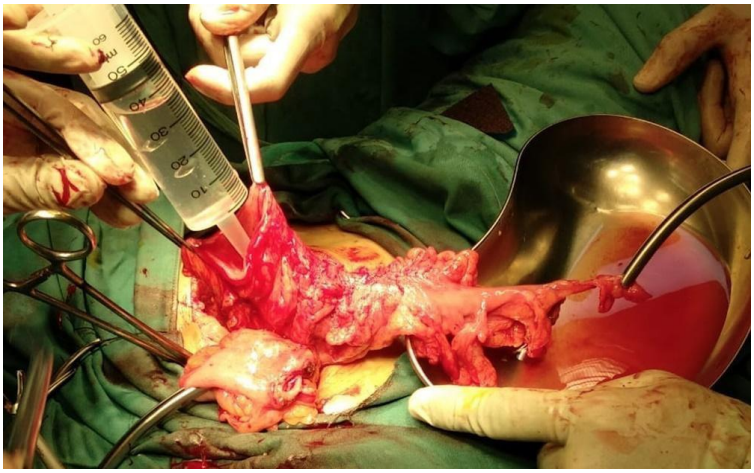

Figure 6. Sigmoid graft washing with saline before being placed in rectovesical space (Pangastuti, 2020)

Placement of the sigmoid graft in the rectovesical space

The placement of the sigmoid graft is carried out after an anastomosis has been performed on the sigmoid colon which has been partially

removed to be used as a sigmoid graft, and the lumen of the sigmoid graft is washed.

Several considerations must be made in order to properly place the sigmoid graft in the rectovesical space as a neovagina. The sigmoid graft can be placed in an isoperistaltic or contraperistaltic direction. Isoperistaltic means that the sigmoid graft is placed in the rectovesical space in the direction of the colon when it is cut. The proximal end of the sigmoid graft is on the proximal side of the neovagina (can be closed with interrupted absorbable sutures and fixed to the vestigial remnants of the Mullerian ducts or to the uterosacral ligaments in cases without a uterus, or anastomosed with the uterus), and the distal end of the sigmoid graft remains as the distal end of the sigmoid graft implanted in the perineum (Fahmy, *et al*., 2011). Contraperistaltic means making the proximal end of the sigmoid graft the distal end of the neovagina implanted in the perineum, and making the distal end of the sigmoid graft the proximal end of the neovagina. This procedure is followed by rotating the sigmoid graft on the vascular pedicle and overlying mesocolon, clockwise or counterclockwise, to avoid straining the vascular pedicle. The distance of the rotation can be only a few degrees, but under certain conditions it can reach 180 degrees.

The edge of the sigmoid graft as a neovagina can be inserted into the rectovesical space in the following ways:

-Installing the tile suture on the right and left lateral side of the end of the sigmoid graft which is the distal end of the neovagina, then pulling the suture thread through the rectovesical space on the perineal side.

-Using bowel clamps inserted in the rectovesical space from the perineal side, until it reaches the pelvic cavity, then clamped on the end of the sigmoid graft which will become the distal end of the neovagina and pulling it towards the perineum.

It is important to note that the sigmoid graft should not be twisted, because it can interfere with vascularization and result in the death of the sigmoid graft tissue. The operator must pay attention to the location of the taenia and mesocolon, and place them in the same direction throughout the placement of the sigmoid graft in the rectovesical space. To facilitate the entry of the sigmoid graft into the rectovesical space, the side of serous surface of the sigmoid graft can be pre-greased with sterile lubricant. In addition, the appendices of the sigmoid colon carried on the sigmoid graft can be reduced so that the outer diameter of the sigmoid graft is more in line with the diameter of the rectovesical space. The operator should assist the entry of the sigmoid graft into the rectovesical space by gently pushing it from the side of the abdominal cavity toward the perineum.

It is important to evaluate the condition of the sigmoid graft after it is placed in the rectovesical space as a neovagina. Vascularization must continue properly, so that the neovagina can function properly throughout the patient's life.

Anastomosis sigmoid perineum

The side of the sigmoid graft placed as the distal end of the neovagina should be sutured to the perineal side or the outer edge of the rectovesical space. The stitches are interrupted, one layer, using a

slow absorbent synthetic thread of size 3-0 or a maximum of 2-0. The sutures should not be too tight, which will result in impaired vascularity in the area where the sigmoid graft is attached. Avoid making too many stitches, only 4-6 interrupted stitches. Continuous suture should also be avoided, because it will create a loop of suture at the mouth of the neovagina, which after healing can lead to a stenotic condition.

Occasionally there is a condition in which the edge of the sigmoid graft that is the distal end of the neovagina cannot reach the edge of the vaginal vestibule. In this condition, it should not be forced to pull the sigmoid graft to try to reach the outer side of the perineum, because this procedure can cause tension of the vascular pedicle that can harm the sigmoid graft. If the maximum distal end can only reach less than 3 centimeters from the vaginal vestibule, sutures can be made in that area, then the rectovesical space area that has not been covered by the sigmoid graft can be closed with a graft from the skin in the perineal area.

On the other hand, where the side of the sigmoid graft that becomes the distal end of the neovagina reaches far beyond the vaginal vestibule, it can be pulled proximal to the abdominal cavity, so that the distal end of the neovagina is right in the vaginal vestibule, and sutures are made in that area. To avoid prolapse in this case, the sigmoid graft can be sutured at the proximal end of the rectovesical space on the side in the abdominal cavity, so that the sigmoid graft will not sag distally. Neovaginal prolapse can also be prevented by

selecting the correct length of the bowel segment and fixing it properly to the sacral promontory (Pan, 2017).

Cosmetic appearance needs to be considered when suturing the perineal sigmoid anastomosis, so that the anatomical description of the perineal vulva can be well received by the woman concerned. A good cosmetic appearance will affect the patient's self-confidence, so that it can improve the perspective of herself as a normal woman, as well as the quality of life in general.

Uterosigmoid anastomosis

Uterosigmoid anastomosis can be performed by several procedures, depending on the shape and position of the uterus, the presence or absence of the uterine cervix, and the position of the sigmoid graft against the uterus. In a relatively normal uterus in both size and location, the incision can be made on the posterior side of the uterus, on the lowest side of the uterus. This should be attempted to ensure that all menstrual blood during menstruation can flow out immediately through the anastomotic sigmoid graft. The incision is made in the direction of the median line, with a length of about 3-5 centimeters, so that the entire diameter of the side of the sigmoid graft which is the proximal end of the neovagina can be inserted and sutured on the inside of the incised uterine wall, until it reaches the endometrial layer.

The suturing is done using slow absorbent synthetic thread, size 3.0 to a maximum of 2.0, with interrupted sutures. The first layer of suture is placed on the innermost side of the uterus, with sutures that do not

damage the intestinal mucosa of the sigmoid graft or uterine endometrium. The second layer of suture was also performed with the same suturing technique, the same type and size of thread, further attaching the serous side of the sigmoid graft to the uterine wall.

Uterosigmoid anastomosis can be performed in an end-to-side, or side-to-side. If the entire side of the sigmoid graft which is the proximal end of the neovagina can easily enter the uterus through the incision that has been made, then an end-to-side procedure can be easily performed. In conditions where the side of the sigmoid graft which is the proximal end of the neovagina cannot be inserted properly, for example because the position of the sigmoid graft is not in the same position as the uterus, or when there is a risk of straining the vascular pedicle of the sigmoid graft, a side-to-side procedure can be performed. The side of the sigmoid graft which is the proximal end of the neovagina is closed, then a new incision is made on the lateral or anterior side of the sigmoid graft, at a height or position according to the height of the uterine incision.

In the case of a uterus without a uterine cervix, generally the uterus will tend to be more rounded in shape, an incision for the uterosigmoid anastomosis site should be made on the lowest side of the uterus.

In the case of a uterus with a uterine cervix, the uterine incision should be made on the posterior side of the uterus until it reaches the internal uterine os in the area of the uterine cervix. In this procedure, the anterior edge of the sigmoid graft which is the proximal end of the

neovagina is sutured to the anterior uterine cervix, then the sutures are placed following the shape of the opened uterine incision.

In the case of right or left hemiuterus, uterine incisions can be made on the right or left posterolateral side, adjusting the location of the sigmoid graft to the uterus, taking into account the ease of menstrual blood flow during the menstrual phase.

In cases where there is an anatomical abnormality of the uterus such as a didelphys uterus or uterine septum, correction can be made at the same time.

Post-surgery management

Sigmoid vaginoplasty abdominal laparotomy surgery requires a sigmoid colon excision and anastomosis procedure. This procedure carries with it the consequences of postoperative care that are specific to bowel management. The digestive function of the intestine must be temporarily rested, until healing is achieved in the area of the intestine that is connected.

In patients with good postoperative condition, fasting can be done from the end of surgery until the next 3-5 days. During the fasting period, fluids and nutrients are given through the parenteral route, with monitoring of general condition, as well as laboratory evaluation of blood protein values, electrolytes and hydration status.

After the fasting phase, start with a liquid diet and gradually increase to the patient's usual diet as tolerated (Meltzer, 2016). Generally,

patients can return to their diet as before surgery, in about 2 weeks to a month after surgery.

Anti-nausea medication can be given as needed. In conditions of constipation, which can occur as a result of administration of narcotic drugs for analgesics, stool softeners can be given (Meltzer, 2016).

Surgical wound care is carried out as needed, so that infection does not occur. Pay attention to factors that affect wound healing such as general condition, hemoglobin levels, albumin or protein levels, nutritional and vitamin adequacy, and psychological factors.

Postoperative physical activity begins immediately postoperatively with gradual mobilization. On the first to second postoperative day, mobilization can be performed lying on the right and left sides alternately. Furthermore, passive sitting mobilization to active sitting, standing, and walking. Daily activities can be carried out gradually according to the conditions of each individual, there are no special restrictions. However, strenuous physical activity including vigorous exercise should be avoided for 6 weeks, bathing for 8 weeks, and swimming or bike riding for 3 months. Complete healing of the surgical process is generally achieved in the third postoperative month, so that more vigorous physical activity and sexual activity can be carried out in 3 months postoperatively. Avoid tobacco use or smoking, both active and passive, for at least a month after surgery, as these will generally interfere with the tissue healing process (Meltzer, 2016).

Neovaginal evaluation was performed postoperatively. On the first day to the first week can be evaluated for the presence or absence of bleeding, signs of infection, and how is the overall condition of the neovagina.

The dilatation procedure can be carried out gradually if there is stenosis at the neovaginal opening in the vaginal vestibule, which is feared that it will interfere with the penetration process in sexual activity. Dilation is carried out using a vaginal dilator according to the Hegar dilator, with a size from the smallest diameter that can be entered without pain to a diameter of about 2.5-3 centimeters. This procedure is done in stages and can be done independently by the patient or assisted by a partner. Make sure the dilator is clean before use. Dilators can be cleaned first with warm water and antibacterial soap. Rinse well and dry with a clean towel or cloth. Apply a water-based lubricant. Gently insert the dilator into the neovagina at a 45-degree angle to below the pubic bone, then continue in a straight direction. Insert the dilator to the full depth of the neovagina (until moderate pressure or resistance is felt) and leave for 10 minutes. This dilation procedure can be performed three times daily for the first three months postoperatively, or as needed, with a gradual increase in the diameter of the dilator (Meltzer, 2016). The frequency and duration of dilatation can be reduced according to the condition of each patient and the results achieved.

The dilatation procedure does not need to be performed in pediatric or adolescent patients who underwent sigmoid vaginoplasty surgery with

the main aim of draining menstrual blood, and have not planned sexual activity in the near future.

Education is important to maintain the cleanliness of the external genital area, washing with mild soap, not using irritating ingredients, especially during menstruation or sexual activity. Wash hands before and after contact with the genital area. Shower should be done every day. When washing the genital area, wipe from front to back to avoid bacterial contamination of the anal area. Avoid clothing that is too tight as friction can facilitate the transfer of bacteria to the genital area (Meltzer, 2016).

Patients generally can be discharged from the hospital after one week of surgery, general condition is good, can actively mobilized, surgical wounds heal well, and have a good diet.

Long term evaluation

Postoperative complications ranged from 0.2 -1.4%, namely ileus, wound infection, pelvic hematoma, urinary tract infection, urinary incontinence, abscess, bowel leakage, colorectal fistula, sigmoid graft necrosis, pelvic abscess. Long-term complications around 0.2-13.9% are persistent vaginal discharge, neovaginal stenosis, neovaginal prolapse, unpleasant odor in vaginal discharge, and postcoital bleeding (Djordjevic *et.al*., 2011; Imparato *et.al*., 2007; Pan, 2017). Excessive neovaginal discharge can be removed by neovaginal irrigation.

Postoperative evaluation of sigmoid vaginoplasty is performed throughout the patient's life. The evaluation includes anatomical form,

function to drain menstrual blood in cases that have a functional uterus, and penetration function in sexual activity.

Anatomically, it is important to maintain the appearance of the vulva perineum within normal limits, there is no excessive stenosis, cicatricial tissue appears, neovaginal prolapse, or other abnormalities that make the patient uncomfortable and reduce self-confidence. If neovaginal prolapse occurs, it can be managed by surgical excision of the excess tissue (Pan, 2017).

Neovaginal stenosis was the main long-term complication reported in the first postoperative year (8.8%). Mild stenosis can be treated with regular vaginal dilatation. The risk of anastomotic stricture can be reduced by selecting a segment of bowel that has an adequate blood supply, a graft that can be mobilized and pulled easily into the perineum without tension (Pan, 2017).

The function of neovagina as an organ to drain menstrual blood can be evaluated from the patient's menstrual cycle routine, the duration of menstruation, and the absence of menstrual blood flow disturbances in the patient.

Evaluation of neovaginal function in sexual activity can be followed up from the absence of interference with penetration during sexual activity. In cases where there is mild stenosis, sexual activity can be initiated by dilating the neovagina to the extent necessary to widen the neovaginal opening in the perineum, followed by natural penetration.

Sexual function is one of the basic human needs. Women who have undergone surgery to treat vaginal disorders including this sigmoid vaginoplasty surgery may experience some postoperative problems, resulting in disturbance or even the inability to perform normal sexual activities. This can be one of the factors that affect the quality of life. Being diagnosed with a sex development disorder has a profound psychological impact on a woman's body image and self-esteem, and as a result, one-third of patients suffer from depression (Carrard *et.al*., 2012).

Long-term, evaluation of neovaginal function in relation to sexual activity especially for the purpose of sexual penetration can be done using the Female Sexual Function Index (FSFI) questionnaire (Pangastuti *et.al*., 2019).

In conditions of suspicion of sexual dysfunction in a woman, the sexual function index can be assessed by conducting interviews using the FSFI (Female Sexual Function Index) and FSDS-R (Female Sexual Distress Scale -Revised) questionnaires (Pangastuti *et.al.*, 2018). The FSFI assessment means that there is no sexual dysfunction if the sum of all scores is more than 26.56. The Female Sexual Distress Scale-Revised (FSDS-R) was created and validated to assess distress associated with impaired sexual function (DeRogatis *et.al*., 2008). The FSDS-R has a total score ranging from 0 to 52, with higher scores indicating more severe distress. A cut-off score of more than 11 is also effective in differentiating between psychological distress and the absence of sexual dysfunction (Carpenter *et.al*., 2014).

The neovagina may produce clear mucus discharge with a characteristic odor, especially in the first few months after surgery. Furthermore this is not a problem that many patients complain about.

For best results, evaluation starts every week after surgery for one month, once a month for three months, and twice a year for the following years (Pangastuti *et.al*., 2020).

It should be noted that there is a risk of cell change towards malignancy, due to changes in its function from the digestive organs to organs that are passed by menstrual blood or are affected by sexual activity.

In cases where pregnancy occurs, close monitoring should be carried out. There is a risk of abortion, premature delivery, infection, pain, bleeding, even uterine or neovaginal rupture. Delivery was carried out by planned cesarean section at the early term of gestation.

REFERENCES

Basturk, T., Koc, Y., Ucar, Z., Sakaci, T., Ahbap, E., Kara, E., Bayraktar, F., Sevinc, M., Sahutoglu, T., Kayalar, A., Sinangil, A., Akgol, C., and Unsal, A. (2015). Renal Damage Frequency in Patients with Solitary Kidney and Factors That Affect Progression. *International journal of nephrology*, 876907. https://doi.org/10.1155/2015/876907.

Beksac, M.S., Salman, M.C., and Dogan, N.U. (2011). A New Technique for Surgical Treatment of Vaginal Agenesis Using Combined Abdominal-Perineal Approach. *Case Report in Medicine*. Vol. 2011, Article ID 120175, 6 pages, 2011. https://doi.org/10.1155/2011/120175.

Both, S., Kluivers, K., ten Kate-Booij, M., and Weijenborg, P. (2018). Sexual response in women with Mayer-Rokitansky-Küster-Hauser syndrome with a nonsurgical neovagina. *Am J Obstet Gynecol*, 219:283.e1-8.

Carpenter, Janet, S., Reed, S.D., Guthrie, K.A., Larson, J.C., Newton, K.M., Lau, R.J., Learman, L.A., and Shifren, J.L. (2014). Using an FSDS-R Item to Screen for Sexually Related Distress: A MsFLASH Analysis. *Sexual Medicine*, 3 (1): 7-13. DOI:10.1002/sm2.53. http://dx.doi.org/10.1002/sm2.53.

Carrard, C., Chevret-Measson, M., Lunel, A., and Raudrant, D. (2012). Sexuality after sigmoid vaginoplasty in patients with Mayer-Rokitansky-Küster-Hauser syndrome. *Fertility and Sterility*, *97*(3), 691–696. https://doi.org/10.1016/j.fertnstert. 2011.12.015.

Chandler, T.M., Machan, L.S., and Cooperberg, P.L. (2009). Müllerian duct anomalies: from diagnosis to intervention. *The British Journal of Radiology*, 82: 1034-42.

Crader M.F. and Varacallo M. (2021). Preoperative Antibiotic Prophylaxis. *NCBI Bookshelf*. A service of the National Library of Medicine, National Institutes of Health. Available from: https://www.ncbi.nlm.nih.gov/books/NBK442032/.

Creatsas, G. and Deligeoroglou, E. (May 2010). Creatsas modification of Williams vaginoplasty for reconstruction of the vaginal aplasia in Mayer-Rokitansky-

Küster-Hauser syndrome cases. *Womens Health* (Lond), 6(3):367-75. DOI: 10.2217/whe.10.13. PMID: 20426603.

Dabaghi, S., Zandi, M., and Ilkhani, M. (2019). Sexual satisfaction in patients with Mayer-Rokitansky-Küster-Hauser syndrome after surgical and non-surgical techniques: a systematic review. *International Urogynecology Journal*, *30*(3), 353–362. https://doi.org/10.1007/s00192-018-3854-5.

DeRogatis, L., Clayton, A., Lewis-D'Agostino, D., Wunderlich, G., and Fu, Y. (2008). Validation of the Female Sexual Distress Scale-Revised for Assessing Distress in Women with Hypoactive Sexual Desire Disorder. *The Journal of Sexual Medicine*, *5*(2), 357–364. https://doi.org/10.1111/j.1743-6109.2007.00672.x.

Djordjevic, M. L., Stanojevic, D. S., and Bizic, M. R. (2011). Rectosigmoid vaginoplasty: clinical experience and outcomes in 86 cases. *The journal of sexual medicine*, *8*(12), 3487–3494. https://doi.org/10.1111/j.1743-6109.2011.02494.x.

Dreisler, E. and Sørensen, S. (2014). Müllerian duct anomalies diagnosed by saline contrast sonohysterography: prevalence in a general population. *Fertil Steril*, 102(2):525–9.

Grimbizis, G. F., Gordts, S., Di Spiezio Sardo, A., Brucker, S., De Angelis, C., Gergolet, M., Li, T. C., Tanos, V., Brölmann, H., Gianaroli, L., and Campo, R. (2013). The ESHRE/ESGE consensus on the classification of female genital tract congenital anomalies. *Human reproduction (Oxford, England)*, *28*(8), 2032–44. https://doi.org/10.1093/humrep/det098.

Grimbizis, G.F. and Campo, R. (2010). Congenital malformations of the female genital tract: the need for a new classification system. *Fertil Steril*, 94:401–7.

Handaya, A.Y., Setyawan, N., Pangastuti, N., Marijata, Barmawi, A., Sofii, I., Rahman, M.N., Setyawati, I.A., and Hafiq, H.M. (June 2020). Double Pedicle Artery Rotation Sigmoid Vaginoplasty for Vaginal Aplasia Management. *Ann Coloproctol*, 36(3):198-203. doi: 10.3393/ac.2018.10.30. Epub 2020 Jan 20. PMID: 31991533; PMCID: PMC7392576.

Hensle T.W. and Dean G.E. (1992). Vaginal replacement in children. *J Urol*., 148:677-9.

Herlin, M.K., Petersen, M.B. and Brännström, M. (2020). Mayer-Rokitansky-Küster-Hauser (MRKH) syndrome: a comprehensive update. *Orphanet J Rare Dis*, 15, 214. https://doi.org/10.1186/s13023-020-01491-9.

Imparato E., Alfei A., Aspesi G., Meus A.L., and Spinillo A. (2007). Long- term results of sigmoid vaginoplasty in a consecutive series of 62 patients. *Int Urogynecol J Pelvic Floor Dysfunct*. Vol. 18: 1465-9.

Kölle, A., Taran, F., Rall, K., Schöller, D., Wallwiener, D., and Brucker, S. (2019). Neovagina creation methods and their potential impact on subsequent uterus transplantation: a review. *BJOG: An International Journal of Obstetrics & Gynaecology*, *126*(11), 1328–1335. https://doi.org/10.1111/1471-0528.15888.

MacGowan A.P., Darley E.S.R., Jacobson S.K., Smith D., and Urch J. (2020). NBT Antibiotic Guidelines 2020. Date of Issue: July 2015, Version 2.0 July 2016, Version 3.0 January 2017, version 4.0 September 2017, version 5.0 July 2018
Ratified by the Drugs and Therapeutics Committee: July 2018
Date of Review: July 2020.

Minami, C., Tsunematsu, R., Hiasa, K., Egashira, K., and Kato, K. (2019). Successful Surgical Treatment for Congenital Vaginal Agenesis Accompanied by Functional Uterus: A Report of Two Cases. *Gynecol Minim Invasive Ther*, 8(2):76-79. DOI:10.4103/GMIT.

Fahmy, M.A.B., Hamid, M.H.A., Al Abeissy, and Abdalla, M.M. (2011). Applicability of Sigmoid Colon Graft for Vaginal Replacement (Colovaginoplasty) at Young Age. *Surgical Science*, 2, 422-426. DOI:10.4236/ss.2011.28092. http://www.SciRP.org/journal/ss.

Meltzer, T. (2016). Vaginoplasty procedures, complications and aftercare. *UCSF Gender Affirming Health Program*. Brownstein & Crane Surgical Services, University of California San Fransisco. Publication Date: June 17, 2016.

Morcel, K. and Camborieux, L. (2007). Mayer-Rokitansky-Küster-Hauser (MRKH) syndrome. *Orphanet journal of rare diseases*, *2*, 13. https://doi.org/10.1186/1750-1172-2-13.

Nowier A., Esmat M., and Hamza R.T. (May-June 2012). Surgical and Functional Outcomes of Sigmoid Vaginoplasty Among Patients with Variants of Disorders of Sex Development. *Int Braz J Urol*. Vol. 38 (3): 380-8. DO-10.1590/S1677-55382012000300011.

Ongom P.A. and Kijjambu S.C. (2013). Antibiotic Prophylaxis in Colorectal Surgery: Evolving Trends. *J Mol Pharm Org Process Res*. Vol 1(3): 109. DOI: 10.4172/2329-9053.1000109.

Pangastuti, N, Iman, B.S., Denny, A., and Emilia, O. (2019). Validation test of Indonesian female sexual function index (Indonesian FSFI). *Bali Medical Journal (Bali Med J)*. Vol. 8, Number 1: 164-168 P-ISSN.2089-1180, E-ISSN.2302-2914. https://doi.org/10.15562/bmj.v8i1.1138.

Pangastuti, N., Rahman, M.N., Handaya, A.Y., Setyawan, N., Sofii, I., Barmawi, A., and Marijata. (2020). How is Vaginal Function in Patients with A History of Sigmoid Vaginoplasty Surgery? *Mal J Med Health Sci*, 16 (SUPP3): 18-23, June 2020.

Pan, P. (2017). Surgical and functional outcome of sigmoid colon-vaginoplasty in Mayer-Rokitansky-Kuster-Hauser syndrome. *Pan P. Int J Reprod Contracept Obstet Gynecol. 2017 Oct;6(10):4441-4446.* www.ijrcog.org. pISSN 2320-1770. eISSN 2320-1789. DOI: http://dx.doi.org/10.18203/2320-1770.ijrcog20174421.

Spencer, T.E., Dunlap, K.A., and Filant, J. (2012). Comparative developmental biology of the uterus: insights into mechanisms and developmental disruption. *Mol Cell Endocrinol*, 354(1–2):34–53.

The American College of Obstetrician and Gynecologist. (2018). ACOG Committee Opinion Number 728 (Replaces Committee Opinion Number 562, May 2013). Müllerian Agenesis: Diagnosis, Management, and Treatment. *Committee on Adolescent Health Care*.

Zhang, W., Li, C., Cheng, W., Li, T., Gao, H., and Zhang, H. (2019). Application of mesocolon rotation and reverse puncture in total laparoscopic sigmoid vaginoplasty. *Experimental and Therapeutic Medicine*, 18: 3191-3196.

CHAPTER 3

CAROTID ARTERY AND THE MOST FREQUENT DISEASES

Assist. Prof. Dr. Ozgur ALTINBAS[1]

[1] Gaziantep University, Vocational School of Health Services, Gaziantep, Turkey
ozgur_altinbas@yahoo.com. ORCID: 0000 0002 6819 2454

1. INTRODUCTION

Carotid arteries are the vascular structures that deliver blood through the neck to the brain. A various types of carotid artery diseases and mains are including carotid artery stenosis, carotid artery injury due to penetrating neck trauma, carotid artery dissection and glomus caroticum. Stenosis of the carotid arteries results in decreased blood flow and known as carotid artery disease (CAD). Mainly, atherosclerotic process causes the narrowing of the carotid arteries and if the plaques formed due to the atherosclerosis break or rupture a cerebrovascular event called stroke may be developed. Carotid artery injury due to penetrating neck trauma is a critical clinic condition that may result in active arterial bleeding and expanding arterial hematoma. Carotid artery dissection is a rarely seen clinical condition which may cause worse outcome if not intervened. Glomus caroticum is an uncommon neoplasm which arise from paraganglion cells in neural crest found on carotid bifurcation. Critical location and hypervascularity of the lesion explain the increased risk of mortality and morbidity due to this tumor although its benign character. Appropriate and rapid diagnosis and treatment approaches to these clinical situations are important to prevent mortality and morbidities.

2. HISTORY

Names of the most of the arteries are related to the organ which they are connected but interestingly the arteries in the neck are called “carotid arteries’’.

The word “carotis’’ originated from a Greek word karos, that means “sleep’’(Fig-1).

grc: Greek eng:English

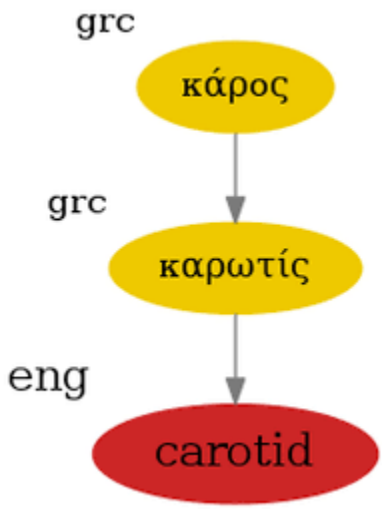

Figure-1: The etymological origin of the word “carotid”

Because not the compression of the arteries in the neck, but of their bifurcation which includes baroreceptors, induce sleep or fainting. Aristotle declared in his work named “Parva Naturalist’’ that, pressure on the veins of the neck results to unconsciousness. Similarly, scientists like Andreas Vesalius, Carolus Stephanus used different terms instead of carotid that means sleep or stupor (Heymans, 1967).

3. ANATOMY

Although rarely seen anatomical variations, aortic arch has three branches: the brachiosephalic artery, left subclavian artery and the left common carotid artery. Brachiosephalic artery also divides into two

branches: right subclavian artery and right common carotid artery (Fig-2).

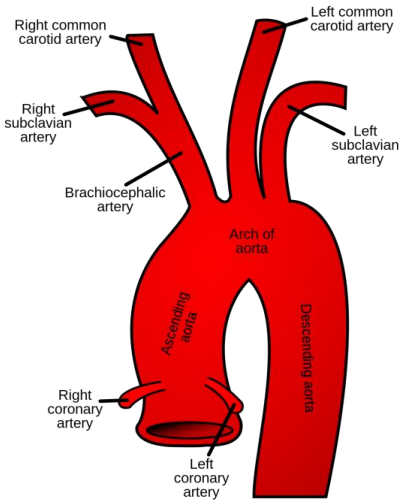

Figure-2: Branches of the aortic arch

Gray's Anatomy, Plate 506

Usually at the level of the fourth or the fifth cervical vertebra, the common carotid arteries (CCA) divide into external carotid artery (ECA) and internal carotid artery (ICA). Region of the bifurcatio includes the *carotid body*, a chemoreceptor, and the *carotid sinus*, a baroreceptor.

The external carotid artery maintains blood to the face and neck and has eight branches: the superior thyroid, ascending pharyngeal, lingual, facial, occipital, posterior auricular, maxillary and superficial temporal arteries.

The internal carotid artery maintains blood to the brain and has six main branches: anterior cerebral artery, middle cerebral artery,

ophthalmic artery, anterior choroidal artery, posterior communicating artery, superior hypophyseal artery (Sethi et al, 2020).

Carotid arteries are adjacent to a number of cranial nerves (CN) and their branches include: glossopharyngeal nerve (CN-9), vagus nerve (CN-10), accessory nerve (CN-11) and hypoglossal nerve (CN-12) (Fig-3) (Majeed et al, 2016). This neighborhood is important in carotid endarterectomy. The cranial nerve which mostly affected in carotid artery surgery is hypoglossal nerve and frequencies vary between 5% to 20% in the literature. Paresis of the ipsilateral muscle of the tongue may occur while bilateral injury may cause life threatening airway obstruction (Forssell et al, 1995).

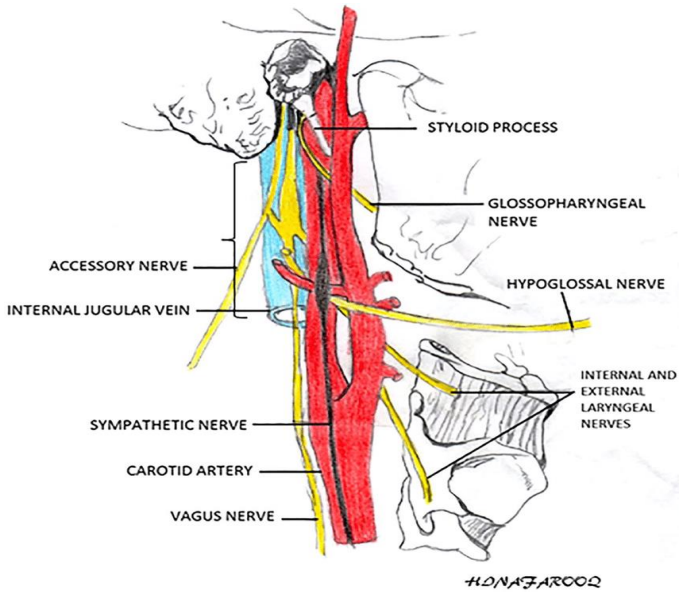

Figure-3: ICA and its relation to cranial nerves IXth, Xth, XIIth and sympathetic chain; (bracket) the IXth cranial nerve passes lateral to the ICA while the Xth nerve lies posteriorly and medially; hypoglossal nerve crosses the ICA more caudally at the C3 level.
Oxford Medical Case Reports 2016 Oct; 2016(10): omw 078

4. EMBRYOLOGY and HISTOLOGY

Development of ICA during the 3 mm embryonic stage (24 days) rise from the combination of the 3rd branchial arch arteries and the distal segments of the paired dorsal aorta. The ventral portion of the 2nd branchial arch disconnects from the dorsal aorta near the origin of the ICA and becomes the ventral pharyngeal artery. The ventral pharyngeal artery and the ICA fuse proximally to form the CCA and the distal segment of the ventral pharyngeal artery becomes the ECA (Fig-4) (Abdulla et al, 2004, Menshawi et al,2015).

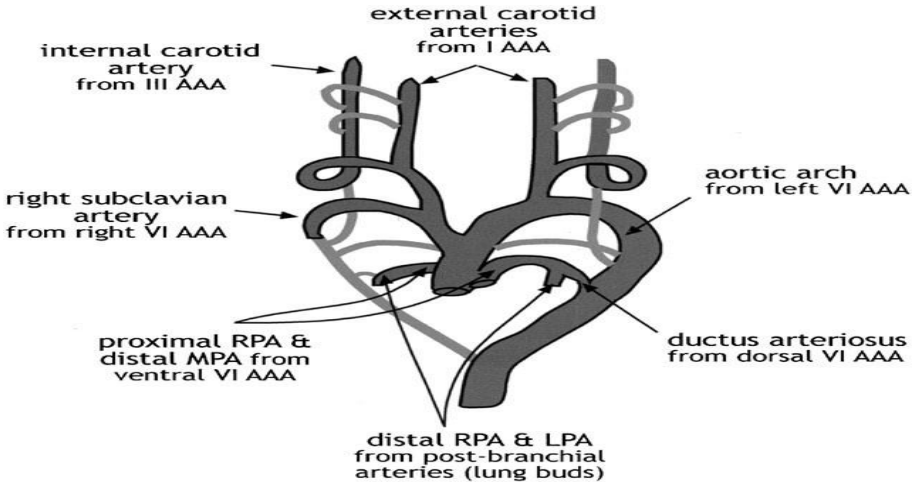

Figure-4: Aortic arch arteries (*AAA*) and the final great vessels anatomy

MPA: Main pulmonary artery LPA: Left pulmonary artery RPA: Right pulmonary artery

Pediatric Cardiology 2004; 25: 191-200

The common carotid arteries are large sized muscular arteries consist of three main layers: the inner layer is called *tunica intima*, made up of epithelium and connective tissue, the layer upon the intima is called *tunica media,* made up of smooth muscles, the outer layer is called *tunica adventitia,* made up of collagen and elastic tissue (Fig-5).

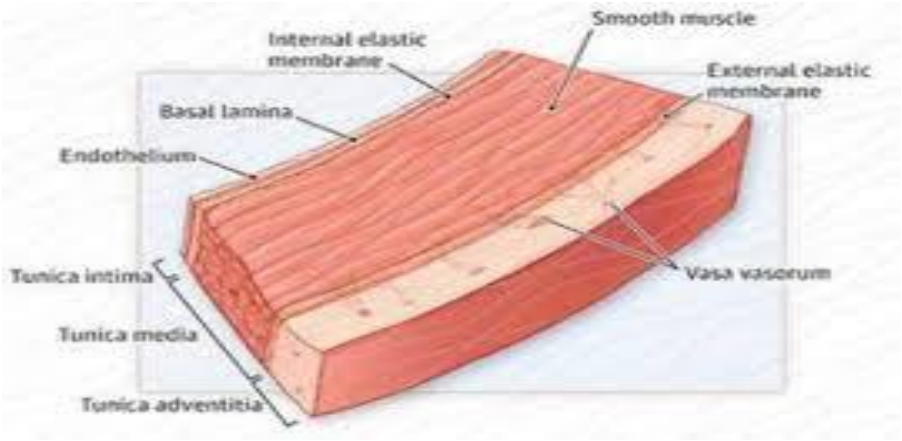

Figure-5: Histological layers of arterial structure

JAMA 2016; 316(2): 754-763

Single layer of simple squamous endothelial cells form tunica intima which is supported by basal lamina. This layer interacts with the contents of the lumen. Smooth muscles in the structure of the tunica media provide rigidity and facilitate pulse contraction to propel blood flow forward. The external layer defined as tunica adventitia is responsible from the flexibility, elasticity and integrity of the vessel. It includes the structure called vasa vasorum that allows nutrients, oxygen and waste to move from the lumen to the cells of the vessel wall (Taylor and Bordoni, 2020, Nguyen and Duong, 2020).

5. PHYSIOLOGY

The systemic cardiorespiratory responses to hypoxia are started by specific sensory structures called peripheral receptors and are sensitive to the increases or decreases in arterial blood O_2 levels. Carotid body is a kind of chemoreceptor and plays a role in systemic vascular, cardiac and respiratory responses to hypoxia. There is one pair of carotid bodies and localized in the bifurcation of common carotid arteries. A branch of the glossopharengeal nerve called the 'carotid sinus nerve' innervates the carotid bodies. Its sensory discharge frequency increases and gives a sudden respond within seconds to hypoxia (Prabhakar, 2013). In addition to decreased PO_2, the carotid body chemoreceptor is sensitive to increased PCO_2 and decreased blood pH. It alerts the brain to set the respiratory rate. The carotid sinus baroreceptors are the peripheral receptors that sensitive to the stretch of the blood vessels. They detect the changes in arterial wall and maintain the blood pressure (Pirahanchi and Bordoni, 2021).

6. THE MOST COMMON CAROTID ARTERY DISEASES

6.1. CAROTID ARTERY STENOSIS

Narrowing of the carotid arteries are defined as carotid artery stenosis (CAS). Cranial ischemic infarction and stroke may occur and enable to mortality and morbidity. Atherosclerosis plays a role in 90% of the cases (Varim et al, 2016). The estimated overall prevalence of the atherosclerotic CAS was 1.1%. It was 1.9% in males and 0.5% in females. Diabetes mellitus, hypertension, increased age,

hyperlipidemia, male gender and smoking are the main risk factors in the development of CAS (Woo et al, 2017).

CAS may either symptomatic or asymptomatic. A wide range of symptoms, atypical to life-threatening, were reported such as limb shaking, headache, retinal claudication, syncope, generalized fatigue, transient ischemic attack and stroke. One-third of all the strokes are associated with carotid occlusive disease (Qaja et al, 2021).

Third leading cause of mortality all over the world is the stroke (Feigin et al, 2003). Strokes are generally ischemic due to stenosis, embolism or clot (National Clinical Guidelines For Stroke, 2004). Advanced atherosclerotic process causes the atherosclerotic plaques rupture resulting in the formation of thrombus and arterial occlusion or dislodged materials from the plaques occluding the small-sized branches of the carotid artery (Badimon and Vilahur, 2014). Patients with 60% or more stenosis have 16% risk of stroke development in 5 year period (Saxena et al, 2019).

Duplex ultrasound (DUS), magnetic resonance angiography (MRA), computed tomography angiography (CTA) and digital subtraction angiography (DSA) are the main diagnostic tests used in the determination of the CAS. DUS is the first step test while DSA is accepted as the gold standard for the diagnosis of the CAS (Nedernkoorn et al, 2002). Advantages and disadvantages of the diagnostic tests were given in table 1.

Table-1:Imaging Modalities for Diagnosis of Carotid Artery Stenosis

	Advantages	Disadvantages
Duplex ultrasound	Relatively inexpensive Non-invasive No radiation or contrast	Tight stenosis may be interpreted as total occlusion May overestimate degree of stenosis Operator-dependent
Computed tomographic angiography	Non-invasive Complete imaging of carotid arteries	Radiation Need for iodinated contrast Tight stenosis may be interpreted as total occlusion Artifact from dental work, metal implants, calcification
Magnetic resonance angiography	Non-invasive Complete imaging of carotid arteries No radiation	Need for contrast May overestimate degree of stenosis Usually contraindicated in patients with pacemakers, other metal implants
Conventional angiography	Gold standard imaging	Invasive test Small risk of stroke

Natalie S, Evans MD. Carotid Artery Stenosis. Cleveland Clinic,2016.

Classification of the CAS was designed by the Society of Radiologists in Ultrasoud Consensus Criteria and shown in Table 2.

Table-2: Society of Radiologists in Ultrasound Consensus Criteria for Carotid Stenosis

	Primary parameters		Secondary parameters	
Degree of stenosis, %	**ICA PSV, cm/sec**	**Plaque estimate, %***	**ICA/CCA PSV ratio**	**ICA EDV, cm/sec**
Normal	<125	None	<2.0	<40
<50	<125	<50	<2.0	<40
50-69	125-230	≥50	2.0-4.0	40-100
≥70 but less than near occlusion	>230	≥50	>4.0	>100
Near occlusion	High, low, or undetectable	Visible	Variable	Variable
Total occlusion	Undetectable	Visible, no detectable lumen	Not applicable	Not applicable

* Plaque estimate (diameter reduction) with gray-scale and color Doppler ultrasound.

CCA = common carotid artery; EDV = end diastolic velocity; ICA = internal carotid artery; PSV = peak systolic velocity.

From Grant E G, Benson C B, Moneta G L, et al. Carotid artery stenosis: Gray-scale and Doppler US diagnosis—Society of Radiologists in Ultrasound Consensus Conference. *Radiology* 2003;229:340-346. Copyright ©2003 by Radiological Society of North America (RSNA). Reprinted by permission of RSNA.

Treatment choices of CAS include medical treatment, carotid endarterectomy and carotid artery stenting. Medical management of patients with CAS is an important part of overall process. Treatment of hypertension, diabetes mellitus, lipid abnormalities, smoking cessation, antithrombotic and/or anticoagulant drugs are the main subjects of medical treatment (Ricotta et al, 2011).

Carotid endarterectomy (CAE) is useful in an asymptomatic patients between 40-75 years old, carotid stenosis is >60% and operation mortality is <3%. However, if the center has high number of patients, mortality or stroke rates of the patients are <3% and revascularization is necessary, carotid artery stenting can be alternative to CAE in asymptomatic patients (Tendera et al, 2011).

If the patient is symptomatic and CAS is between 70%-99%, CAE is recommended rather than single medical therapy. However, if the CAS is between 50%-69%, CAE is more favorable than single medical treatment. CAE is not recommended in complete occlusion. Various clinical trials were designed to compare CAE and carotid artery stenting in symptomatic patients. According to the results CAE is recommended if the patient is symptomatic and CAS is between 70%-99%. In addition if there is a high risk of surgery in a symptomatic patient or in the presence of high patient population of the health care center, mortality or stroke rate is <6% and necessity of revascularization, carotid artery stenting can be thought for alternative to the CAE (Tendera et al, 2011).

Recommendation for management of asymptomatic and symptomatic carotid artery disease were summarized in table 3 and table 4.

Table 3: Recommendations for management of asymptomatic carotid artery disease

Recommendations	Class[a]	Level[b]
In 'average surgical risk' patients with an asymptomatic 60–99% stenosis, CEA should be considered in the presence of clinical and/or more imaging characteristics[c] that may be associated with an increased risk of late ipsilateral stroke, provided documented perioperative stroke/death rates are <3% and the patient's life expectancy is > 5 years.[116]	IIa	B
In asymptomatic patients who have been deemed 'high risk for CEA'[d] and who have an asymptomatic 60–99% stenosis in the presence of clinical and/or imaging characteristics[c] that may be associated with an increased risk of late ipsilateral stroke, CAS should be considered, provided documented perioperative stroke/death rates are <3% and the patient's life expectancy is > 5 years.[135,136]	IIa	B
In 'average surgical risk' patients with an asymptomatic 60–99% stenosis in the presence of clinical and/or imaging characteristics[d] that may be associated with an increased risk of late ipsilateral stroke, CAS may be an alternative to CEA provided documented perioperative stroke/death rates are <3% and the patient's life expectancy is > 5 years.[110,129,132,137]	IIb	B

Table 4: Recommendations on revascularization in patients with symptomatic carotid disease

Recommendations	Class[a]	Level[b]
CEA is recommended in symptomatic patients with 70–99% carotid stenoses, provided the documented procedural death/stroke rate is < 6%.[138,147]	I	A
CEA should be considered in symptomatic patients with 50–69% carotid stenoses, provided the documented procedural death/stroke rate is < 6%.[138,147]	IIa	A
In recently symptomatic patients with a 50–99% stenosis who present with adverse anatomical features or medical comorbidities that are considered to make them 'high risk for CEA', CAS should be considered, provided the documented procedural death/stroke rate is < 6%.[135,145,152]	IIa	B
When revascularization is indicated in 'average surgical risk' patients with symptomatic carotid disease, CAS may be considered as an alternative to surgery, provided the documented procedural death/stroke rate is < 6%.[152,153]	IIb	B
When decided, it is recommended to perform revascularization of symptomatic 50–99% carotid stenoses as soon as possible, preferably within 14 days of symptom onset.[138,154,155]	I	A
Revascularization is not recommended in patients with a < 50% carotid stenosis.[138]	III	A

6.2. CAROTID ARTERY TRAUMA

Trauma of the carotid artery is rarely seen and occurs in less than 2 per 1000 patients with trauma who require hospital admission and has mortality and morbidity risks due to hemorrhage, airway compression and cerebral damage. Traumas may blunt injuries like motor vehicle crushes, falls or crush injury or penetrating injuries like gunshot wounds or blasts. Patients can be presented with no neurologic deficits, neurologic deficits like transient ischemic attack and stroke or

in coma. Mortality rate may up to 40%. Most of the patients with carotid artery trauma can accompanied with other injuries include thoracic, head, face, abdominal and extremities (Ramadan et al, 1995). Underlying mechanisms of carotid artery injuries related to blunt trauma are the hyperextension and contra-lateral rotation of the neck or direct pressure to the neck e.g. by a seatbelt (Bajko et al, 2018).

DSA is the gold standard method for the diagnosis of the trauma of the carotid artery, in addition patients often CT scan of other body parts for investigating of other injuries such as the chest, abdomen and spinal cord (Foreman and Harrigan, 2017, Biffl et al, 2012).

Treatment modalities differ according to the type of the trauma and location of the lesion. Endovascular techniques are becoming more widely performed in the treatment of blunt extracranial carotid injuries and penetrating or blunt intracranial carotid lesions, while open surgery such as surgical ligation or surgical repair is still necessary for the penetrating extracranial carotid injuries or after unsuccessful endovascular interventions (Lee et al, 2014).

6.3. CAROTID ARTERY DISSECTION

Dissection of the carotid artery is a clinical situation in which the layers of the carotid artery separated (Figure 6).

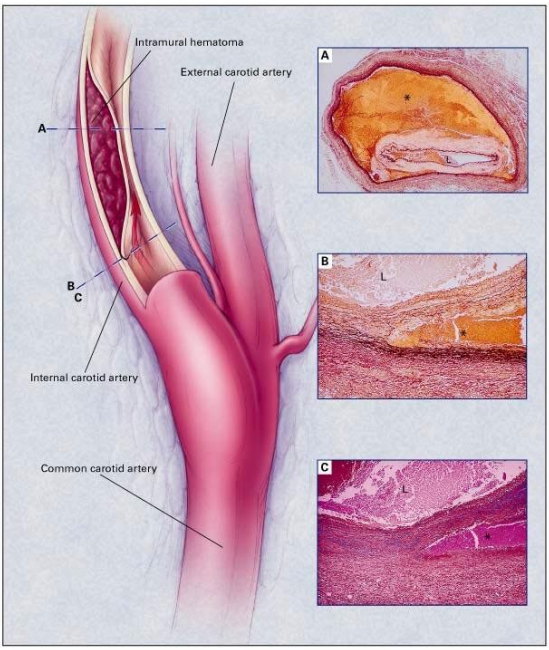

Figure 6: Dissection of intimal layer of the carotid artery and intramural hematoma

N Engl J Med 2009;344:898-906

Thus, blood flow to particular areas of the brain decreases and can result into stroke. It may happen intracranially or extracranially which may result in brain ischemia or subarachnoid hemorrhage (Goodfriend et al, 2021). Mechanism of the dissection is the tear in the intimal layer of the carotid artery which creates an intramural hematoma. Tear can be result from trauma or spontaneously (Hart and Easton, 1983). Dissection related with trauma may result from blunt or penetrating trauma. Motor vehicle collision is an example to the blunt trauma and rapid deceleration with simultaneous neck hyperextension may lead to the dissection. The most common cause of spontaneous carotid artery dissection is “idiopathic” and usually in association with family

history (Goodfriend et al, 2021). It was reported in whole age populations but most common between the ages of 35 to 50. Furthermore it is responsible from the 20% of the strokes under the age of 45 years. The main symptoms attributable to local effects of the carotid artery dissection are pain and partial Horner's syndrome. Clinical manifestations attributable to ischemia are ipsilateral cerebral or retinal ischemia including amaurosis fugax, hemiplegia, dysphasia, etc. (Thanvi et al, 2005).

Doppler ultrasonography, MRA, CTA or DSA are the diagnostic modalities of carotid artery dissection. Although there are additional risks like stroke, vascular perforation, retroperitoneal hemorrhage, and contrast induced nephropathy, DSA is accepted as the gold standard method for diagnosis of carotid artery dissections (Gokce and Erdemoglu, 2012).

Treatment strategies for carotid artery dissection differ in the presence of symptoms. If the patient is asymptomatic any intervention is not required. Progressive stenosis in asymptomatic patients with carotid artery dissection requires the continuation of warfarin treatment and 3 month follow up for other treatment options. Anticoagulant therapy is recommended in the acute period of the disease to prevent thrombus formation. In the presence of resistant ischemia despite anticoagulant therapy or any contraindication for anticoagulant agent, surgery or endovascular treatments are indicated (Akay and Aslim, 2012). Subarachnoid hemorrhage or symptomatic aneurismal dilatation of the carotid artery is required urgent surgery. To prevent further ischemic

or thromboembolic complications, surgical reconstruction may be useful in chronic carotid dissections (Thanvi et al, 2005). In the presence of the progressive dissection, widening pseudoaneurysm or lesions that can not be reached by surgery, endovascular treatment options such as balloon angioplasty, stent or coil embolization can be taken into account (Gokce and Erdemoglu, 2012).

6.4. GLOMUS CAROTICUM

Glomus tumors are known as paragangliomas and origin of them is the neural crest. Their names are given according to origin of the location. Tumors originated from carotid bodies at the carotid bifurcation are called carotid body tumors and “glomus caroticum” is used as an alternative term for carotid body tumors (Sanli et al, 2012, Talay et al, 2010).

Glomus caroticum is usually sporadic, however there is a family history in 10% of the patients. Familial glomus caroticum has an autosomal dominant inheritance. It is usually benign natured however malignancy incidence is <20% (Arda et al, 2020).

Patients may be presented with slow-growing, usually painless mass in the anterolateral region of the neck, tinnitus, syncope and cranial nerve deficits (Schmid et al, 2012).

Open or percutaneous biopsy does not recommended because of the probability of massive bleeding. Doppler ultrasound has also limited usage for the diagnosis of glomus caroticum but it can be performed for differential diagnosis. CT scanning and MRA can also be used for

evaluation of these kinds of tumors. DSA is the gold standard for detection of especially small-sized glomus tumors (Tokgoz et al, 2019).

Treatment modalities depend on the location, size and biologic activity of the tumor and the age and the life expectancy of the patient. Surgical approach, stereotactic radiosurgery and primary radiotherapy are the main treatment methods for the glomus caroticum (Tokgoz et al, 2019). Although some authors recommend routine embolization 24 to 48 hours before surgery to reduce intra-operative bleeding, various neurological complications have been reported due to particulate reflux into the cerebral circulation (Karaman et al, 2019, Kesper et al, 2006). Success of the surgery depends on the resection of the tumor without recurrence. Some authors declared that radiotherapy can not eradicate the tumor totally so radiotherapy may be recommended in patients with high risk of surgical morbidity or who refuse surgery (Papaspyrou et al, 2009).

REFERENCES

Abdulla, R., Blew, G.A., Holterman, M.J. (2004). Cardiovascular Embryology, Pediatric Cardiology, 25, pp. 191-200

Akay, H.T., Aslim, E. (2012). Carotid Artery Dissections, Damar Cer Derg, 21(3), pp. 218-221

Arda, H.N., Sakinci, U., Titiz, A., Civelek, S., Nalca, Y. (2020). Value of preoperative embolization in glomus caroticum, K.B.B ve Bas Boyun Cerrahisi Derg, 4(2), pp.181-183

Badimon, L., Vilahur, G. (2014). Thrombosis formation on atherosclerotic lesions and plaque rupture, J Intern Med, 276(6), pp.618-632

Bajko, Z., Maier, S., Motataianu, A., Balasa, R., Vasius, S., Stoian, A., et al. (2018). Stroke Secondary to Traumatic Carotid Artery Injury-A Case Report, J Crit Care Med, 4(1), pp. 23-28

Biffl, W.L., Burlew, C.C., Moore, E.E., Barnett, C.C., Johnson, J.L., Bensard, D.D. (2012). Blunt cerebrovascular injury: redefining screening criteria in the era of noninvasive diagnose, J Trauma Acute Care Surg, 72(2), pp.330-335

Feigin, V.L., Lawes, C.M., Bennett, D.A., Anderson, C.S. (2003). Stroke epidemiology: a review of population-based studies of incidence, prevalence, and case-fatality in the late 20th century, Lancet Neurol, 2(1), pp. 43–53

Foreman, P.M., Harrigan, M.R. (2017). Blunt Traumatic Extracranial Cerebrovascular Injury and Ischemic Stroke, Cerebrovasc Dis Extra, 7, pp.72–83

Forssell, C., Kitzing, P., Bergqvist, D. (1995). Cranial nerve injuries after carotid artery surgery. A prospective study of 663 operations, Eur J Vasc Endovasc Surg,10, pp. 445-449

Gokce, B., Erdemoglu, A.K. (2012). Carotid Artery Dissection and Cerebral Infarction Secondary to Blunt Trauma, Turk J Neurol, 18(4), pp.162-167

Goodfriend, S.D., Tadi, P., Koury, R. (2021 Jan-). Carotid Artery Dissection, [Updated 2021 Jan 31]. In: StatPearls [Internet]. Treasure Island (FL): StatPearls Publishing

Hart, R.G., Easton, J.D. (1983). Dissections of cervical and cerebral arteries, Neurol Clin, 1(1), pp. 155-182

Heymans C. (1967). Origin and the meaning of the name "carotis'', Med Hist, 11(2), pp.189-190

Karaman, E., Isildak, H., Yilmaz, M., et al. (2009). Management of para-gangliomas in otolaryngology practice: review of a 7-year experience, J Craniofac Surg, 20, pp.1294-1297

Kesper, G.C., Welling, R.E., Wladis, A.R., et al. (2006). A multidisciplinary approach to carotid paragangliomas, Vasc Endovascular Surg, 40, pp. 467-474

Lee, T.S., Ducic, Y., Gordin, E., Stroman, D. (2014). Management of Carotid Artery Trauma, Craniomaxillofac Trauma Reconstr, 7(3), pp. 175-189

Majeed, A., Riberio, N.L., Ali, A., Hijazi, M., Farook, H. (2016). A rare presentation of spontaneous internal carotid artery dissection with Horner's syndrome, VIIIth, Xth and XIIth nerve palsies, Oxford Medical Case Reports, 2016(10), pp. omw 078

Menshawi, K., Mohr, J.P., Gutierrez, J. (2015). A functional perspective on the embryology and anatomy of the cerebral blood supply, J Stroke, 17(2), pp. 144-158

Nederkoorn, P.J., Mali, W.P., Eikelboom, B.C., Elgersma, O.E., Buskens, E., Hunink, M., et al. (2002). Preoperative Diagnosis of Carotid Artery Stenosis, Stroke, 33(8), pp. 2003-2008

Nguyen, J., Duong, H. (2020 Jan-).Anatomy, Head and Neck, Anterior, Common Carotid Arteries. [Updated 2019 Aug 21], In: StatPearls [Internet], Treasure Island (FL): StatPearls Publishing

Papaspyrou, K., Mann, W.J., Amedee, R.G. (2009). Management of head and neck paragangliomas: review of 120 patients, Head Neck 31, pp. 381-387

Pirahanchi, Y., Bordoni, B. (2021). Anatomy, Head and Neck, Carotid Baroreceptors. 2021 Feb 7. In: StatPearls [Internet]. Treasure Island (FL): StatPearls Publishing; PMID: 30725908

Prabhakar, N.R. (2013). Sensing hypoxia: physiology, genetics and epigenetics, J Physiol, 591(9), pp. 2245-2257

Qaja, E., Tadi, P., Kariyanna, P.T. (2021). Carotid Artery Stenosis. StatPearls Publishing

Ramadan, F., Rutledge, R., Oller, D., Howell, P., Baker, C., Keagy, B. (1995). Carotid artery trauma: A review of contemporary trauma center experiences, J Vasc Surg, 21(1), pp. 46-56

Ricotta, J.J., AbuRahma, A., Ascher, E., Eskandari, M., Faries, P., Lal, B.K. (2011). Updated Society for Vascular Surgery guidelines for management of extracranial carotid disease, J Vasc Surg, 54, pp. e1-e31

Sanli, A., Oz, K., Ayduran, E., Aydin, S., Altin, G., Eken, M. (2012). Carotid Body Tumors and Our Surgical Approaches, Ind J Otolaryn Head & Neck Surg, 64, pp. 158-161

Saxena, A., Ng, E.Y, Lim, S.T. (2019). Imaging modalities to diagnose carotid artery stenosis: progress and prospect, BioMed Eng OnLine, 18, pp. 66-88

Schmid, M., Raithel, D., Hahn, E.G., Daniel, W.G., Martin, R. (2012). Glomus caroticum tumor as rare cause of recurrent syncope, Clin Res Cardiol, 101, pp.499-501

Sethi, D., Gofur, E.M., Munakomi, S. (2020 Jan-). Anatomy, Head and Neck, Carotid Arteries, [Updated 2020 May 4]. In: StatPearls [Internet]. Treasure Island (FL): StatPearls Publishing

Talay, S., Abanoz, M., Kaygin, M.A., Dag, O., Halici, U., Ay, D. (2010). Glomus caroticum tumors: A case report of an operated giant carotid body tumor with a review of our experience in 47 patients, Cent Eur J Med 5, pp. 411-416

Taylor, A.M., Bordoni, B. (2020 Jan-). Histology, Blood Vascular System, [Updated 2020 Jul 3]. In: StatPearls [Internet]. Treasure Island (FL): StatPearls Publishing

Tendera, M., Aboyans, V., Bartelink, M.L., Baumgartner, I., Clement, D., Collet, J.P., et al. (2011). ESC peripheral arterial diseases diagnose and treatment guideline

Thanvi, B., Munshi, S.K., Dawson, S.L., Robinson, T.G. (2005). Carotid and vertebral artery dissection syndromes, Postgrad Med J, 8, pp. 383-388

The Intercollegiate Working Party for Stroke . London: Royal College of Physicians; (2004). National Clinical Guidelines for Stroke. 2nd ed.

Tokgoz, S.A., Saylam, G., Bayir, O., Keseroglu, K., Toptas, G., Tatar, EC., et al. (2019). Glomus tumors of the head and neck: thirteen years' institutional experience and management, Acta Oto-Laryngologica, 139(10), pp. 930-933

Varım, C., Varım, P., Acar, B.A., Vatan, M.B., Uyanik, M.S., Kaya, T., et al. (2016). Usefulness of the platelet-to-lymphocyte ratio in predicting the severity of carotid artery stenosis in patients undergoing carotid angiography, Kaohsiung J of Med Sci, 32(2), pp. 86-90

Woo, S.Y., Joh, J.H., Han, S.A., Park, H.C. (2017). Prevalence and risk factors for atherosclerotic carotid stenosis and plaque, Medicine (Baltimore), 96(4), pp. e5999

CHAPTER 4

RADIATION IN PREGNANCY AND LACTATION

Şadan TUTUŞ, MD[1]

[1] Şadan Tutuş, MD Kayseri City Hospital, Radiology Clinic, Kayseri, Turkey sadantutus35@yahoo.com.tr. Orcid ID: 0000-0001-5936-5643

INTRODUCTION

Diagnosis and follow-up in pregnancy is usually done by ultrasonography. However, in some special cases such as acute abdomen, primary cancer diagnosis, pulmonary embolism and traumatic injuries, imaging modalities including X-ray and radioactive material may be required for diagnosis. Since there is often confusion in the selection of the correct diagnostic method in pregnant and breastfeeding mothers, sometimes there may be unnecessary avoidance of beneficial diagnostic trials or unnecessary discontinuation of breastfeeding. While exposure to radiation is a concern for the patient, exposure of pregnant women to strong magnetic fields and/or contrast agents is a cause for concern for the doctor. In this case, radiologists inform the clinician and try to ensure that all patients are examined timely and accurately with lowest probable exposure to radiation, contrast agents, and magnetic fields. They try to make the most accurate imaging selection that can protect the pregnant and fetus and make the correct diagnosis with the principle of ALARA (As Low As Reasonable Achievable).

In this article, it is aimed to clear up the confusion in the diagnostic imaging of patients during pregnancy and breast-feeding mother in the light of the literature.

DIAGNOSTIC IMAGING IN PREGNANCY AND LACTATION

One of the most extensive causes of non-obstetric mortality in pregnant women is trauma, and the gold standard in the evaluation of trauma patients is computed tomography (CT) (Mirza, et al. 2010; Patel, et al. 2007; Sadro, et al. 2012). With the first ultrasonographic examination performed in a pregnant woman was exposed to trauma, the evaluation of the intra-abdominal organs can be done easily and information about the pericardial fluid can be obtained. However, CT examination is necessary to evaluate the integrity of the parenchymal organs, especially in abdominal injuries. New generation multislice CT devices should be preferred because of less radiation exposure. In CT examinations that do not include the pelvic region, covering the abdomen of the pregnant woman with a lead apron may relieve the mother, yet it doesn't reduce the scattered radiation on the uterus (American College of Radiology, 2019; Iball, & Brettle, 2011). In multiple traumas, re-examination may be required in some cases. Therefore, it is also significant to calculate the total radiation exposure of the fetus and to inform the family.

In nuclear medicine units; radio-labeled drugs, namely radiopharmaceuticals (RF), are used for diagnosis and treatment. Since the majority of these RFs used cross the placenta and cause radiation exposure to the fetus, it is not recommended to be used in pregnant women (Stabin, 2014). However, pulmonary perfusion scintigraphy with Tc-99m MAA (macro aggregated albumin), which is widely used in nuclear medicine departments with high sensitivity

in the diagnosis of pulmonary embolism, can be used safely in pregnant women with suspected pulmonary embolism by reducing the dose and the number of particles. If pulmonary perfusion study performed with Tc- 99m MAA is normal, diagnosis of the pulmonary embolism is generally excluded. Apart from this, since some radiopharmaceuticals can pass into breast milk, breastfeeding should be interrupted for a while according to the RF used (Mettler, et al., 2019; Mitchell, et al.2019; Russell, et al. 1997; Stabin, 2014). Information about breastfeeding in some nuclear medicine and radiological imaging studies is presented in Table 1 (Mitchell, et al. 2019).

Common cancer types during pregnancy are malignant melanoma, breast, cervix, lymphoma, thyroid and colorectal cancers. The incidence of these cancers varies between 1/1000 and 1/13000 (Bassam, et al. 2016). Cancer can be diagnosed at any stage up to antenatal period, intrapartum period and postpartum one year (Smith, et al. 2003). In this case, imaging modalities used other than ultrasonography are mammography, CT, direct radiography, retrograde pyelography, fluoroscopic examinations and magnetic resonance imaging (MRI). When diagnostic imaging is required during pregnancy, the safest imaging methods are ultrasound and MRI. Absorbed fetal dose should be less than 5 mGy (0.5 rad) for safe use of radiography and CT that do not involve the abdomen (Lowe, 2004). In order to limit fetal radiation exposure while taking radiographs, the mother's abdomen and pelvis should be protected with lead apron, the area of view should be narrowed as much as

possible, exposure time and absolute dose should be reduced (Oxford & Ludmir, 2009). Direct exposure of the fetus to radiation occurs if it is within the imaging area. While the fetus is outside the imaging area, it is exposed to radiation scattered from maternal tissues. Although lead apron reduces the access of radiation to the womb, some scattered radiation still reaches the fetus (Iball & Brettle, 2011). In Table-2, the estimated radiation doses that the fetus can receive in some imaging modalities are given (Tremblay, et al. 2012).

IMPACTS OF RADIATION ON THE FETUS

The impacts of radiation on living organisms are divided into deterministic and stochastic effects.

-Deterministic Effect: It is the effect of high doses (>0.5 Gy) radiation, which has a certain threshold value, causes cell death. The seriousness of the deterministic impact increases with dose. Radiation-induced malformations occur in a developing organ.

-Stochastic Effect: It is independent from dose, it has no threshold value. At any dose of radiation, it creates random DNA damage and causes genetic damage. It might potentially consequence in neoplasia or changes in reproductive genes. Unlike deterministic impacts, the severity of a stochastic effect doesn’t rise since radiation dose increases, the radiation dose only increases the probability of the effect.

Table 1: Information About Breastfeeding In Some Nuclear Medicine And Radiological Imaging Studies Is Presented (Mitchell, et al. 2019).

Imaging agent	**Breastfeeding interruption**
Noncontrast radiographs	(-)
Nonvascular administration of iodinated contrast	(-)
CT with intravenous contrast	(-)
MRI with intravenous contrast	(-)
Nuclear medicine imaging	
PET (positron emission tomography)	(-)
Bone scan	(-)
Thyroid imaging	
I-131	Interruption for infant
I-123	Suggestions vary, up to 3 weeks
Technetium-99m pertechnetate	Depending on dose, up to 24 hours
Renal imaging	
Tc-99m DTPA (diethyl triamine penta acetic acid)	(-)*
Tc-99m MAG3 (mercapto acetyl glycine)	(-)*
Tc-99m DMSA (dimercapto succinic acid)	(-)*
Tc-99m glucoheptonate	(-)*
Cardiac imaging	
Tc-99m Sestamibi	(-)*
Tc-99m Tetrofosmin	(-)*
VQ scan (ventilation-perfusion)	
Tc-99m MAA (macro aggregated albumin)	12 hours
Breast imaging	
Mammography	(-)
Ultrasound	(-)
MRI with intravenous contrast	(-)

*The International Atomic Energy Administration suggests withholding breastfeeding for 4 hours or one feeding.

Carcinogenesis is related to the stochastic effect of radiation. It has the potential to occur at any dose. There is no threshold at which carcinogenesis can't occur (Tirada, et al. 2015). The relative risk for childhood malignancy from diagnostic radiation is higher in the first trimester and is estimated to be about 3.19. This rate was reported as

1.29 in second trimester and 1.30 in third trimester (Chen, et al. 2008; Gilman, et al. 1988). The lifetime attributable risk of developing malignancy is approximately 0.4% per 10 mGy fetal dose (American College of Radiology, 2019). It should be considered that the background radiation rate is very low for childhood cancers (McCollough, et al. 2007).

Table 2: Fetal Radiation Doses Associated With Common Radiologic Examinations (Tremblay, et al. 2012).

Type of Examination	Fetal Dose * (mGy)
Very low dose examinations(<0.1 mGy)	
Cervical spine radiography (two views)	<0.001
Radiography of any extremity	<0.001
Mammography (two views)	0.001–0.01
Chest radiography (two views)	0.0005–0.01
Low- to moderate-dose examinations (0.1–10 mGy)	
Radiography	
- Abdominal radiography	0.1–3.0
- Lumbar spine radiography	1.0–10
- Intravenous pyelography	5–10
- Barium enema with double-contrast	1.0–20
CT	
- Head/ neck CT	1.0-10
-Chest CT/ CT pulmonary angiography	0.01–0.66
- Limited CT pelvimetry	<1
Nuclear medicine	
- Low dose perfusion scintigraphy	0.1-0.5
- Technetium-99m bone scintigraphy	4-5
- Pulmonary digital subtraction angiography	0.5
Higher-dose examinations (10–50 mGy)	
- Abdominal CT	1.3-35
- Pelvic CT	10-50
-18F PET/CT whole-body scintigraphy	10-50

*Fetal exposure alters with gestational age and maternal body mass index.

It is unethical to conduct research on the fetus; therefore, the results of exposure to radiation in fetuses have been derived from observations, not scientific research. Data on the effect of radiation on the fetus were obtained from observations of patients suffering from the Chernobyl nuclear power plant disaster and the Hiroshima bombing in Japan (Drozdovitch, et al. 2020; Otake & Schull, 1984). High-dose radiation results to the fetus based on these data; It can be examined in four groups as loss of pregnancy, congenital malformations, intrauterine growth retardation and carcinogenesis. There is no completely safe diagnostic dose of radiation for the fetus, radiography should be avoided during all gestational periods and should always be minimized during pregnancy. As a matter of fact, the background radiation that a fetus will be exposed to during its development in the womb is estimated to be 2.3 mSv on average. After attenuation in the mother, the radiation dose reaching the fetus is 0.5-1 mSv (Wang, et al. 2012a); (Wang, et al. 2012b). Fetal dose less than 50 mGy is a negligible level for malformation or miscarriage. This dose cannot be reached with a single CT scan anyway. The impact of ionizing radiation on the fetus is related to the current week of pregnancy and the dose exposed (American College of Radiology, 2015). A summary of deterministic radiation effects according to weeks of gestation after intrauterine radiation exposure of the International Commission on Radiological Protection of the American College of Radiology is given in Table-3.

The "all or nothing" law applies to radiation received during the first eight weeks of pregnancy, that is, if the fetus is affected by radiation, the pregnancy may result in miscarriage, or if it is not affected, the pregnancy will continue. Doses above 100 mGy during the third and fourth weeks of pregnancy result in possible spontaneous abortion. Between the fifth and tenth weeks, no effects are seen at doses below 50 mGy, while potential effects in the interaction between 50 and 100 mGy are scientifically unclear. Doses above 100 mGy increase the risk of malformation due to increasing dose. Radiation dose below 50 mGy between the eleventh and seventeenth gestational weeks still has no effect. Doses between 50-100 mGy produce effects that are probably too vague to be clinically detectable. Doses above 100 mGy between these weeks may cause mental retardation, decrease in IQ, microcephaly and intrauterine growth retardation. Since the organogenesis period ends between the eighteenth and the twenty-seventh gestational weeks, no effect is observed at doses below 100 mGy, while doses above 100 mGy may cause diagnostic undetected IQ deficiencies. After the 27th gestational week, no effect can be detected even above 100 mGy (ICRP Publication 84, 2000; ICRP Publication 90, 2003). Using atomic bomb radiation data, exposure for mental retardation was found to be highest between eight and fifteen weeks, with a threshold dose estimated at 60 to 310 mGy. In fact, the lowest dose determined for severe mental retardation has been reported as 610 mGy (Miller, 1999).

Table 3: A Summary Of Ddeterministic Radiation Effects According To Weeks Of Gestation After Intrauterine Radiation Exposure Of The International Commission on Radiological Protection Of The American College Of Radiology (Drozdovitch, et al 2020).

Gestational Age	**<50 mGy**	**50–100 mGy**	**>100 mGy**
0–2 week	(-)	(-)	(-)
3rd and 4th week	(-)	Probably none	Possible spontaneous abortion
5th–10th week	(-)	There are uncertain effects that cannot be detected clinically and scientifically.	Possible Malformations increase in a dose-dependent.
11th–17th week	(-)	There are uncertain effects that cannot be detected clinically and scientifically.	Increased risk of deficits in intelligence quotient or mental retardation that increase in frequency and severity with increasing dose
18th–27th week	(-)	(-)	Intelligence deficits not detectable at diagnostic dose
> 27 week	(-)	(-)	None applicable to diagnostic medicine

The radiation that the fetus may encounter in daily practice is caused by imaging methods containing radiation. In the evaluation of acute conditions, the benefit that the mother will reach with CT scan should be more than the radiation that the fetus will receive. In these cases, the shooting technique also gains importance, and the section spacing and section thickness can also affect the radiation dose received. MRI can replace CT in some shots. The use of contrast material may facilitate the evaluation of vascular structures and solid organs, but iodine can cross the placenta and go into the amniotic fluid. In animal studies, the teratogenic and mutating effect of iodine used as a contrast agent could not be detected (Webb, et al. 2005). In a study conducted

by Atwell TD et al. (Atwell, et al. 2008) in 21 pregnant women who underwent CT scan between 8 and 37 weeks of gestation, no negative impact of iodinated contrast agent on neonatal thyroid function was found. Each case should be evaluated according to the gestational age exposed and radiation levels received. A precise assessment of fetal dose requires a great deal of information about the X-ray system, examinations performed, technique applied, patient size, and gestational week etc. Once all information is available, the radiation risk will be assessed and reviewed along with any other possible pregnancy risks. Thus, the doctor, patient and other interested persons can understand the circumstances and make a reasonable decision about the management of the disease.

PREGNANCY AND MAGNETIC RESONANCE IMAGING

Today, the indication range of MRI scans in pregnant women has expanded considerably. MRI can be requested with a large number of preliminary diagnoses, from causes of acute abdomen to headache or placental invasion anomalies. There are also concerns about MRI. These are radiofrequency pulses used in MRI causing heating in the tissues, B0 power that might affect rapid cell migration in the first trimester, and the possibility of hearing loss due to the loud noise during imaging that damages the fetal ear (Ciet & Litmanovich, 2015). Ray G et al (Ray, et al., 2016) reported the children of pregnant women who underwent MRI in first trimester, from their birth to the age of four; They followed up in terms of stillbirth, newborn death, congenital anomaly, neoplasm development, hearing and vision loss.

They did not detect any increased risk when comparing exposure and non-exposure to MRI in first trimester. However, they have associated contrast-enhanced MRI with an increased risk of rheumatologic, inflammatory or infiltrative skin condition and stillbirth or neonatal death at any time during pregnancy. However, since there is an uncertainty in the effects of MR contrast agents on the fetus, it is recommended to be used if it is absolutely necessary and the examination cannot be postponed until the termination of pregnancy (Tirada, et al., 2015). In addition, due to rapid cell migration in the first trimester, the International Commission on Non-Ionizing Radiation Protection recommends that MRI not be performed until the end of the first trimester (Tirada, et al., 2015). Due to the increase in the magnetic field, imaging should not be performed on pregnant patients with MRI devices larger than 3T (Ciet & Litmanovich, 2015).

PREGNANCY AND ULTRASONOGRAPHY

Fetal follow-up is performed by ultrasonography in obstetric practice. In the routine, ultrasonographic examinations are performed at least three times for nuchal thickness measurement in the first trimester, for detailed anomaly screening in the second trimester, and for the follow-up of fetal development in the third trimester, and more in some countries. Diagnostic ultrasonography is a form of energy that has potential to act on tissues. As the sound wave travels through the tissue, it loses amplitude through absorption and scattering. Energy is converted into heat by absorption. The thermal index (TI) is the ratio of the power used to the power that causes a maximum temperature

rise of 1 degree. The mechanical index (MI) points out the potential of ultrasound to induce inertial cavitation. The US Food and Drug Administration has limited the spatio-peak temporal average intensity of ultrasound transducers to 720 mW/cm^2. The theoretical increase in temperature rise at this density can be as high as 2°C (American Institute of Ultrasound in Medicine, 2015; Patel, et al. 2007). The temperature rise is lowest in B-mode imaging. It's higher in color Doppler and spectral Doppler examinations than in B-mode. TI and MI values are displayed on the screen of the ultrasonography device used. When performing obstetric doppler, the TI value cannot be exceeded 1.5, so that it does not have a negative effect on the health of the fetus. In ultrasonographic examinations, fetal health is tried to be protected by considering ALARA principles.

CONCLUSION

Radiation is undesirable for the fetus. However, in cases of necessity, there is no harm in using diagnostic radiological imaging modalities considering the benefit-harm ratio.

REFERENCES

American College of Radiology (2015). ACR–SPR practice parameter for imaging pregnant or potentially pregnant adolescents and women with ionizing radiation. Resolution 39. Reston (VA): ACR; 2014. Available at: http://www. acr.org/~/media/ 9e2ed55531fc4b4fa53ef3b6d3b25df8.pdf. Retrieved October 27.

American College of Radiology (2019). ACR–SPR Practice Parameter for Imaging Pregnant or Potentially Pregnant Adolescents and Women with Ionizing Radiation. Updated 2018. https://www.acr. org/-/media/ACR/Files/Practice-Parameters/pregnant-pts.pdf. Accessed November 30.

American Institute of Ultrasound in Medicine (2015). Statement on mammalian biological effects of heat. Laurel (MD): AIUM; 2015. Available at: http://www.aium.org/official Statements/17. Retrieved October 5.

Atwell, T. D., Lteif, A. N., Brown, D. L., McCann, M., Townsend, J. E., Leroy, A. J. (2008). Neonatal thyroid function after administration of IV iodinated contrast agent to 21 pregnant patients. *AJR Am J Roentgenol; Jul 191*(1):268–71.

Bassam, H. R. , Victoria, G., Michael L., (2016). Fetal Implications of Diagnostic Radiation Exposure During Pregnancy Evidence-based Recommendations *Clin Obstet Gynecol Jun;59*(2):412-8.

Chen, M. M., Coakley, F. V., Kaimal, A., Laros, R. K., (2008). Guidelines for computed tomography and magnetic resonance imaging use during pregnancy and lactation. *Obstet Gynecol 2008;112*(2 part 1):333-340.

Ciet, P. & Litmanovich, D. E. (2015). MR safety issues particular to women. *Magn Reson Imaging Clin N Am;23*(1):59–67.

Drozdovitch, V., Minenko, V., Kukhta, T., Trofimik, S, Grakovitch, R., Hatch, M., Cahoon, E. K., …. Rozhko, A. (2020). Thyroid Dose Estimates for a Cohort of Belarusian Persons Exposed in Utero and During Early Life to Chernobyl Fallout. *Health Phys. Feb;118*(2):170-184

Gilman, E. A., Kneale, G. W., Knox, E. G., Stewart, A. M. (1988). Pregnancy x-rays and childhood cancers: effects of exposure age and radiation dose. *J Radiol Prot;8*(1):3–8.

Iball, G. R. & Brettle, D. S. (2011). Use of lead shielding on pregnant patients undergoing CT scans: results of an international survey. *Radiography;17*(2):102-108.

International Commission on Radiological Protection (2000). Pregnancy and Medical Radiation. ICRP Publication 84;1-43.

International Commission on Radiological Protection (2003). Biological Effects After Prenatal Irradiation (Embryo and Fetus): ICRP Publication 90;1-200.

Lowe, S. A. (2004): Diagnostic radiography in pregnancy: Risks and reality. *Aust N Z J Obstet Gynaecol 44*(3):191-196.

McCollough, C. H., Schueler, B. A., Atwell, T. D., Braun, N. N., Regner, D. M., Brown, D. L., LeRoy, A. J. (2007). Radiation exposure and pregnancy: when should we be concerned? *Radiographics.27*(4):909-917.

McJury, M., & Shellock, F. G. (2000). Auditory noise associated with MR procedures: a review. *J Magn Reson Imaging 12* (1):37–45.

Mettler, F., Guiberteau, M., Appendix, G. (2019). Pregnancy and breast feeding. In Essentials of Nuclear Medicine and Molecular Imaging. 7th ed. *Philadelphia, PA: Elsevier;*513-515.

Miller, R. W. (1999). Discussion: severe mental retardation and cancer among atomic bomb survivors exposed in utero. *Teratology;59*(4):234-235.

Mirza, F., Devine, P., Gaddipati, S. (2010). Trauma in pregnancy: a systematic approach. *Am J Perinatol. 27*(07):579-586.

Mitchell, K. B., Fleming, M. M., Anderson, P. O., Giesbrandt, J. G. (2019); Academy of Breastfeeding Medicine. ABM Clinical Protocol #30: Radiology and Nuclear Medicine Studies in Lactating Women. *Breastfeed Med. Jun;14*(5):290-294.

Otake, M. & Schull, W. J. (1984). In utero exposure to A-bomb radiation and mental retardation: a reassessment. *Br J Radiol*. 57:409.

Oxford, C. M., & Ludmir, J. (2009): Trauma in pregnancy. *Clin Obstet Gynecol 52* (4):611-629.

Patel, S. J., Reede, D. L., Katz, D.S., Subramaniam, R., Amorosa, J.K. (2007). Imaging the pregnant patient for onobstetric conditions: algorithms and radiation dose considerations. *Radiographics. 27*(6):1705-1722.

Ray, J. G., Vermeulen, M. J., Bharatha, A., Montanera, W. J., Park, A. L. (2016). Association between MRI exposure during pregnancy and fetal and childhood outcomes. *JAMA. 316*(9):952-961.

Russell, J. R., Stabin, M. G., Sparks, R. B., Watson, E. E. (1997). Radiation absorbed dose to the embryo/fetus from radiopharmaceuticals. *Health Phys. 73*(5):756-769.

Sadro, C., Bernstein, M. P., Kanal, K. M. (2012). Imaging of trauma: part 2, abdominal trauma and pregnancy—a radiologist's guide to doing what is best for the mother and baby. *Am J Roentgenol. 199*(6):1207-1219.

Smith, L. H., Danielsen, B., Allen M. E., Cress, R. (2003). Cancer Associated with obstetric delivery: results of link age with the California cancer registry. *Am J Obstet Gynecol.Oct 189*(4):1128–1135.

Stabin, M. G. (2014). Radiation dose concerns for the pregnant or lactating patient. *Semin Nucl Med. 44*(6):479-488.

Tremblay, E., Thomassin, N. I., Trop, I. (2012) Quality iniitiatives: guidelines for use of medical imaging during pragnancy and lactation. *Radiographics;32*(3):897-911

Tirada, N., Dreizin, D., Khati, N. J., Akin, E. A., Zeman, R. K. (2015) Imaging pregnant and lactating patients. *Radiographics.;35(*6): 1751-1765.

Wang, P. I., Chong, S. T., Kielar, A. Z., Kelly, A. M., Knoepp, U. D., Mazza, M.B., Goodsitt, M. M. (2012). Imaging of pregnant and lactating patients. I. Evidence based review and recommendations. *AJR Am J Roentgenol 198*(4): 778–784.

Wang, P. I., Chong, S. T., Kielar, A. Z., Kelly, A. M., Knoepp, U. D., Mazza, M.B., Goodsitt, M. M. (2012). Imaging of pregnant and lactating patients. II.

Evidence-based review and recommendations. *AJR Am J Roentgenol 198*(4): 785–792.

Webb, J. A., Thomsen, H. S., Morcos, S. K. (2005). The use of iodinated and gadolinium contrast media during pregnancy and lactation. Members of Contrast Media Safety Committee of European Society of Urogenital Radiology (ESUR). *Eur Radiol 15*:1234–40.

CHAPTER 5

A NEVER ENDING STUDY:
GENERAL vs LOCAL ANESTHESIA

Assist. Prof. Dr. Tolga KOYUNCU[1]

[1] Recep Tayyip Erdogan University Medical Faculty, Department of Anesthesiology and Reanimation, Rize, Turkey
e-mail: tolga.koyuncu@erdogan.edu.tr .ORCID: 0000-0002-0019-9684

INTRODUCTION

The choice of anesthetic method is based on indications, contraindications, discretion of the surgeon, general status and preference of the patient. Therefore, the patient should undergo a detailed assessment before making-decision for the anesthetic method. There is an ongoing debate in the literature about general anesthesia (GA) vs local anesthesia (LA) in certain surgical procedures. Each anesthesia technique has its unique indications and contraindications, advantages and disadvantages, complications and adverse effects. A number of studies in the literature have investigated the superiority of these techniques over each other. As the number of these studies increase, insight into this debate will gain new dimensions. On the other hand, significant advancements are being achieved in both GA and LA techniques. Keeping the controversy about the selection of best anesthetic technique live will provide significant contributions to continuous development of anesthesia practice. This chapter aims to discuss recent comparisons of GA and LA techniques in line with the current literature after brief explanations of the two methods.

1. GENERAL ANESTHESIA (GA)

GA is defined as a drug-induced condition involving unconsciousness, immobility, amnesia, and antinociception (Brown et al. 2010). Physiological stability is maintained during GA. The main goal of GA is to render a patient unconscious and unable to feel pain stimuli when the anatomic reflexes are controlled (Smith et al. 2021). An ideal general anesthetic technique should provide optimal operation

conditions, and rapid induction and recovery with minimal adverse effects. During GA, the patient is unresponsive to tactile, verbal and painful stimuli (Siddiqui and Kim 2021). The most important impact of GA is its ability to achieve rapid recovery of a patient after termination of surgery. GA allows a patient to tolerate surgical operations that would otherwise cause unbearable pain and physiologic exacerbations. The mechanism of action in GA has not been fully understood. However, it is known that the signals along the nerves that enable passage of stimuli are interrupted and can not be processed by the CNS following induction of GA. Anesthetic agents used in GA include IV anesthetics, inhalational anesthetics, opioids, IV sedatives and neuromuscular blocking drugs. The first general anesthetic used in surgical operations was diethyl ether, followed by the introduction of propofol, halothane, nitrous oxide, xenon and barbiturates (Græsbøll et al. 2016). Commonly used general anesthetics are given in Table 1.

Table 1. Commonly used general anesthetics

Inhaled anesthetics		**Intravenous Anesthetics**	
Gases	**Volatile Liquids**	**Barbiturates**	**Opioids**
Nitrous Oxide	Halothane	Thiopental	Fentanyl
	Enflurane	**Dissociative**	**Benzodiazepines**
	Desflurane	Ketamine	Midazolam
	Isoflurane	**Miscellaneous**	Lorazepam
	Methoxyflurane	Etomidate	Diazepam
	Sevoflurane	Propofol	

GA consists of analgesia, delirium and surgical anesthesia stages. Five goals of GA are shown in Figure 1.

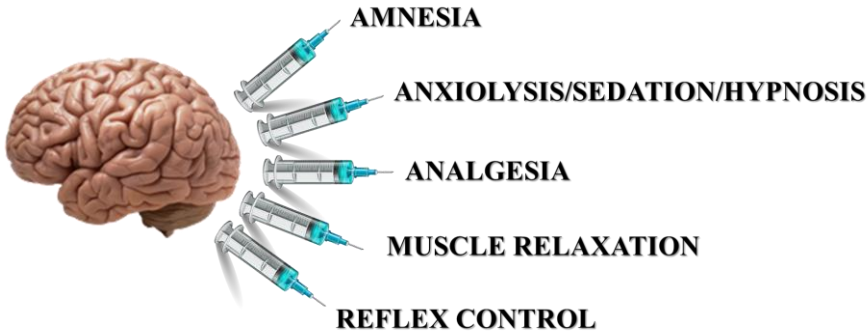

Figure 1. Main goals of general anesthesia

1.1. Indications

Surgical operations that require deep relaxation for long periods of time are best performed under GA. GA is indicated in surgical procedures that cause significant blood loss and affect respiration (Smith et al. 2021). Surgeries that can not be performed with local or regional anesthesia require GA. It is also better to treat uncooperative patients under GA even in simple operations. Finally, the preference of the patient is as important as the discretion of the surgeon in decision-making for undergoing GA.

1.2. Contraindications

Although there is no absolute contraindication for GA, several relative contraindications may limit the use of this anesthetic technique. These include patients with a difficult airway, and significant comorbidities such as severe pulmonary disease, chronic heart failure, and

significant aortic stenosis. Procedures that could be performed using regional anesthesia or neuraxial blockade are a contraindication for GA in terms of avoiding psychological alterations and airway manipulation that are associated with GA (Eichelsbacher et al. 2018). GA is contraindicated in patients with hypersensitivity, myasthenia gravis, acute glaucoma and increased intracranial pressure. A detailed preoperative evaluation should be performed by the anesthesia provider in patients scheduled for GA.

1.3. Advantages

The major advantage of GA is the elimination of feeling pain by interrupting the passage of signals from stimuli to the CNS, that might otherwise be unbearable. GA is an easily and rapidly anesthetic method, which is irreversible and can be used in surgeries with an unpredicted extent. Improved periprocedural imaging and better muscle relaxation are among the advantages of GA (Zorofchi et al. 2018).

1.4. Disadvantages

The main disadvantages of GA include its side effects, including nausea, vomiting, headache, and delay in reverse of amnesia. GA is associated with more complex care and increased costs. Preoperative patient preparation takes a longer time. One of the rarely encountered disadvantages of GA is the development of malignant hyperthermia caused by exposure to some general anesthetics. Malignant hyperthermia may lead to acute and potentially fatal rise in body

temperature, metabolic acidosis, hyperkalemia and hypercarbia (Ndikontar et al. 2020). In addition, a special team of physicians and technicians is required to perform GA.

1.5. Complications

The administration of GA is associated with common adverse effects such as memory loss, urinary retention, dizziness, chills, nausea/vomiting and sore throat. GA also leads to an increased risk for developing significant complications, including brain damage, stroke, heart attack and mortality. The risk of death from GA is associated with several risk factors such as age, gender, underlying medical conditions, allergies, general health status and the current use of alcohol, tobacco products and drugs (Braz et al. 2009). However, death from GA is rare with an estimated rate of 1/150.000 (Barrabé et al. 2020).

2. LOCAL ANESTHESIA

Local anesthesia is used to block the transmission of nerve impulses in the central and peripheral nervous system without causing altered mental status and CNS depression. Local anesthetics anesthetize the skin, subcutaneous tissues and peripheral nerves by blocking autonomic, sensory and motor impulses, respectively (Garmon et al. 2020). Local anesthetics block the transmission of these impulses by blocking voltage-gated sodium channels, and inhibiting sodium entrance into the cells.

Local anesthetics can be administered via topical and subcutaneous routes to the local tissues. Larger nerves can also be anesthetized by administration of anesthetic agents around the peripheral nerves (Dias et al. 2017). Local anesthetics are widely used by many healthcare professionals, includings anesthesiologists, surgeons, primary and intensive care providers and emergency physicians. The first used local anesthetic is cocaine in the 1850s followed by the introduction of other anesthetics, including bupivacaine, lidocaine, articaine, prilocaine and mepivacaine (Moore and Hersh 2010). Commonly used local anesthetics are presented in Table 2.

Table 2. Commonly used local anesthetics

Esters	**Amides**
Butacaine	Articaine
Benzocaine	Bupivacaine
Chloroprocaine	Dibucaine (cinchocaine)
Cocaine (methylbenzoylecgonine)	Etidocaine
Hexylcaine	Lignocaine (lidocaine)
Piperocaine	Mepivacaine
Procaine	Prilocaine
Propoxycaine	Ropivacaine
Tetracaine (amethocaine)	

Because local anesthetic agents are toxic in varying degrees, it is important to know their toxicity and use of the lowest dose possible (Garmon et al. 2020). Several anesthetic agents are being used for

local anesthesia. Characteristics of an ideal local anesthetic are as follows (Moore and Hersh 2010):

- Having little or no allergenicity
- Non-irritating administration
- A rapid onset and adequate duration of anesthesia
- Completely reversible anesthesia
- Minimal systemic toxicity
- Selectivity to nociceptive pathways

2.1. Indications

Local anesthesia is indicated to reduce pain before surgical procedures. Local anesthetic agents have a wide spectrum of clinical use. These agents are infiltrated into the skin and subcutaneous tissues for skin procedures such as skin biopsy, suturing, extraction of foreign bodies etc., into the epidural space for epidural anesthesia and into the subarachnoid space for spinal anesthesia. Topical applications of local anesthetics include patches (before minimally invasive procedures such as placement of intravenous catheters and venipuncture, especially in children), gel form before catheterization of the bladder and spray form before indirect endoscopy, laparoscopy etc.

2.2. Contraindications

Studies have reported allergic reactions for each class of local anesthetics. Anaphylaxis may be seen as ester local anesthetics are metabolized to a para-aminobenzoic acid-like compound (Garmon et

al. 2020). Coagulopathy and local sepsis are relative contraindications of musculoskeletal injections due to the increased risk for developing bleeding and septic complications (Buchko et al. 2015). Some local anesthetics such as lidocaine and IB antiarrhythmics are contraindicated in the treatment of cardiac arrest (Wolfe and Spillars 2018). Local anesthesia may fail when local anesthetics are administered in the region of inflamed tissue. IV administration of local anesthetics should be evaluated for benefits versus risks in some conditions such as pre-fatal ventricular dysrhythmias due to premature ventricular contractions (Haugh 2002).

2.3. Advantages

First of all, local anesthesia prevents some complications seen with GA such as nausea and vomiting. Anesthetic action of local agents lasts for longer than required, resulting in pain relief for several hours following the procedure. Blood loss is reduced by using local anesthesia. The patients undergoing local anesthesia return to their normal activities faster compared to other anesthesia techniques. Patients remain conscious, are able to maintain their own airways, aspiration of gastric contents is unlikely and costs of anesthesia are lower with local anesthesia applications (Yu et al. 2019).

2.4. Disadvantages

Local anesthetics are generally safe and rarely cause serious problems. Local anesthesia has no significant disadvantages once the patient is prepared mentally. On the other hand, local anesthesia is often

unacceptable to the patients. The risk of developing toxicity is higher with some local anesthetic agents. Slow onset of action may cause delays in surgery (El-Boghdadly et al. 2018).

2.5. Complications

Complications caused by local anesthetics maye be local or systemic. Systemic complications of local anesthesia include allergy, systemic toxicity, methemoglobinemia and systemic reactions. Commonly reported local complications are pain during injection, prolongation of anesthesia, infection, hematoma, edema and soft tissue injury.

3. GENERAL ANESTHESIA vs LOCAL ANESTHESIA

In certain procedures, there is no agreement on the method to be chosen for anesthetic management. There are numerous studies in the literature discussing and comparing these two methods and trying to find out which anesthetic technique is superior over the other. Today, research on this issue is still ongoing and for each specific surgical procedure, both general anesthesia (GA) and local anesthesia (LA) have their unique pros and cons. The decision on the selection of the anesthetic method is influenced by several factors, including indications and contraindications, advantages and disadvantages, general status of the patient, underlying diseases and comorbidities, discretion of the surgeon and of course preference of the patient. Comparison of general and local anesthetic methods in selected surgical practices and procedures is discussed below.

3.1. Nasal Bone Fractures

The nose is susceptible to injury because of its central anatomic position and anterior projection on the face (Moraissi et al. 2015). Nasal bone fractures are the most common facial fractures, accounting for 39-45 of all facial fractures (Stroup et al. 2008). Its most common treatment method is surgical manipulation with closed reduction. Studies advocating GA claim that the operation can be performed with less pain and greater accuracy (Khwaja et al. 2007). On the other hand, patients presenting to the emergency service with nasal fractures are usually treated under local anesthesia (LA), sometimes with addition of sedation. In non-cooperative patients, GA becomes mandatory. Studies in the literature have reported that GA is more likely to provide better outcomes in nasal fracture procedures such as rhinoplasty, septoplasty etc., although no statistically significant significant difference between the anesthetic methods has been reported in terms of patient satisfaction and restoring nasal function (Khwaja et al. 2007; Atighechi et al. 2009).

3.2. Inguinal Hernia Surgery

Inguinal hernia repair is one of the most common surgical operations performed on men, although the optimum anesthetic method in these patients remains unclear (Nordin et al. 2003). Postoperative pain is the most common complication and is caused by the activation of the receptors of nerve fibers that are stimulated by tissue injury during inguinal hernia repair. In a study by Callesen et al., no significant

difference was found between GA and LA in terms of cumulative pain scores (Callesen et al. 1999). In another study by Hosseinpour et al., the use of local infiltration for the repair showed significant advantages over GA. Heavy sedation was not required in any patient undergoing LA and operation time was also shorter in these patients (Hosseinpour et al. 2013). In the same study, most patients undergoing LA returned home on the same day, also indicating an economic advantage. However, there are also studies reporting significantly longer operational time with LA (Nordin et al. 2003).

3.3. Cataract Surgery

Cataract is the loss of natural transparency of the eye's lenses. Surgery requiring anesthesia is the only treatment for cataract (RCO 2004). The choice of anesthetic method for cataract surgery is still unclear. In a survey study among ophthalmologists to determine the anesthesia techniques used for cataract surgery, it was found that GA was used only by 10%, while local block alone was used by 55% and combined with sedation by 35% of the participants (Eichel and Goldberg 2005). In another survey study conducted with the members of the American Society of Cataract and Refractive Surgery (ASCRS), it was reported that the use of GA has largely been replaced by equally effective and safer LA techniques (Leaming 2004). In conclusion, the authors of the above mentioned studies concluded that there is no single anesthetic mode to serve as a universal choice for all surgeons and patients. However, the use of GA in cataract surgery seems to be limited to selected special cases.

3.4. Thrombectomy for Acute Ischemic Stroke

Thrombectomy for ischemic stroke accompanied by the occlusion of large vessels significantly reduces disability, although the best anesthetic strategy for the best clinical outcome has yet to be established (Cappellari et al. 2020). In two meta-analyses by Brinjikji et al. and Campbell et al., worse functional outcomes were obtained at three months following mechanical thrombectomy under GA, while no significant difference was found between the two anesthetic methods in the rates of symptomatic intracerebral bleeding and recanalization success (Brinjikji et al. 2017; Campbell et al. 2018). In a multicenter retrospective study, significantly better clinical outcomes and survival were reported with LA compared to GA (Abou-Chebl et al. 2014). It was reported in the study by Cappellari et al. that GA was associated with lower rates of functional outcomes in patients undergoing mechanical thrombectomy. However no significant difference was observed between GA and LA in terms of recanalization success (Cappellari et al. 2020).

3.5. Oncologic Surgery

Until today, there is no human study reporting that LA modifies outcomes following cancer surgery (Cata et al. 2020). In a study by Schalengenhauff et al. including 4329 patients with melanoma, the use of GA was associated with a reduction in survival rate (Schlagenhauff et al. 2000). In a recent study, LA was reported to be associated with longer metastasis-free survival following melanoma surgery (Kofler et al. 2018). In a murine breast cancer model, the use of IV lidocaine

under sevoflurane anesthesia was reported to reduce postoperative lung metastasis by lowering serum metalloproteinase levels (Wall et al. 2019). In another study by Zhang et al., IV use of lidocaine was associated with longer overall survival in patients undergoing surgery due to pancreatic cancer (Zhang et al. 2020). Currently, several randomized controlled studies comparing GA and LA techniques in patients undergoing surgery due to breast, pancreatic, lung and colorectal cancers are underwork (Cata et al. 2020).

3.6. Transcatheter Aortic Valve Implantation (TAVR)

TAVR is a popular surgical procedure performed in patients with severe aortic stenosis. TAVR is being increasingly used as a less invasive alternative treatment option in patients who are not eligible or have a high risk for conventional valve surgery (Lancellotti et al. 2013). The majority of TAVR procedures are performed under GA. However, GA may be associated with an increased peri-procedural risk in patients with severe aortic stenosis (Phillips 2006). There are studies reporting that LA with monitored anesthesia care (MAC) may be as safe and feasible as GA in these patients (Motloch et al. 2012; Yamamoto et al. 2013). MAC is defined as continuous monitoring of cardiovascular and respiratory systems by an experienced anesthesiologist (Fröhlich et al. 2014). MAC has been demonstrated to be a beneficial method for aortic aneurysm repair in a large series of high-risk patients (Ruppert et al. 2007). In a systematic review and meta-analysis by Fröhlich et al. including 7 studies, GA was reported to have potential advantages such as improved perioperative imaging,

while LA with MAC was associated with reduced operational time and shorter length of stay in hospital (Fröhlich et al. 2014) .

3.7. Tympanoplasty

Tympanoplasty is a commonly performed surgery for the repair of perforated tympanic membrane due to chronic suppurative otitis media. Tympanoplasty can be carried out under both GA and LA techniques. Each anesthetic method has its unique advantages and disadvantages during this procedure. The most common complaints of patients during this procedure with LA include anxiety, backache, earache and noise during operation. On the other hand, LA has several advantages in tympanoplasty such as less hemorrhage, early recovery and ability to test hearing of a patient intraoperatively (Panda et al. 2020). However, the majority of tympanoplasty procedures are still performed under GA, because of anxiety, severe hearing loss, inability of patients to cooperate and concern of sudden patient movements during surgery (De Araujo et al. 2009). Despite complications such as nausea/vomiting, dry mouth and hypertension with GA, patients undergoing tympanoplasty mostly prefer this anesthetic method (Panda et al. 2020). On the other hand, there is less need for analgesic immediately after the procedure with LA.

3.8. Primary Spontaneous Pneumothorax

Non-intubated video-assisted thoracoscopic surgery (VATS) has increasingly gained popularity in the surgical treatment of various thoracic diseases. VATS bullectomy is considered the most appropriate surgical method in the case of primary spontaneous

pneumothorax (Jung et al. 2019). In a study by Hwang et al., it was reported that LA can reduce the time between entering the operating room and skin incision, operational time and emergence time (Hwang et al. 2018). In addition, the economic benefit of VATS with LA is high as GA is not required in this technique. Non-intubated VATS through LA reduces the time from admission to discharge. Studies have reported that the average time to ambulation was one day with GA, while patients undergoing non-intubated VATS with LA achieved ambulation on the day of surgery (Tacconi and Pompeo 2016; Umari et al. 2018). On the other hand, no significant difference between VATS with LA and conventional VATS bullectomy has been reported in terms of short-term clinical outcomes and surgical results (Jung et al. 2019).

3.9. Third Molar Extractions

Third molar extractions cause the highest level of patient anxiety (Kazancioglu et al. 2015). Anxiety of these patients is mainly caused by postoperative pain, which is the most common complication following a third molar extraction (Maulina et al. 2017). GA is used in patients with severe anxiety about dental treatment or those who experience vomiting reflex. Studies have reported that GA minimizes anxiety and improves patients' satisfaction (El Batawi et al. 2014). However, GA has several disadvantages during this procedure, including relatively higher risk to general health status, treatment costs and time spent for preparing the anesthesia (Savanheimo et al. 2012). Third molar extractions under GA, operational time can be longer due

to patients experiencing difficulty with mouth opening and positioning (Hidaka et al. 2005). The surgeon should consider shortening the operational time to reduce postoperative pain, possibly with LA.

3.10. Deep Brain Stimulation for Parkinson's Disease

Subthalamic nucleus deep brain stimulation (STN-DBS) has proven efficacy for the treatment of Parkinson's disease, especially side effects of medications. For this purpose, electrode implantation is most commonly performed under LA with awakened patients. However, DBS under LA has several limitations. Patients undergoing DBS have to withstand the entire operation and the incidence of DBS lead passes is higher than with GA (Tsai et al. 2019). The advantages of GA in this procedure include more accurate intraoperative imaging, blood pressure stabilization and still position of the patient (Brodsky et al. 2017). There are studies reporting similar short-term surgical outcomes following STN-DBS with GA and LA (Chen et al. 2011; Fluchere et al. 2013). Furthermore, in a study by Tsai et al., long-term (5 years) effectiveness and safety of STN-DBS under GA was similar to STN-DBS under LA (Tsai et al. 2019).

CONCLUSION

Studies comparing general and local anesthesia techniques in surgical treatment of specific diseases are ongoing. Currently, there are no specific guidelines or standards regarding the selection of anesthetic methods. Both anesthetic methods have their own indications and contraindications, advantages and disadvantages, and complications. In general, GA is associated with more severe postoperative pain,

longer operational time, longer time from admission to discharge and treatment costs. However, it is still preferred especially in patients who can not tolerate local anesthesia and who are unable to cooperate. Selection of the appropriate anesthetic methods depends on multiple factors, including anxiety and risk levels of the patient, general health status, indications, contraindications, discretion of the surgeon and of course patient preferences. As the number of studies comparing GA and LA increase, more accurate decisions will be made about the anesthetic technique that will be used. Nevertheless, the ongoing debate on anesthetic choice seems to continue at least in near future.

REFERENCES

Abou-Chebl, A., Zaidat, O. O., Castonguay, A. C., Gupta, R., Sun, C. H., Martin, C. O., Holloway, W. E., Mueller-Kronast, N., English, J. D., Linfante, I., Dabus, G., Malisch, T. W., Marden, F. A., Bozorgchami, H., Xavier, A., Rai, A. T., Froehler, M. T., Badruddin, A., Nguyen, T. N., Taqi, M., … Nogueira, R. G. (2014). North American SOLITAIRE Stent-Retriever Acute Stroke Registry: choice of anesthesia and outcomes. Stroke, 45(5), 1396–1401.

Al-Moraissi, E. A., & Ellis, E., 3rd (2015). Local versus general anesthesia for the management of nasal bone fractures: a systematic review and meta-analysis. Journal of oral and maxillofacial surgery : official journal of the American Association of Oral and Maxillofacial Surgeons, 73(4), 606–615.

Atighechi, S., Baradaranfar, M. H., & Akbari, S. A. (2009). Reduction of nasal bone fractures: a comparative study of general, local, and topical anesthesia techniques. The Journal of craniofacial surgery, 20(2), 382–384.

Barrabé, A., Louvrier, A., Allary, R., Moussa, M., Boutros, M., & Bénateau, H. (2020). Infantile and adult mortality in precarious conditions. Journal of stomatology, oral and maxillofacial surgery, 121(1), 49–52.

Braz, L. G., Braz, D. G., Cruz, D. S., Fernandes, L. A., Módolo, N. S., & Braz, J. R. (2009). Mortality in anesthesia: a systematic review. Clinics (Sao Paulo, Brazil), 64(10), 999–1006.

Brinjikji, W., Pasternak, J., Murad, M. H., Cloft, H. J., Welch, T. L., Kallmes, D. F., & Rabinstein, A. A. (2017). Anesthesia-Related Outcomes for Endovascular Stroke Revascularization: A Systematic Review and Meta-Analysis. Stroke, 48(10), 2784–2791.

Brodsky, M. A., Anderson, S., Murchison, C., Seier, M., Wilhelm, J., Vederman, A., & Burchiel, K. J. (2017). Clinical outcomes of asleep vs awake deep brain stimulation for Parkinson disease. Neurology, 89(19), 1944–1950.

Brown, E. N., Pavone, K. J., & Naranjo, M. (2018). Multimodal General Anesthesia: Theory and Practice. Anesthesia and analgesia, 127(5), 1246–1258.

Buchko, J. Z., Gurney-Dunlop, T., & Shin, J. J. (2015). Knee chondrolysis by infusion of bupivacaine with epinephrine through an intra-articular pain pump catheter after arthroscopic ACL reconstruction. The American journal of sports medicine, 43(2), 337–344.

Callesen, T., Bech, K., Andersen, J., Nielsen, R., Roikjaer, O., & Kehlet, H. (1999). Pain after primary inguinal herniorrhaphy: influence of surgical technique. Journal of the American College of Surgeons, 188(4), 355–359.

Campbell, B., van Zwam, W. H., Goyal, M., Menon, B. K., Dippel, D., Demchuk, A. M., Bracard, S., White, P., Dávalos, A., Majoie, C., van der Lugt, A., Ford, G. A., de la Ossa, N. P., Kelly, M., Bourcier, R., Donnan, G. A., Roos, Y., Bang, O. Y., Nogueira, R. G., Devlin, T. G., … HERMES collaborators (2018). Effect of general anaesthesia on functional outcome in patients with anterior circulation ischaemic stroke having endovascular thrombectomy versus standard care: a meta-analysis of individual patient data. The Lancet. Neurology, 17(1), 47–53.

Cappellari, M., Pracucci, G., Forlivesi, S., Saia, V., Nappini, S., Nencini, P., Inzitari, D., Greco, L., Sallustio, F., Vallone, S., Bigliardi, G., Zini, A., Pitrone, A., Grillo, F., Musolino, R., Bracco, S., Tinturini, R., Tassi, R., Bergui, M., Cerrato, P., … Mangiafico, S. (2020). General Anesthesia Versus Conscious Sedation and Local Anesthesia During Thrombectomy for Acute Ischemic Stroke. Stroke, 51(7), 2036–2044.

Cata, J. P., Guerra, C., Soto, G., & Ramirez, M. F. (2020). Anesthesia Options and the Recurrence of Cancer: What We Know so Far?. Local and regional anesthesia, 13, 57–72.

Chen, S. Y., Tsai, S. T., Lin, S. H., Chen, T. Y., Hung, H. Y., Lee, C. W., Wang, W. H., Chen, S. P., & Lin, S. Z. (2011). Subthalamic deep brain stimulation in Parkinson's disease under different anesthetic modalities: a comparative cohort study. Stereotactic and functional neurosurgery, 89(6), 372–380.

Dias, R., Dave, N., Tullu, M. S., & Deshmukh, C. T. (2017). Local anaesthetic systemic toxicity following oral ingestion in a child: Revisiting dibucaine. Indian journal of anaesthesia, 61(7), 587–589.

Eichel, R., & Goldberg, I. (2005). Anaesthesia techniques for cataract surgery: a survey of delegates to the Congress of the International Council of Ophthalmology, 2002. Clinical & experimental ophthalmology, 33(5), 469–472.

Eichelsbacher, C., Ilper, H., Noppens, R., Hinkelbein, J., & Loop, T. (2018). “Rapid sequence induction and intubation“ beim aspirationsgefährdeten Patienten : Handlungsempfehlungen für das praktische anästhesiologische Management [Rapid sequence induction and intubation in patients with risk of aspiration : Recommendations for action for practical management of anesthesia]. Der Anaesthesist, 67(8), 568–583.

El Batawi, H. Y., Panigrahi, P., & Awad, M. A. (2014). Perceived outcomes and satisfaction of Saudi parents and their children following dental rehabilitation under general anesthesia: A 2-year follow-up. Journal of International Society of Preventive & Community Dentistry, 4(Suppl 3), S153–S160.

El-Boghdadly, K., Pawa, A., & Chin, K. J. (2018). Local anesthetic systemic toxicity: current perspectives. Local and regional anesthesia, 11, 35–44.

Fluchere, F., Witjas, T., Eusebio, A., Bruder, N., Giorgi, R., Leveque, M., Peragut, J. C., Azulay, J. P., & Regis, J. (2014). Controlled general anaesthesia for subthalamic nucleus stimulation in Parkinson's disease. Journal of neurology, neurosurgery, and psychiatry, 85(10), 1167–1173.

Fröhlich, G. M., Lansky, A. J., Webb, J., Roffi, M., Toggweiler, S., Reinthaler, M., Wang, D., Hutchinson, N., Wendler, O., Hildick-Smith, D., & Meier, P. (2014). Local versus general anesthesia for transcatheter aortic valve implantation (TAVR)--systematic review and meta-analysis. BMC medicine, 12, 41.

Garmon, E. H., & Huecker, M. R. (2020). Topical, Local, and Regional Anesthesia and Anesthetics. In StatPearls. StatPearls Publishing.

Graesbøll, K., Sasse-Middelhoff, H., & Heimburg, T. (2014). The thermodynamics of general and local anesthesia. Biophysical journal, 106(10), 2143–2156.

Haugh K. H. (2002). Antidysrhythmic agents at the turn of the twenty-first century: a current review. Critical care nursing clinics of North America, 14(1), 53–69.

Hidaka, S., Nakagawa, I., Uesugi, F., Kubo, T., Hamaguchi, K., & Kato, T. (2005). Masui. The Japanese journal of anesthesiology, 54(4), 370–375.

Hosseinpour M., Behdad A., Resaei M. (2013). Assessment of the effect of local versus general anesthesia on the pain perception after inguinal hernia surgery. Ambulatory Surgery. 19 (1):10-12.

Hwang, J., Shin, J. S., Son, J. H., & Min, T. J. (2018). Non-intubated thoracoscopic bullectomy under sedation is safe and comfortable in the perioperative period. Journal of thoracic disease, 10(3), 1703–1710.

Jung, J., Kim, D. H., Son, J., Lee, S. K., & Son, B. S. (2019). Comparative study between local anesthesia and general anesthesia in the treatment of primary spontaneous pneumothorax. Annals of translational medicine, 7(20), 553.

Kazancioglu, H. O., Tek, M., Ezirganli, S., & Demirtas, N. (2015). Does watching a video on third molar surgery increase patients' anxiety level?. Oral surgery, oral medicine, oral pathology and oral radiology, 119(3), 272–277.

Khwaja, S., Pahade, A. V., Luff, D., Green, M. W., & Green, K. M. (2007). Nasal fracture reduction: local versus general anaesthesia. Rhinology, 45(1), 83–88.

Kofler, L., Breuninger, H., Häfner, H. M., Schweinzer, K., Schnabl, S. M., Eigentler, T. K., & Leiter, U. (2018). Lymph node dissection for melanoma using tumescence local anaesthesia: an observational study. European journal of dermatology : EJD, 28(2), 177–185.

Lancellotti, P., Rosenhek, R., Pibarot, P., Iung, B., Otto, C. M., Tornos, P., Donal, E., Prendergast, B., Magne, J., La Canna, G., Piérard, L. A., & Maurer, G. (2013). ESC Working Group on Valvular Heart Disease position paper--heart valve clinics: organization, structure, and experiences. European heart journal, 34(21), 1597–1606.

Leaming D. V. (2004). Practice styles and preferences of ASCRS members--2003 survey. Journal of cataract and refractive surgery, 30(4), 892–900.

Maulina, T., Djustiana, N., & Shahib, M. N. (2017). The Effect of Music Intervention on Dental Anxiety During Dental Extraction Procedure. The open dentistry journal, 11, 565–572.

Moore, P. A., & Hersh, E. V. (2010). Local anesthetics: pharmacology and toxicity. Dental clinics of North America, 54(4), 587–599.

Motloch, L. J., Rottlaender, D., Reda, S., Larbig, R., Bruns, M., Müller-Ehmsen, J., Strauch, J., Madershahian, N., Erdmann, E., Wahlers, T., & Hoppe, U. C. (2012). Local versus general anesthesia for transfemoral aortic valve implantation. Clinical research in cardiology : official journal of the German Cardiac Society, 101(1), 45–53.

Ndikontar, R., Etoundi, P. O., Tochie, J. N., Bengono, R., & Minkande, J. Z. (2020). Malignant hyperthermia, a rare perioperative complication: case series and literature review. Oxford medical case reports, 2020(11), omaa101.

Nordin, P., Zetterström, H., Gunnarsson, U., & Nilsson, E. (2003). Local, regional, or general anaesthesia in groin hernia repair: multicentre randomised trial. Lancet (London, England), 362(9387), 853–858.

Panda S., Naik C. , Nanda R. Panda B., K. (2020). Is general anaesthesia better for tympanoplasty than local anaesthesia? JEvid Based Med Healthc 2020; 7(37), 2033-2037.

Phillips D. (2006). Aortic stenosis: a review. AANA, 74:309–315

RCO The Royal College of Ophthalmologists. Cataract surgery guidelines. London: The College; 2004. Available: http://www.rcophth.ac.uk/docs/publications/CataractSurgeryGuidelinesMarch2005Updated.pdf (Access Date: 25/07/2021).

Ruppert, V., Leurs, L. J., Rieger, J., Steckmeier, B., Buth, J., Umscheid, T., & EUROSTAR Collaborators (2007). Risk-adapted outcome after endovascular aortic aneurysm repair: analysis of anesthesia types based on EUROSTAR data. Journal of endovascular therapy : an official journal of the International Society of Endovascular Specialists, 14(1), 12–22.

Sarmento, K. M., Jr, & Tomita, S. (2009). Retroauricular tympanoplasty and tympanomastoidectomy under local anesthesia and sedation. Acta oto-laryngologica, 129(7), 726–728.

Savanheimo, N., Sundberg, S. A., Virtanen, J. I., & Vehkalahti, M. M. (2012). Dental care and treatments provided under general anaesthesia in the Helsinki Public Dental Service. BMC oral health, 12, 45.

Schlagenhauff, B., Ellwanger, U., Breuninger, H., Stroebel, W., Rassner, G., & Garbe, C. (2000). Prognostic impact of the type of anaesthesia used during the excision of primary cutaneous melanoma. Melanoma research, 10(2), 165–169.

Siddiqui BA, Kim PY. (2021). Anesthesia Stages. In: StatPearls. Treasure Island (FL): StatPearls Publishing; March 7, 2021.

Smith G., D'Cruz J., R., Rondeau B., Goldman J. (2021). General Anesthesia for Surgeons. In: StatPearls. Treasure Island (FL): StatPearls Publishing; April 8, 2021.

Stroup, D. F., Berlin, J. A., Morton, S. C., Olkin, I., Williamson, G. D., Rennie, D., Moher, D., Becker, B. J., Sipe, T. A., & Thacker, S. B. (2000). Meta-analysis of observational studies in epidemiology: a proposal for reporting. Meta-analysis Of Observational Studies in Epidemiology (MOOSE) group. JAMA, 283(15), 2008–2012.

Tacconi, F., & Pompeo, E. (2016). Non-intubated video-assisted thoracic surgery: where does evidence stand?. Journal of thoracic disease, 8(Suppl 4), S364–S375.

Tsai, S. T., Chen, T. Y., Lin, S. H., & Chen, S. Y. (2019). Five-Year Clinical Outcomes of Local versus General Anesthesia Deep Brain Stimulation for Parkinson's Disease. Parkinson's disease, 2019, 5676345.

Umari, M., Falini, S., Segat, M., Zuliani, M., Crisman, M., Comuzzi, L., Pagos, F., Lovadina, S., & Lucangelo, U. (2018). Anesthesia and fast-track in video-assisted thoracic surgery (VATS): from evidence to practice. Journal of thoracic disease, 10(Suppl 4), S542–S554.

Wall, T. P., Crowley, P. D., Sherwin, A., Foley, A. G., & Buggy, D. J. (2019). Effects of Lidocaine and Src Inhibition on Metastasis in a Murine Model of Breast Cancer Surgery. Cancers, 11(10), 1414.

Wolfe, R. C., & Spillars, A. (2018). Local Anesthetic Systemic Toxicity: Reviewing Updates From the American Society of Regional Anesthesia and Pain Medicine Practice Advisory. Journal of perianesthesia nursing: official journal of the American Society of PeriAnesthesia Nurses, 33(6), 1000–1005.

Yamamoto, M., Meguro, K., Mouillet, G., Bergoend, E., Monin, J. L., Lim, P., Dubois-Rande, J. L., & Teiger, E. (2013). Effect of local anesthetic management with conscious sedation in patients undergoing transcatheter aortic valve implantation. The American journal of cardiology, 111(1), 94–99.

Yu S., Wang B., Zhang J., Fang K. (2019). The development of local anesthetics and their applications beyond anesthesia. Int J Clin Exp Med;12(12):13203-13220.

Zhang, H., Yang, L., Zhu, X., Zhu, M., Sun, Z., Cata, J. P., Chen, W., & Miao, C. (2020). Association between intraoperative intravenous lidocaine infusion and survival in patients undergoing pancreatectomy for pancreatic cancer: a retrospective study. British journal of anaesthesia, 125(2), 141–148.

Zorofchi B., H., Jahan E., Nassiri S., Najmodin A., Saffarieh E. (2018). Comparing Spinal and General Anesthesia in terms of Postoperative Pain in Patients undergoing Hysterectomy. J Obstet Gynecol Cancer Res;3(2):73-77.

CHAPTER 6

HYPERTENSION IN PREGNANCY

Spec. MD. Meral MEŞE[1]

[1] Dr.Lütfi Kırdar City Hospital,Nephrology,Istanbul,Turkey, mesemeral@gmail.com

INTRODUCTION

Hypertensive disorders of pregnancy are the second most common cause for maternal death worldwide, after hemorrhage (17)And affects 10% to 12% of all pregnancies. In normal pregnancy, blood pressure (BP) characteristically reaches its lowest level in the second trimester, beginning in the first trimester, and only rises to pre-pregnancy levels towards the end of the third trimester.Hypertension-related diseases are seen in 5-10% of pregnancies. Hypertension (HT) is defined as systolic blood pressure (SBP) ≥140mmHg and/or diastolic blood pressure (DBP) ≥90mmHg at any time during pregnancy at least two different times (14,16)

HT during pregnancy is a condition that should be followed closely and carefully due to fetal complications such as intrauterine growth retardation, low birth weight, perinatal death, as well as maternal complications resulting in hemorrhagic cerebrovascular disease, kidney damage, disseminated intravascular coagulation, premature birth and death (18)

The four major hypertensive disorders that occur in pregnant women are:

- Preeclampsia/eclampsia/HELLP syndrome (hemolysis, elevated liver enzymes, low platelets)
- Chronic HT
- Preeclampsia superimposed on chronic HT
- Gestational HT

Preeclampsia/Eclampsia/HELLP Syndrome:

Preeclampsia is a pregnancy-specific condition that affects 3-5% of pregnancies and is the presence of proteinuria and/or end-organ dysfunction accompanying HT after 20 weeks of gestation in a woman who was known to be normotensive before pregnancy (30).

In the 2013 report of the American College of Obstetricians and Gynecologist (ACOG), it was decided that proteinuria is not necessary for the diagnosis, since severe disease was detected without proteinuria. However, it was stated that the presence of any multisystemic organ accompanying HT is sufficient for the diagnosis. In addition, since massive proteinuria (5 g/24 hours) was poorly correlated with survival it was excluded from the criteria for serious disease. Fetal growth retardation and oliguria are also no longer considered features of severe disease (27).

Reasons such as abnormal placental implantation, ischemia-reperfusion damage caused by maternal endothelial dysfunction, oxidative stress, deterioration in the balance of hypoxia-induced angiogenic factors in favor of vasoconstriction (activation of the sympathetic system, angiotensin 2, endothelin, thromboxane, increase in vasopressin and uric acid levels) are responsible for the pathogenesis of preeclampsia (22).

Risk factors for preeclampsia; multiple pregnancy, obesity diabetes mellitus, chronic hypertension, chronic kidney disease, autoimmune diseases, advanced age pregnancy, low socioeconomic status, preeclampsia in previous pregnancies (3) .

According to the ACOG 2013 report, preeclampsia is defined as:

de novo hypertension (BP> 140/90mmHg, measured twice for at least 4 hours)manifesting after 20 weeks of gestation combined with one or more of the following:

- Proteinuria (spot urine protein/creatinine >30 mg/mmol [0.3 mg/mg] or >300 mg/day or at least 1 g/l [2+] on dipstick testing)
- Other maternal organ dysfunction: Renal impairment (serum creatinine ≥90 µmol/l [1 mg/dl]), liver involvement (elevated transaminases—at least twice the upper limit of normal ± right upper quadrant or epigastric abdominal pain), neurologic complications (e.g., eclampsia, altered mental status, blindness, stroke, or, more commonly, hyperreflexia with clonus, severe headaches with hyperreflexia, persistent or unresponsive headache to analgesic treatment, mental status change, persistent visual scotomata), hematologic complications (thrombocytopenia —platelet count below 100×10^9/l, DIC, hemolysis), development of pulmonary edema

Eclampsia, on the other hand, refers to the occurrence of a grand mal seizure in the absence of other neurological conditions that could explain the seizure in a woman with preeclampsia. Although the pathophysiology is not clearly known, it is thought that high blood pressure causes cerebral circulation disorder (26).It should not be forgotten that eclampsia can also develop after delivery.

HELLP syndrome (Hemolysis, Elevated Liver enzymes, Low Platelets) probably represents a subtype of preeclampsia. It is a clinical picture in which hemolysis, elevated liver enzymes and thrombocytopenia are more prominent, accompanied by HTor central nervous system or kidney dysfunction.

Chronic Hypertension

Chronic HT is defined as HT that occurs before pregnancy or is detected at least twice before the 20th week of pregnancy, or that persists for more than 12 weeks postpartum. It can be primary or secondary to chronic kidney disease, adrenal tumors (primary hyperaldosteronism, pheochromocytoma), or renovascular HT. It is difficult to distinguish between chronic HT and gestational HT in pregnant women presenting after the 20th week of pregnancy (9).

Its prevalance is 1-5% of all pregnancies and increasing gestational age and obesity contribute to this situation. A pregnant woman with chronic HT has a 25% risk of preeclampsia. It is also associated with premature birth, intrauterine growth retardation, ablatio placenta and perinatal mortality (23,28). It should be confirmed by 24-hour ambulatory BP monitoring or home self-monitoring to exclude white coat hypertension, which is common in pregnancy. Women with white coat hypertension may be managed without medication through regular home BP monitoring. A small proportion will go on to develop preeclampsia (17)

Preeclampsia Superimposed on Chronic Hypertension

It occurs with the addition of preeclampsia findings during pregnancy in a patient with pre-pregnancy hypertension. Hypertensive state with the highest number of complications associated with maternal and fetal complications. Preeclampsia added to chronic hypertension should be suspected if there is a gradual increase in blood pressure, resistance to antihypertensive treatment, and an increase in proteinuria in a pregnant woman with chronic hypertension (24).

Gestational Hypertension

A new onset of BP after the 20th week of pregnancy and returning to normal at the postpartum 12th week is called gestational HT. For the diagnosis of gestational HT, the patient should not have preeclampsia findings. Risk factors for gestational HT are multiple pregnancy, obesity, and a history of preeclampsia in previous pregnancies. The earlier the age at which gestational HT is detected, the higher the risk of developing pereeclampsia (11).

Because of the typical reduction in BP that occurs in early pregnancy, a woman with pre-existing HT may be found to be normotensive on her first gynecological examination. In this case, the factors described below may be helpful in determining the possible diagnosis;

- HT occurring before the 20th week is usually due to chronic hypertension rather than preeclampsia,
- Proteinuria is usually present and increases over time in preeclampsia, occasionally reaching the nephrotic range,

- Hypertensive nephrosclerosis is associated with very modest proteinuria (1 to 2 g/day) but rarely occurs in young women (8)
- Preeclampsia is more common in nulliparas than multiparas,
- Preeclampsia is more common in older (>40 years) than younger nulliparas,
- Older women (nulliparous or multiparous) are also more likely to have chronic HT.

HT may also be a manifestation of severe autonomic dysfunction associated with a primary neurological disorder such as Guillain-Barré syndrome, paroxysmal sympathetic hyperactivity, multiple system atrophy syndrome, or acute spinal cord injury.

Also, in the presence of tachycardia associated with HT hyperthyroidism should be investigated. In the presence of hypertensive patients with hypercalcemia, hyperparathyroidism should be considered. Hyperaldosteronism should be investigated in hypertensive pregnant women with hypokalemia. In suspected patients, endocrinological causes such as Cushing should not be overlooked.

TREATMENT

The aim of treatment in a pregnant woman with high BP is to prevent maternal and fetal complications. In patients using angiotensin receptor blockers or angiotensin converting enzyme inhibitors as antihypertensive therapy, these drugs should be discontinued at least 6

weeks before pregnancy and switched to an antihypertensive agent that is safe to use during pregnancy.

ACOG 2013 report recommends starting treatment when systolic blood pressure (SBP) is >160mmHg or diastolic blood pressure (DBP) >110mmHg, but it is recommended to keep BP pressure at 140/90 mmHg if there are signs of maternal organ damage and fetal hypoperfusion.

In the report of the "International Society of Hypertension in Pregnancy" published in 2018, it is recommended to start treatment if the office BP is 140/90 mmHg and above, and 135/385mmHg and above in home measurements. In the same report, it was emphasized that the decision to start treatment should be individualized according to the patient's clinical signs and symptoms, not according to a specific BP value (12,7).Low-dose aspirin therapy (60-80mg) is recommended for pregnant women at high risk of preeclampsia to prevent preeclampsia. (12)

The definitive treatment for a pregnant woman with preeclampsia and eclampsia is delivery. In mild preeclampsia, it can be expected up to 37 weeks and in severe preeclampsia can be 34 weeks. If delivery is planned before the 34th week of pregnancy due to maternal and fetal complications, steroid therapy should be given for fetal lung development (14)

Severe HT is defined as SBP ≥160 mmHg and/or DBP ≥110 mmHg lasting longer than 15 minutes. In order to reduce the risk of serious

maternal complications such as stroke and heart failure, treatment should be started as soon as possible (30-60 minutes). Severe systolic HT presents a higher risk for cerebral events than severe diastolic hypertension (15)

Some conclusions were drawn by meta-analyses of randomized trials against treatment versus no treatment for pregnant women with chronic or non-pregnancy-related non-severe HT (1,5,31).These are:

- Antihypertensive treatment did **not** reduce the occurrence of preeclampsia, perinatal death, preterm birth, or abruptio placentae,
- A 40 to 70 percent reduction in the occurrence of severe HT has been found with antihypertensive therapy given during pregnancy
- Antihypertensive treatment did not increase the frequency of delivery of a small for gestational age infant.

Antihypertensive treatment should be started or the current treatment dose should be increased in pregnant women with SBP ≥150 mmHg or DBP ≥100 mmHg lasting longer than 15 minutes.

In adolescents and young women with low baseline BP (less than 90/75 mmHg), treatment may also be initiated at lower BP levels if cardiac decompensation or cerebral symptoms are observed (21).

All antihypertensive drugs cross the placenta. There are no data from large well-designed randomized trials to base a strong

recommendation for use of one drug over another. Given the significant methodological weaknesses and lack of statistical power of the available studies, it is not possible to draw clear conclusions about the effect of these drugs on pregnancy and the fetüs (13,6).

Oral agents methyldopa, nifedipine and labetalol are the first choice in antihypertensive treatment in pregnancy; Second-line therapy includes oral hydralazine. While the first options in intravenous antihypertensive treatment are labetalol and nicardipine; Agents that can be used in the second step are hydralazine and nitroprusside.

Methyldopa — Methyldopa has been widely used in pregnant women and its long-term safety for the fetus has been demonstrated (19)
It is a central alpha 2 adrenergic agonist and used orally as 500mg-3gr/day in 2-4 divided doses. Its effect starts 3-6 hours after the drug is taken and makes a moderately effective blood pressure decrease. Any women will not achieve blood pressure goals on this oral agent or are bothered by its sedative effect at high doses. It has side effects such as increased liver function tests, depression, dry mouth, and hemolytic anemia (10)

Calcium Channel Blockers-Nifedipine is a dihydropyridine calcium channel blocker and is the most widely used drug in this class in pregnancy. It is used at a dose of 30-120mg/day orally. It also has a preventive effect on preterm birth. Side effects are headache, flushing, peripheral edema, reflex tachycardia.

Beta blockers-Labetalol - a non-selective beta-blocker- is the most preferred drug in this class because in early experimental studies it was found to protect uteroplacental blood flow more than other beta blockers.It is taken orally in 2-3 doses at a dose of 200-1200mg/day. In intravenous therapy, 1mg/min is used as a maximum of 300mg/day. It has bronchospasm, hypotension, fetal bradycardia and hypoglycemic side effects. It should not be used in pregnant women with asthma (32).Metoprolol and pindolol can be alternative agents

Beta-adrenergic blockers without alpha-blocking properties (eg, atenolol) should be avoided when used in early pregnancy as they are associated with slightly lower placental and fetal weights at birth. Since myometrial relaxation of the uterus is a beta-2 receptor-mediated process, non-selective beta-adrenergic blockers (e.g. propranolol) may counteract the effect of beta-2 stimulation and are therefore not preferred for treatment.

Hydralazine-It is a direct-acting vasodilator agent. Oral 50-300mg/day is used in 2-4 divided doses. In intravenous therapy, 5-10mg, maximum 20mg is used. It has side effects such as hypotension, fetal thrombocytopenia, lupus-like picture, nausea, headache, and flushing (20). The hypotensive response to intravenous hydralazine is less predictable than that seen with labetalol.

Sodium Nitroprusside-It is used in severe HT and hypertensive encephalopathy that does not respond to treatment. It is used intravenously at a dose of 0.3-2mcq/kg/min. May cause fetal cyanide

poisoning if used for more than four hours.Thats why its use should be limited to a short period of time in an emergency situation (25).

Magnesium sulfate is given to prevent eclampsia in a preeclamptic pregnant woman. After a loading dose of 4-6 g intravenous magnesium sulfate in 15-20 minutes, it is continued as an infusion of 1-2 g per hour (2).

Breastfeeding does not increase BP.Beta blockers and calcium channel blockers pass into breast milk; however, most appear to be safe for the baby during breastfeeding (4).

The rate at which blood pressure is brought to safe levels is controversial. Cerebral or myocardial ischemia or infarction can be induced if tissue perfusion becomes too low with aggressive antihypertensive therapy. Therefore, it may be relatively safe to reduce mean arterial pressure by up to 25 percent within two hours to achieve target blood pressures of 130 to 150 mmHg systolic and 80 to 100 mmHg diastolic with initial therapy (29).

The BP pressure of women who have borderline BP before discharge and do not use any antihypertensive medication should be closely monitored after discharge; If possible, BP monitoring at home is helpful. In addition, BP of women receiving antihypertensive therapy should be closely monitored to prevent hypotension as BP returns to normal baseline. If pre-pregnancy BP is normal and the patient is not hypertensive on the drug, it is reasonable to stop the antihypertensive

agent after three weeks and monitor BP to assess whether further treatment is necessary.

REFERENCES

1- Abalos,E., Duley,L., Steyn, D.W.,& Gialdini, C. (2018). Antihypertensive drug therapy for mild to moderate hypertension during pregnancy. *Cochrane Database Syst Rev*; 10:CD002252.

2- Altman,D.,Carroli,G.,Duley,L.,Farrell,B.,Moodley,J.,Neilson,J.,& Smith,D. (2002). Magpie Trial Collaboration Group. Do women with pre-eclampsia, and their babies, benefit from magnesium sulphate? The Magpie Trial: A randomised placebo-controlled trial. *Lancet*, *359* (9321), 1877-90.

3-Bartsch,E.,Medcalf,KE.,Park,AL.,&Ray,JG.(2016) High risk of pre-eclampsia identification group. Clinical risk factors for pre-eclampsia determined in early pregnancy: systematic review and meta-analysis of large cohort studies. *BMJ*, *19*,353,i1753.

4-Beardmore,KS.,Morris,JM.,&Gallery,ED.(2002) Excretion of antihypertensive medication into human breast milk: a systematic review. *Hypertens Pregnancy*; *21*(85).

5- Bellos, I,, Pergialiotis, V., & Antsaklis, A., et al. (2020).Safety of non-steroidal anti-inflammatory drugs in postpartum period in women with hypertensive disorders of pregnancy: systematic review and meta-analysis. *Ultrasound Obstet Gynecol*, *56* (329).

6- Boesen, EI. (2017) Consequences of in-utero exposure to antihypertensive medication: the search for definitive answers continues. *J Hypertens*,*35*,2161.

7- Brown,M.A.,Magee,L.A.,Kenny,L.C.,Karumanchi, S.A., McCarthy, F.P., Saito, S., Hall, D.R., Warren, C.E., Adoy, G., & Ishaku, S. (2018) International Society for the Study of Hypertension in Pregnancy (ISSHP). Hypertensive Disorders of Pregnancy: ISSHP Classification, Diagnosis, and Management Recommendations for International Practice. *Hypertension.72*(1),24-43

8- Campbell,D.M., MacGillivray, I., & Carr-Hill,R.(1985) Pre-eclampsia in second pregnancy. *Br J Obstet Gynaecol*, *92*(131).

9- Chahine,K.M.,& Sibai,B.M.(2019) Chronic hypertension in pregnancy: New concepts for classification and management. *Am J Perinatol.36*(2),161-168.

10- Cockburn,J., Moar,V.A., Ounsted, M.,& Redman, C.W. (1982) Final report of study on hypertension during pregnancy: The effects of specific treatment on the growth and development of the children. *Lancet.1*(8273),647-9.

11- Cruz,M.O.,Gao,W.&,Hibbard,J.U.(2011) Obstetrical and perinatal outcomes among women with gestational hypertension, mild preeclampsia, and mild chronic hypertension. *Am J Obstet Gynecol. 205*(3),260.e1-9

12- El Farra,J.,Bean,C.,& Martin,J.N (2016) Management of hypertensive crisis for the obstetrician/gynecologist. *Obstet Gynecol Clin North Am. 43*(4),623-637. https://doi.org/10.1016/j.ogc.07.005 PMID: 27816151.

13- Fitton, C.A, Steiner, M.,F.,C.,& Aucott, L. et al.(2017) In-utero exposure to antihypertensive medication and neonatal and child health outcomes: a systematic review. *J Hypertens , 35* (2123)

14- Hypertension in pregnancy. Report of the American College of Obstetricians and Gynecologists' Task Force on Hypertension in Pregnancy.(2013) *Obstet Gynecol.,122*(5),1122-1131

15- Judy, A.E., McCain, C.L., & Lawton, E.S. et al. (2019) Systolic hypertension, preeclampsia-related mortality, and stroke in California. *Obstet Gynecol*

16- Lowe, S.A., Bowyer, L., Lust, K., McMahon, L.P., Morton, M., North, R.A., Paech, M.,& Said, J.M. (2015) Guidelines for the management of hypertensive disorders of pregnancy . *N Z J Obstet Gynaecol.,55*(5),e1-29.

17- M.A., Brown, G., Mangos, G., Davis, & C., Homer (2005) The natural history of white coat hypertension during pregnancy. *BJOG. 112* (5), 601-606 PMID:15842284

18- Magee,L.A., Pels, A., Helewa, M., Rey, E.,& von Dadelszen, P.; (2014)Canadian hypertensive disorders of pregnancy (HDP) working group. diagnosis, evaluation, and management of the hypertensive disorders of pregnancy. *Pregnancy Hypertens.,4*(2):105-45

19- Magee, L.A., CHIPS Study Group, von Dadelszen, P., et al. (2016) Do labetalol and methyldopa have different effects on pregnancy outcome?

Analysis of data from the control of hypertension in pregnancy study (CHIPS) trial. *BJOG* , 123:1143.

20- Magee, L.A., Cham, C., Waterman, E.J., Ohlsson, A.,& von Dadelszen, P. (2003) Hydralazine for treatment of severe hypertension in pregnancy: meta-analysis. *BMJ.25*;327(7421):955-60. https://doi.org/ 10.1136/bmj.327.7421.955. PMID: 14576246

21- Martin, J.N. Jr., Thigpen, B.D., & Moore, R.C., et al. (2005)Stroke and severe preeclampsia and eclampsia: a paradigm shift focusing on systolic blood pressure. *Obstet Gynecol* , 105:246.

22-Phipps,E.A.,Thadhani,R.,Benzing,T.,& Karumanchi,S.A. (2019) Pre-eclampsia: pathogenesis, novel diagnostics and therapies. *Nat Rev Nephrol.,15*(5):275-289.

23- Poston, L., Briley, A.L., Seed, P.T., Kelly, F.J.,& Shennan, A.H.(2006); Vitamins in Pre-eclampsia (VIP) trial consortium. vitamin C and vitamin E in pregnant women at risk for pre-eclampsia (VIP trial): randomised placebo-controlled trial. *Lancet.,367*(9517):1145-54.

24- Rolnik, D.L., Wright, D., Poon, L.C., O'Gorman, N., Syngelaki, A., de Paco Matallana, C., Akolekar, R., Cicero, S., Janga, D., Singh, M., Molina, F.S., Persico, N., Jani, J.C., Plasencia, W., Papaioannou, G., Tenenbaum-Gavish, K., Meiri, H., Gizurarson, S., Maclagan, K., & Nicolaides, K.H. (2017) Aspirin versus placebo in pregnancies at high risk for preterm preeclampsia. *N Engl J Med. 17*;377(7):613-622

25- Sass, N., Itamoto, C.H., Silva, M.P., Torloni, M.R., & Atallah, A.N. (2007) Does sodium nitroprusside kill babies? A systematic review. *Sao Paulo Med J.* ;*125*(2):108-11.

26-Sibai, B.M. (2005) Diagnosis, prevention, and management of eclampsia. *Obstet Gynecol.,105*(2):402-10.,

27-Tranquilli, A.L., Dekker, G., & Magee, L., et al.(2014) The classification, diagnosis and management of the hypertensive disorders of pregnancy: A revised statement from the ISSHP. *Pregnancy Hypertens* ; 4:97.

28-Umesawa, M., & Kobashi,G.(2017) Epidemiology of hypertensive disorders in pregnancy:Prevalence, risk factors, predictors and prognosis. *Hypertens Res. ,40*(3):213-220

29-Visintin, C., Mugglestone, M.A., & Almerie, M.Q., et al.(2010) Management of hypertensive disorders during pregnancy: summary of NICE guidance. *BMJ* , 341:c2207.

30-Von Dadelszen, P., Magee, L.A.,& Roberts, J.M.(2003) Subclassification of preeclampsia. *Hypertens Pregnancy,22*(2):143-8.

31-Webster, L.M., Conti-Ramsden, & F., Seed, P.T., et al. (2017) Impact of antihypertensive treatment on maternal and perinatal outcomes in pregnancy complicated by chronic hypertension: A systematic review and meta-analysis. *J Am Heart Assoc* ; 6.

32-Welch, R., Thornton, J.G., & Moutquin, J.M (2016) CHIPS Study Group*. The CHIPS randomized controlled trial (control of hypertension in pregnancy study): Is severe hypertension just an elevated blood pressure? *Hypertension* , *68*(5):1153-1159

ISBN: 978-625-8007-01-5