NEW HORIZONS IN THE HEALTH SCIENCES

EDITOR: Hülya ÇİÇEK

AUTHORS

Abdullah Izzeddin KARABULUT
Ali Berkan URAL
Ayse Sebnem ERENLER
Baki TÜRKOĞLU
Benan YAZICI KARABULUT
Burak ÜN
Büşra ÇETİNKAYA ÜN
Büşra MUSLU DINÇ
Çiğdem KARAKAYALI AY
Ibrahim BAYHAN
İrem BİGAT
Kübra AYDIN BAHAT
Mehmet Irfan YESILNACAR
Nurten ÖZÇALKAP
Enes Mustafa AŞAR
Pınar CELEPLİ
Salih CELEPLİ
Suleyman Hilmi AKSOY
Tuba UNVER
Uğur ERAY
Zümrüt BAHAT

İKSAD
Publishing House

NEW HORIZONS IN THE HEALTH SCIENCES

EDITOR: Hülya ÇİÇEK

AUTHORS

Abdullah Izzeddin KARABULUT
Ali Berkan URAL
Ayse Sebnem ERENLER
Baki TÜRKOĞLU
Benan YAZICI KARABULUT
Burak ÜN
Büşra ÇETİNKAYA ÜN
Büşra MUSLU DINÇ
Çiğdem KARAKAYALI AY
Ibrahim BAYHAN
İrem BİGAT
Kübra AYDIN BAHAT
Mehmet Irfan YESILNACAR
Nurten ÖZÇALKAP
Enes Mustafa AŞAR
Pınar CELEPLİ
Salih CELEPLİ
Suleyman Hilmi AKSOY
Tuba UNVER
Uğur ERAY
Zümrüt BAHAT

İKSAD
Publishing House

(The Licence Number of Publicator: 2014/31220)
TURKEY TR: +90 342 606 06 75
USA: +1 631 685 0 853
E mail: iksadyayinevi@gmail.com
www.iksadyayinevi.com

ISBN: 978-625-8405-09-5
Cover Design: İbrahim KAYA
February / 2022
Ankara / Turkey
Size = 16x24 cm

CONTENTS

PREFACE

Dear health workers and all our readers who care about health,

We have published this book thanks to our dear friends who walk a long road called science. When starting a job, it should be remembered that it is extremely important to maintain it. For this reason, our high-level stakeholders bear great responsibilities in scientific platforms. Their guidance to the scientists who came after them should be an inspiration for them to take their scientific activities further. Knowledge and fondness grow when shared. In addition to being in a very busy work pace in our age, the COVID-19 pandemic, which has affected the world for the last few years, has made our living conditions difficult. In addition, this situation increased the importance of the concept of health even more. We reminded once again of the importance of not only healthcare professionals but also all individuals making efforts to solve their health problems. For this reason, it has become mandatory for all scientists outside the field of health to work with us and produce multidisciplinary solutions. In the age of technology we live in, distances have become closer, sharing has increased, and our chance of integrating each branch of science with others became easier.

I would like to thank the scientists who work not only for themselves but for all humanity, and to our team of authors who supported our book, with the hope of opening new horizons together in health science.

Prof. Dr. Hülya ÇİÇEK[1]

[1] Department of Medical Biochemistry/Gaziantep University School of Medicine..

CHAPTER 1

APPROACH TO PROTEINURIA

Kübra AYDIN BAHAT[1]

[1] Spec. Dr., Istanbul Kartal Dr. Lütfi Kırdar City Hospital, Nephrology BD, İstanbul, Turkey. asbkubra@gmail.com, ORCID ID :0000-0002-2620-9991

INTRODUCTION

Total urinary protein excretion should be less than 150 mg/day (usually 40 to 80 mg) in normal adult physiological conditions. Daily albumin loss in urine is less than 20 mg (15 mcg/min). Persistent albumin excretion of 30 to 300 mg/day (20 to 200 mcg/min) in the urine is called moderately increased albuminuria (microalbuminuria). Albumin excretion greater than 300 mg/day (200 mcg/min) daily in the urine is considered overt proteinuria or severely increased albuminuria (macroalbuminuria), the level at which the standard dipstick becomes positive. At this level, most of the protein in the urine consists of albumin (1).

The amount of proteinuria is one of the important factors that play a role in the preservation of kidney functions. Therefore, it is important to know the amount of proteinuria in the follow-up and treatment of proteinuria.

1. METHODS OF DETECTION OF PROTEINURIA

1.1. Semiquantitative methods:

They are the preferred methods because they are easy to apply and give fast results.

1.1.1 Standard urine dipstick stick

The standard urine dipstick primarily detects albumin, relatively insensitive to non-albumin proteins. Therefore, a positive dipstick usually reflects glomerular proteinuria. The lower limit of detection is a urinary albumin concentration of about 10 to 20 mg/dL. Therefore, patients with moderately increased albuminuria (microalbuminuria) will usually not be identified by this method unless the urine is very concentrated.

Urinalysis performed in the first 24 hours after the use of iodinated contrast material, high alkaline urine (pH greater than 8), presence of gross hematuria, and some antiseptics (chlorhexidine, benzalkonium, etc.) used before the urine sample is given may cause false positives (2-6).

1.1.2 Precipitation of urine proteins with sulfosalicylic acid (SSA)

The SSA test usually shows the presence of non-albumin proteins, mostly immunoglobulin light chains, in the urine. SSA detects all proteins in the urine with a sensitivity of 5 to 10 mg/dL (7). It provides the detection of significant protein excretion in patients who have not detected proteinuria with a standard urine dipstick. When proteinuria is detected in the SSA test, it requires attention especially for the detection of multiple myeloma and other monoclonal gammopathies.

In the SSA test, proteinuria amounts are determined according to the following scheme (7):

- Trace proteinuria = 1- 10 mg/dL
- 1+ = 15- 30 mg/dL
- 2+ = 40- 100 mg/dL
- 3+ = 150- 350 mg/dL
- 4+ = >500 mg/dL.

False positive results may occur if the urine sample taken for the SSA test is given in the first 24 hours after the use of iodinated radiocontrast agents, if penicillin group antibiotics are used, sulfisoxazole is used, and if gross hematuria is present (2-5).

1.2 Quantitative measurements

Determining the degree of protein excretion is a central part of the assessment of patients with acute and chronic kidney disease and patients who are incidentally identified as having persistent proteinuria by a semi-quantitative method. The amount of protein excretion is very important in determining renal progression.

1.2.1 Measurement of protein in 24-hour urine

Patients with persistent proteinuria should undergo a quantitative measurement of total protein excretion. It is the gold standard test for the measurement of protein excretion. However, it is troublesome for patients and is often collected incorrectly. (Over- and under-collection are common).

1.2.2 Ratio of spot urine protein to creatinine or spot urine albumin to creatinine:

They are the preferred tests because they are more practical and applicable than the 24-hour urine test. The urine protein-creatinine ratio in the first or second urine sample in the morning, often after exercise is avoided, can be used to predict 24-hour proteinuria in patients with protein uric kidney disease and to monitor the effects of treatment. However, the variation of urinary protein excretion throughout the day causes controversy over its correct estimation of urinary excretion (8).

2. TYPES OF PROTEINURIA

There are four main types of proteinuria (7):

- Glomerular proteinuria
- Tubular proteinuria
- Overflow proteinuria
- Post-renal proteinuria

2.1 Glomerular proteinuria

Glomerular proteinuria results from increased filtration of macromolecules (such as albumin) through the glomerular capillary wall. This is a sensitive marker for the presence of glomerular disease. Diabetic nephropathy, glomerular diseases, orthostatic or exercise-induced proteinuria fall into this category.

2.2 Tubular proteinuria

Proximal tubular reabsorption is impaired by various tubulointerstitial diseases or even by some primary glomerular diseases. The tubular damage that occurs can lead to increased excretion of low molecular weight proteins (<25,000 Daltons), such as beta2-microglobulin, immunoglobulin light chains, retinol-binding protein, and polypeptides derived from the degradation of albumin (9- 11). The increased excretion of immunoglobulin light chains (or Bence Jones proteins) in tubular proteinuria is mild, polyclonal (both kappa and lambda) and does not damage the kidney.

2.3 Overflow proteinuria

It occurs when marked overproduction of a particular protein exceeds the resorption capacity of the proximal tubule. This is almost always due to immunoglobulin light chains in multiple myeloma, but can also be caused by non-haptoglobin-bound lysozyme (in acute myelomonocytic leukemia), myoglobin (in rhabdomyolysis), or free hemoglobin (in intravascular hemolysis) (12). It should be considered in cases where there is proteinuria with other methods and proteinuria cannot be detected with urine dipstick cavity.

2.4 Postrenal proteinuria (Tissue proteinuria)

Structural disorders occur as a result of urinary tract tumors, kidney stone disease or inflammatory urinary system disorders. This condition, which usually occurs with urinary tract infection, may cause an increase in urinary protein excretion, although the mechanism is not clear. The excreted proteins are usually not albumin (often IgA or IgG) and only small amounts are excreted. Leukocyturia is often found in such patients.

3. OTHER DEFINITIONS OF PROTEINURIA

3.1. Transient proteinuria

It is especially common in young individuals. It has been reported in 8 to 12 percent of individuals younger than 18 years and in about 4 percent of college-aged adults [52-54]. It may occur with fever and exercise and symptomatic urinary tract infection (9,13-15). Proteinuria is usually less than 1 g/day in these patients. If repeated qualitative test is not positive for proteinuria, transient proteinuria is diagnosed. These patients do not need further evaluation.

3.2 Orthostatic proteinuria

Orthostatic proteinuria is a relatively common finding in adolescents (occurring in 2 to 5 percent) but an uncommon disorder in adults over 30 years of age (13,16,17). It is characterized by increased protein excretion in the upright position but normal protein excretion when the patient lies supine. The mechanism by which orthostatic proteinuria occurs is unclear. Total protein excretion is usually less than 1 g/day in orthostatic proteinuria, but

may exceed 3.5 g/day in selected patients (16,18). It is a benign condition that does not require specific treatment (18). However, renal function and proteinuria should be monitored annually to monitor for any evidence of progression.

3.3 Isolated proteinuria

It is defined as the absence of abnormalities (hematuria, lipid urea, casts, etc.) in the urinary sediment together with preserved glomerular filtration rate in patients without hypertension and diabetes. In most cases of isolated proteinuria, the patient is asymptomatic. Proteinuria is detected incidentally during routine check-ups. Benign causes of isolated proteinuria usually progress with proteinuria less than 1-2 g/day. If proteinuria is persistent during follow-up, it is called persistent isolated proteinuria.

Persistent isolated proteinuria can usually occur with an underlying cause such as diabetes mellitus, malignancy, systemic autoimmune disease, or previous history of kidney disease. Therefore, if persistent isolated proteinuria is considered, comprehensive evaluation is required to determine the etiology of proteinuria.

Most patients with persistent proteinuria should have the following tests:

- Amount of urinary protein excretion with a quantitative measurement
- Measurement of serum creatinine (with estimation of GFR).
- A urine protein immunoelectrophoresis to assess the excretion of monoclonal light chains
- A kidney ultrasound examination to exclude structural causes (e.g., reflux nephropathy, polycystic kidney disease).
- Antinuclear antibody (ANA), antineutrophil cytoplasmic antibody (ANCA), complement component C3 and C4 levels and hepatitis serologies.

4. APPROACH TO PROTEINURIA PATIENTS

It is very important to pay attention to the urinary sediment in a patient with proteinuria, if no features are detected in the detailed history and physical examination. Transient proteinuria and orthostatic proteinuria should be evaluated in patients with isolated proteinuria without any feature in the urinary sediment. These two conditions are usually benign and require follow-up. Significant increases in the amount of proteinuria in the future require detailed examination. In addition, in the presence of leukocyturia with hematuria in the complete urine analysis, it is important to investigate the patient for urinary system infection and to evaluate the urinary sediment after treatment if urinary system infection is considered. The amount of proteinuria detected by quantitative methods can give an idea about the etiology of kidney disease (Table 1).

Table 1: Possible Causes of Kidney Disease by Amount of Proteinuria (19)

Mild proteinuria (<500 mg/day)	Obstructive nephropathy, tubular diseases, kidney tumors, stone disease, prerenal azotemia, polycystic kidney disease, hypokalemic nephropathy, hypercalcemic nephropathy
Moderate proteinuria (500-3000 mg/day)	Urinary tract infection, benign nephrosclerosis, vesicourethral reflux, pyelonephritis, interstitial nephritis, acute tubular necrosis, hepatorenal syndrome, transplant rejection, postural proteinuria, lupus nephritis, primary glomerular diseases, diabetic nephropathy
Severe proteinuria (>3000 mg/day)	Acute glomerulonephritis, multiple myeloma, amyloidosis, preeclampsia, lupus nephritis, drug toxicity, diabetic nephropathy, malignant nephrosclerosis, renal vein thrombosis, primary glomerular diseases

Renal biopsy should generally be performed in all patients with proteinuria greater than 3.5 g/day or in cases with proteinuria <3.5 g with active urinary sediment or with decreased glomerular filtration rate. However,

biopsy is not recommended in some patients who are very likely to have nephrotic proteinuria (>3.5 g/day) due to diabetic nephropathy.

In patients with isolated proteinuria, if the degree of proteinuria increases at follow-up and persists above 1 g/day, or if the patient develops new glomerular hematuria, hypertension, or a decrease in glomerular filtration rate, a kidney biopsy is usually performed. In addition, in patients with isolated proteinuria, a kidney biopsy may be helpful to diagnose a suspected systemic process if the diagnosis cannot be made reliably in any other way (20).

Depending on the underlying cause, specific treatments are applied to patients diagnosed with kidney biopsy. Blood pressure control is important in patients with proteinuria, although biopsy is not considered appropriate. In this patient group, angiotensin converting enzyme inhibitors and angiotensin receptor blockers are the first choice, which are known to reduce renal protein excretion (21).

CONCLUCSION

Whatever the cause, the presence of proteinuria is closely related to the lifespan of the kidney. Therefore, it is clinically very important to carry out detailed clinical examinations in patients with proteinuria.

REFERENCES

Dickson, L. E., Wagner, M. C., Sandoval, R. M., & Molitoris, B. A. (2014). The proximal tubule and albuminuria: Really! *Journal of the American Society of Nephrology*, *25*(3), 443–453. https://doi.org/10.1681/asn.2013090950

Morcos, S. K., el-Nahas, A. M., Brown, P., & Haylor, J. (1992). Effect of iodinated water soluble contrast media on urinary protein assays. *BMJ*, *305*(6844), 29. https://doi.org/10.1136/bmj.305.6844.29-a

Carroll, M. F., & Temte, J. L. (2000). Proteinuria in adults: a diagnostic approach. *American Family Physician*, *62(6)*(1333–40).

Simerville JA, Maxted WC., & Pahira, JJ. (2005). Urinalysis: a comprehensive review. *American Family Physician*, *71(6)*(1353–62).

Tapp, D. C., & Copley, J. B. (1988). Effect of Red Blood Cell Lysis on Protein Quantitation in Hematuric States. *American Journal of Nephrology*, *8*(3), 190–193. https://doi.org/10.1159/000167581

Rudensky, B. (1981). False-Positive Test for Protein Using Dipsticks: Contamination With Chlorhexidine Antiseptic. *JAMA: The Journal of the American Medical Association*, *246*(10), 1089. https://doi.org/10.1001/jama.1981.03320100025016

Pathophysiology of renal disease. (1987). McGraw Hill.

Naresh, C. N., Hayen, A., Craig, J. C., & Chadban, S. J. (2012). Day-to-Day Variability in Spot Urine Protein-Creatinine Ratio Measurements. *American Journal of Kidney Diseases*, *60*(4), 561–566. https://doi.org/10.1053/j.ajkd.2012.04.010

Carter, J. L., Tomson, C. R. V., Stevens, P. E., & Lamb, E. J. (2006). Does urinary tract infection cause proteinuria or microalbuminuria? A systematic review. *Nephrology Dialysis Transplantation*, *21*(11), 3031–3037. https://doi.org/10.1093/ndt/gfl373

Portman, R. J., Kissane, J. M., Robson, A. M., Peterson, W. T. T. A. O. L. J., & Richardson, A. (1986). Use of β2 microglobulin to diagnose tubulo-interstitial renal lesions in children. *Kidney International*, *30*(1), 91–98. https://doi.org/10.1038/ki.1986.156

Sesso, R. (1992). Prediction of Steroid Responsiveness in the Idiopathic Nephrotic Syndrome Using Urinary Retinol-binding Protein and Beta-2-Microglobulin. *Annals of Internal Medicine*, *116*(11), 905. https://doi.org/10.7326/0003-4819-116-11-905

Barratt, J., & Topham, P. (2007). Urine proteomics: the present and future of measuring urinary protein components in disease. *Canadian Medical Association Journal*, *177*(4), 361–368. https://doi.org/10.1503/cmaj.061590

Robinson, R. R. (1980). Isolated proteinuria in asymptomatic patients. *Kidney International*, *18*(3), 395–406. https://doi.org/10.1038/ki.1980.151

Poortmans, J. R. (1985). Postexercise Proteinuria in Humans. *JAMA*, *253*(2), 236. https://doi.org/10.1001/jama.1985.03350260088032

Poortmans, J. R., Brauman, H., Staroukine, M., Verniory, A., Decaestecker, C., & Leclercq, R. (1988). Indirect evidence of glomerular/tubular mixed-type postexercise proteinuria in healthy humans. *American Journal of Physiology-Renal Physiology*, *254*(2), F277–F283. https://doi.org/10.1152/ajprenal.1988.254.2.f277

SPRINGBERG, P. D. (1982). Fixed and Reproducible Orthostatic Proteinuria: Results of a 20-Year Follow-up Study. *Annals of Internal Medicine*, *97*(4), 516. https://doi.org/10.7326/0003-4819-97-4-516

Sebestyen, J. F., & Alon, U. S. (2010). The Teenager With Asymptomatic Proteinuria: Think Orthostatic First. *Clinical Pediatrics*, *50*(3), 179–182. https://doi.org/10.1177/0009922810380904

Rytand, D. A., & Spreiter, S. (1981). Prognosis in Postural (Orthostatic) Proteinuria. *New England Journal of Medicine*, *305*(11), 618–621. https://doi.org/10.1056/nejm198109103051105

Akpolat, T., Utaş C., & Süleymanlar G. (2007). *Nefroloji El Kitabi*. ISTANBUL, Türkiye: Akademisyen Kitabevi.

Fuiano, G., Mazza, G., Comi, N., Caglioti, A., de Nicola, L., Iodice, C., . . . Andreucci, V. E. (2000). Current indications for renal biopsy: A questionnaire-based survey. *American Journal of Kidney Diseases*, *35*(3), 448–457. https://doi.org/10.1016/s0272-6386(00)70197-1

Vehaskari, V. M., & Rapola, J. (1982). Isolated proteinuria: Analysis of a school-age population. *The Journal of Pediatrics*, *101*(5), 661–668. https://doi.org/10.1016/s0022-3476(82)80287-4

CHAPTER 2

CLINICAL AND COST EFFECTIVENESS OF SURGERY, FOAM SCLEROTHERAPY AND LASER ABLATION IN THE TREATMENT OF VARICOSE VEINS

Suleyman Hilmi AKSOY[1]

[1]Asst Prof .,Hisar Intercontinental Hospital, Department of Radiology, Istanbul, Turkey, mdshilmiaksoy@gmail.com .ORCID ID : 0000-0002-2356-0268

INTRODUCTION

Varicose veins is among the types of venous insufficiency with enşarged and tortuous superficial veins. The treatment and complications of varicose veins bring a significant burden on healthcare systems. These conditions may impair patients' health-related quality of life. Although varicose veins usually cause few symptoms, treatment should be initiated if the patient is complaining of symptoms such as, venous ulcers, external bleeding, itching, swelling, skin changes, ulceration and pain. Today, there are several conservative and surgical methods utilized to treat varicose veins. Although among these treatment options ultrasound-guided foam sclerotherapy (UGFS) and endovenous laser ablation (EVLA) have become more popular, surgical treatment remains a valuable technique when performed appropriately. This chapter focuses on the clinical effectiveness and cost-effectiveness of foam sclerotherapy, endovenous laser ablation and in line with the current literature.

1. VARICOSE VEINS

According to one of the most accepted definitions, varicose veins are "any elongated, dilated or tortuous veins of any size" (Ghosh et al., 2021) (Figure 1). Varicose vein is "a vein, which has lost its valvular efficiency, permanently" (Ghosh et al. 2021). Approximately 25% of the general population suffer from varicose veins (Biemans et al. 2013). Visible varicose veins affect 40% of male and 32% of female patients (Ghosh et al., 2021).

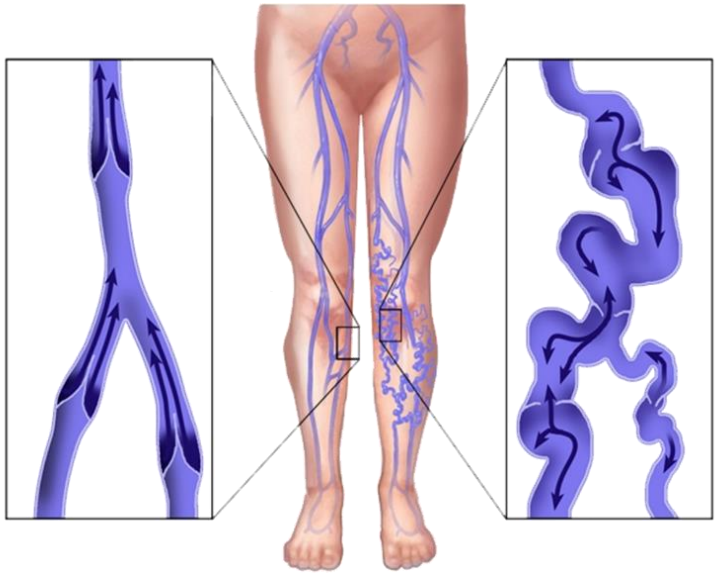

Figure 1. Healthy (left) and varicose (right) veins

The treatment of complications related to varicose veins, including eczema, ulceration, acute bleeding from one of the small varices and superficial thrombophlebitis cause a significant economic burden and workload to healthcare systems by consuming limited health resources, especially during the ongoing pandemic.

Several intrinsic and extrinsic factors are reported as the factors predisposing to develop varicose veins, including age, gender, weight, height, race, pregnancy, genetics, previous DVT and climate (Janugade et al. 2017).

Symptoms of varicose veins can be discomforting and painful, leading to an increase in the risk of developing ulcer in severe cases (Onida, Lane & Davies, 2013). The most common clinical symptoms of varicose veins include bleeding, visible veins, itching, aching, pain, itching, skin changes, swelling, and ulceration. When the patient with this condition is complaining of heaviness in legs, ankle hyperpigmentation, superficial thrombophlebitis, bleeding and venous leg ulcers, treatment should be considered and initiated.

Current options for the treatment of varicose veins can significantly improve QoL. Although there are numerous methods in the market used for treatment, the well-established methods include conservative cares such as compression stockings, high-ligation surgery, radiofrequency ablation (RFA),

endovenous laser ablation (EVLA), ultrasound-guided foam sclerotherapy (UGFS) and high-ligation surgery (HL/S) (Epstein et al., 2018). In addition, there are other newer options such as mechanochemical ablation (MOCA) and cyanoacrylate glue occlusion (CAE) (Almeida et ak., 2013). Among these therapeutic options, foam sclerotherapy and EVLA and UGFS are involved in the modern treatment of varicose veins. Yet surgical methods also remain valuable if performed appropriately by skilled hands (Kabnick & Sadeck, 2014). On the other hand, a surge of research on clinical and cost-effectiveness of these methods is ongoing.

2. ULTRASOUND-GUIDED FOAM SCLEROTHERAPY (UGFS)

Today, (UGFS) is one of the frequently used treatment methods for the management of varicose veins, including truncal veins, perforating veins and saphenous junctions. In a survey conducted among the members of the Vascular Society of Great Britain and Ireland, it was reported that UGFS was performed by 27% of surgeons (Winterborn and Corbett, 2008). Foam sclerotherapy was introduced for the first time by Orbach in 1950 to treat varicose veins (Orbach and Petretti, 1950). This procedure became popular when Tessari reported a method in which the foam was prepared using a three-way stopcock and two disposable syringes (Tessari, 2001). Ultrasound guidance has revolutionized the method. Ultrasound-guided foam sclerotherapy has been used with very low complication rates and success rate as high as 90% (Myers et al. 2007).

2.1. Technique

Although there are various alterations in the technical methods used for UGFS, usually the great saphenous vein (GSV) or small saphenous vein (SSV) under ultrasound guidance. The leg is elevated and advancement of the foam through the vein is monitored using ultrasound imaging. The foam is mostly prepared using the method described by Tessari by mixing one part sclerosant and sodium tetradecyl sulphate (STS) 0.5 - 3% with four air using two-disposable syringes and a three-way stopcock (Tessari, 2000). The foam is used in varying concentrations depending on thesize of the target vein. The foam is milked along target vein using surface pressure. In a survey study

conducted among foam surgeons, 63% of the participants stated that they routinely blocked the saphenopopliteal and saphenofemoral junction during injection (O'Hare & Earnshaw, 2007). The most commonly used technique was first to treat the main incomponent main and then any remaining smaller varicose veins with a separate session. After the foam sclerotherapy, either compression bandaging or graduated compression is used to promote healing. Patients are usually advised to wear compression stockings for 7 to 14 days after the treatment.

2.2. Clinical results

Complete occlusion of the target vein is considred a successful outcome in the management of varicose veins and this is confirmed with Color Doppler Ultrasonography at follow-up controls. Darke et al., evaluated efficacy and complications of UGFS were evaluated in 197 truncal veins. At the end of the controls, complete occlusion of the varicose veins occurred in 163 legs after the 1st treatment, 33 legs after the 2nd treatment and one leg after the 3rd treatment (Darke & Baker, 2006). In another study by Smith et al., obliteration was achieved in 82% of the SSVs and 88% of the GSVs at the end of the 6-month follow-up (Smith, 2006). On the other hand, technical failure with UGFS was reported as 16.3% (Rasmussen et al. 2011). In another study with a longer follow-up period investigating the efficacy of UGFS in 391 limbs of 285 patients, after 5 to 8-year follow-up, disease specific QoL was significantly improved in 82% of the patients and 91% stated that they would recommend this therapy to their family. The need for re-treatment due to recurrence was reported as 15.3% by 5 years (Darvall, Bate and Bradbury, 2014).

In a systematic review of 1023 studies including 10819 patients, venous thromboembolism was found in 11 (1.07%) patients, migraines in 8 (0.78%) patients and visual impairment in 7 (0.68%) patients (Belramman et al., 2018). In addition, other complications such as skin discoloration, tissue necrosis and telangiectasia matting have also been reported (Gosh, 2021).

3. ENDOVENOUS LASER ABLATION (EVLA)

EVLA is among the endovenous thermal ablation techniques that have replaced conventional surgical techniques in many countries (Proebstle et al. 2015). The use of EVLA procedure for treatment of varicose veins was approved by the FDA in 2000 for the first time (Gibson, Ferris & Pepper, 2007). On the other hand, EVLA is not a standardized method anc can be used with many modifications in numerous settings. With the results of long-term follow-up studies, there has been increased variations in the devices and settings used to perform the EVLA procedure (Malksat et al., 2019). The working mechanism of EVLA is not fully understood, although it is known that heat produced by the laser fiber is transferred to the surrounding tissue via various mechanisms such as heat conduction, direct contact and steam bubbles (Malskat et al. 2014). The primary mechanism of action is provocation of thermal reaction, and this can be altered with setting various parameters including type of energy and wavelength, (de Araujo et al., 2017).

3.1. Technique

The goal of EVLA treatment is the destruction of the incompetent vein through laser ablation. GSV is cannulated at the lower part of the insufficiency. During the procedure, the leg is flexed and rotated in the direction of the hip. The knee is then slightly flexed. In the next step, a guidewire was entered and a 5 Fr catheter is advanced over the wire. Position of the catheter tip should be 0.5 cm to 1cm distal to the junction. A laser fiber is then placed and the tip is withdrawn about 2 cm to enable laser fiber protrusion beyond the catheter (Venermo et al., 2016). In the Trendelenburg position, cold saline tumescent is infiltrated along the trunk vein to provide anesthesia and prevent heat absorption. The laser fibre is set at 12-watt power to deliver a 70 joules/cm vein, and then fired continuously. Laser fiber can be used at different wavelengths with varying results, but studies on this issue lack in the literature. EVLA is usually performed under tumescent local anesthesia. The patient receives a light sedative before and during the EVLA procedure. Post-treatment compression is recommended at least for 10 days (Brittenden et al., 2019).

3.2. Clinical results

In the first clinical study by Navarro et al. on EVLA procedure, 44 GSVs were treated with EVLA and at the end of a mean 4.2 months follow-up, 100% of GSVs were occluded without major complications (Navarro, Min and Bone, 2001). Venermo et al. reported 71 patients undergoing EVLA due to GSV varicose veins, the GSV was occluded or absent in 97% of the patients after 1 year (Venermo et al., 2016). EVLA of the GVS with wavelengths >810 nm causes thrombotic occlusion od the vein and is related a reduction in reduced postoperative pain Belramman et al., 2018). In a study by Min et al., EVLA was performed on 499 limbs with varicose veins were followed-up to 17 months. Occlusion rates were found as 97% at in 1 month, 97% in one year and 93.4% in 2 years. Twenty-four percent of the patients developed bruising and 5% thrombophlebitis (Min & Khilnani, 2003). In a study by Brittenden et al. with , QoL significantly improved in patients undergoing EVLA, at the 5-year follow-up period (Brittenden et al., 2019). In a study by Biemans et al. (2013) on 76 patients undergoing EVLA, the anatomic success rate, namely occlusion was found as 88.5% of the patients at at the end of 1-year follow-up without developing a clinically significant complication.

4. SURGERY FOR VARİCOSE VEİNS

The mainstay of treatment for varicose veins is surgery with saphenofemoral junction (SFJ) ligation, strippting and phlebectomies of non-trunk varicosities (Brittenden et al., 2014). This method traditionally includes ligation and division of the SFJ and its tributaries in the groin, and stripping the GSV from groin to the knee level. On the other hand, for the treatment of varicosity in smaller veins such as the small saphenous vein these veins are ligated and divided rather than stripped, because stripping small saphenous veins may potentially damage the adjacent nerve (Lin et al. 2015). Recurrence rates with surgical treatment remain a significant problem with reported rates of 20-28% at five years following the procedure (Lynch, Clarke & Fulton, 2014).

4.1. Technique

High ligation with short stripping (HLSS) is carried out under either spinal or general anesthesia. After flush of the saphenofemoral junction (SFJ) is performed, all tributaries are ligated to the second branch of the GSV at the level of the knee. The procedure is completed by closing the cribriform fascia layer, superficial fascia layer and skin, respectively.

An ambulatory compression bandage is applied following the procedure for 48 hours and compression stockings are used at least for 2 weeks. Patients wait under observation at least for 30 minutes in the clinic before discharge.

4.2. Clinical results

In a study by Venermo et al., 61 patients with varicose veins were treated traditionally with surgery and the occlusion rate was found as 97% at 1 year. No major complication was seen, while 5% of the patients developed wound site infection (Venermo et al., 2016). Lawaetz et al., found recurrence rate as 34.6% at five years in patients undergoing surgery (Lawaetz et al., 2017). It was reported in a study by Rasmussen et al. that sick leave was relatively shorter with surgery (7.6 days), which was thought to be resulted from utilization ofin the procedures (Rasmussen et al. 2007). Osman, El-Heeny and El-Razeq reported the complication rate as 37.5% in 20 patients undergoing stripping of the GSV, with the most common complication being hematoma (12.5%) followed by ecchymosis (8.3%) (Osman, El-Heeny and El-Razeq, 2019). In another study, the most common complications following stripping of the GSV were reported as mild inflammation, serous wound discharge, hematoma and wound breaking, all of which resolved spontaneously (Subramonia and Lees, 2010).

5. SURGERY, UGFS AND EVLA PROCEDURES: CLİNİCAL EFFECTİVENESS

A number of factors affect success of the different treatment method utilized. All these methods have their own advantages and disadvantages, and so far there is no standardized and widely adopted method for this purpose. The commonly used factors to determine treatment success are given in Figure 2.

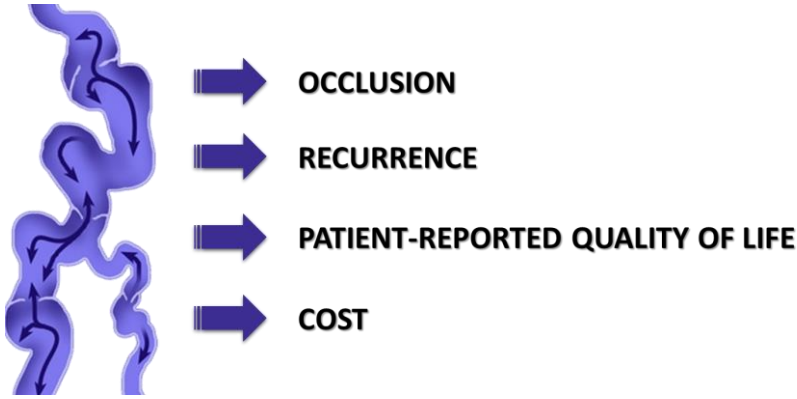

Figure 2. Commonly measured factors to determine success in the treatment of varicose veins.

Clinical effectiveness of UGFS, EVLA and Surgery have been investigated and compared in numerous studies. In a meta-analysis of 13 studies with a mean follow-up duration ≥ 5 years, anatomical success rate was significantly lower with UGFS (%34) compared to surgery (87%) and EVLA (88%) procedures (Hamann et al., 2017). In the same analysis, pooled recurrence rate was found as 12% with surgery, 22% with EVLA and 29% with UGFS procedures (Hamann et al., 2017). In a recent study by Brittenden et al., higher success was obtained in treatment with surgery and ELVA compared with UGFS (Brittenden et al., 2019). Biemans et al. reported no significant difference between the UGFS and surgery methods in terms of clinician noted recurrence (Biemans et al. 2013). Similarly, Rasmussen et al. found similar recurrence rates (14.8% vs 13.8%) for surgery and UGFS procedures (Rasmussen 2011).

In a study by Brittenden et al., QoL (measured by AVVQ scores) was higher in the patients undergoing EVLA compared to surgery and UGFS ($p<0.001$). In that study, pain (measured by VAS score) was found as 2.6 with laser ablation, 3.2 with foam sclerotherapy, and 2.4 with surgery. In addition, 5-year rates of complete success were found as 64.0% with EVLA, 33.3% with UGFS, and 75.9% with surgery (Brittenden et al., 2019). In another study by van der Velden et al., disease specific QoL was higher in patients who underwent EVLA compared to those who underwent UGFS for the

treatment of varicose veins. However, no significant difference was found between the patients undergoing UGFS and surgery (van der Velden et al., 2015).

6. SURGERY, UGFS AND EVLA PROCEDURES: COST EFFECTIVENESS

Quality-adjusted life-years (QALY) is an important factor used in the analysis of cost-effectiveness with a certain treatment method, taking in account long term (e.g. 5 years) effects. QALY takes into account both quantity and quality of life generated by healthcare interventions (Wichman et al. 2020). Tassie et al. compared cost-effectiveness of UGFS, EVLA and Surgery by examining 5-year outcomes, and reported that EVLA was the potentially preferred option in terms of cost-effectiveness with £3640 per QALY gained. The authors of this study stated that cost savings related to EVLA procedure increased to £368 using the same staff and further increased when patients with good results following the initial EVLA were not followed up at for 6 weeks (Tassie et al. 2014). In a Markov model developed by Gohel et al., EVLA performed under local anesthesia was found to be the most cost-effective method with £20,000 per QALY (Gohel, Epstein & Davies, 2010).

It is difficult to make a healthy comparison among studies due to several variable factors such as the surgical staff, operational setting, anesthesia type, sclerosing agents used in UGFS and wavelengths used in EVLA etc. However, a general review of the published studies gave an idea about the effectiveness. In a study by Brittenden et al., the most cost-effective method was found as EVLA with a willingness-to-pay ratio of £20,000 ($28,433) per QALY compared to UGFS and surgery (Brittenden et al., 2019).

CONCLUSION

The management of varicose veins has dramatically evolved especially with advancement in endovenous techniques. EVLA and UGFS appear safe and effective alternatives to surgery. However, patients should be given clear instructions about the importance of adherence to compression following treatment. Most data in the recent literature indicate that both clinical effectiveness and cost effectiveness are better with EVLA compared to UGFS and surgery, which is evident by the fact that EVLA has replaced

surgery in numerous countries worldwide. On the other hand, follow-up studies with longer durations will continue to provide a better insight into the costs and clinical effectiveness of these three methods and other novel techniques.

REFERENCES

Almeida, J. I., Javier, J. J., Mackay, E., Bautista, C., & Proebstle, T. M. (2013). First human use of cyanoacrylate adhesive for treatment of saphenous vein incompetence. Journal of vascular surgery. Venous and lymphatic disorders, 1(2), 174–180.

Belramman, A., Bootun, R., Lane, T., & Davies, A. H. (2019). Endovenous Management of Varicose Veins. Angiology, 70(5), 388–396.

Biemans, A. A., Kockaert, M., Akkersdijk, G. P., van den Bos, R. R., de Maeseneer, M. G., Cuypers, P., Stijnen, T., Neumann, M. H., & Nijsten, T. (2013). Comparing endovenous laser ablation, foam sclerotherapy, and conventional surgery for great saphenous varicose veins. Journal of vascular surgery, 58(3), 727–34.e1.

Brittenden, J., Cotton, S. C., Elders, A., Ramsay, C. R., Norrie, J., Burr, J., Campbell, B., Bachoo, P., Chetter, I., Gough, M., Earnshaw, J., Lees, T., Scott, J., Baker, S. A., Francis, J., Tassie, E., Scotland, G., Wileman, S., & Campbell, M. K. (2014). A randomized trial comparing treatments for varicose veins. The New England journal of medicine, 371(13), 1218–1227.

Brittenden, J., Cooper, D., Dimitrova, M., Scotland, G., Cotton, S. C., Elders, A., MacLennan, G., Ramsay, C. R., Norrie, J., Burr, J. M., Campbell, B., Bachoo, P., Chetter, I., Gough, M., Earnshaw, J., Lees, T., Scott, J., Baker, S. A., Tassie, E., Francis, J., … Campbell, M. K. (2019). Five-Year Outcomes of a Randomized Trial of Treatments for Varicose Veins. The New England journal of medicine, 381(10), 912–922.

Darke, S. G., & Baker, S. J. (2006). Ultrasound-guided foam sclerotherapy for the treatment of varicose veins. The British journal of surgery, 93(8), 969–974.

Darvall, K. A., Bate, G. R., & Bradbury, A. W. (2014). Patient-reported outcomes 5-8 years after ultrasound-guided foam sclerotherapy for varicose veins. The British journal of surgery, 101(9), 1098–1104.

de Araujo, W., Erzinger, F. L., Caron, F. C., Nejm, C. S., Junior, & Timi, J. (2017). Influência da termoablação com baixa e alta densidade de energia na junção safeno-femoral, utilizando laser endovenoso 1470 nm. Jornal vascular brasileiro, 16(3), 220–226.

Epstein, D., Onida, S., Bootun, R., Ortega-Ortega, M., & Davies, A. H. (2018). Cost-Effectiveness of Current and Emerging Treatments of Varicose Veins. Value in health : the journal of the International Society for Pharmacoeconomics and Outcomes Research, 21(8), 911–920.

Ghosh, S.K., Al Mamun, A., & Majumder, A. (2021). Clinical Presentation of Varicose Veins. Indian Journal of Surgery, 1 - 8.

Gibson, K. D., Ferris, B. L., & Pepper, D. (2007). Endovenous laser treatment of varicose veins. The Surgical clinics of North America, 87(5), 1253–xii.

Gohel, M. S., Epstein, D. M., & Davies, A. H. (2010). Cost-effectiveness of traditional and endovenous treatments for varicose veins. The British journal of surgery, 97(12), 1815–1823.

Hamann, S., Giang, J., De Maeseneer, M., Nijsten, T., & van den Bos, R. R. (2017). Editor's Choice - Five Year Results of Great Saphenous Vein Treatment: A Meta-analysis. European journal of vascular and endovascular surgery : the official journal of the European Society for Vascular Surgery, 54(6), 760–770.

Janugade, H.B., Patil, B.P., Tata, N.H., Saygaonkar, H.V., Janugade, D.H., Dokania, V. (2017) Clinical profile and management of lower limb varicose veins. J Evol Med Dent Sci 6(20):1615–1622.

Kabnick, L.S., Sadek, M. (2014). Varicose veins: endovenous ablation and sclerotherapy. In: Cronenwett JL, Johnston KW (eds) Rutherford's Vascular Surgery. Eighth edition, Chapter- 58, pp 885–901. Elsevier Saunders, Philadelphia, PA, USA

Lawaetz, M., Serup, J., Lawaetz, B., Bjoern, L., Blemings, A., Eklof, B., & Rasmussen, L. (2017). Comparison of endovenous ablation techniques, foam sclerotherapy and surgical stripping for great saphenous varicose veins. Extended 5-year follow-up of a RCT. International angiology : a journal of the International Union of Angiology, 36(3), 281–288.

Lin, F., Zhang, S., Sun, Y., Ren, S., & Liu, P. (2015). The management of varicose veins. International surgery, 100(1), 185–189.

Lynch, N. P., Clarke, M., & Fulton, G. J. (2015). Surgical management of great saphenous vein varicose veins: A meta-analysis. Vascular, 23(3), 285–296.

Malskat, W. S., Poluektova, A. A., van der Geld, C. W., Neumann, H. A., Weiss, R. A., Bruijninckx, C. M., & van Gemert, M. J. (2014). Endovenous laser ablation (EVLA): a review of mechanisms, modeling outcomes, and issues for debate. Lasers in medical science, 29(2), 393–403.

Malskat, W., Engels, L. K., Hollestein, L. M., Nijsten, T., & van den Bos, R. R. (2019). Commonly Used Endovenous Laser Ablation (EVLA) Parameters Do Not Influence Efficacy: Results of a Systematic Review and Meta-Analysis. European journal of vascular and endovascular surgery : the official journal of the European Society for Vascular Surgery, 58(2), 230–242.

Min, R. J., & Khilnani, N. M. (2003). Endovenous laser treatment of saphenous vein reflux. Techniques in vascular and interventional radiology, 6(3), 125–131.

Myers, K. A., Jolley, D., Clough, A., & Kirwan, J. (2007). Outcome of ultrasound-guided sclerotherapy for varicose veins: medium-term results assessed by ultrasound surveillance. European journal of vascular and endovascular surgery : the official journal of the European Society for Vascular Surgery, 33(1), 116–121.

Navarro, L., Min, R. J., & Boné, C. (2001). Endovenous laser: a new minimally invasive method of treatment for varicose veins--preliminary observations using an 810 nm diode laser. Dermatologic surgery : official publication for American Society for Dermatologic Surgery [et al.], 27(2), 117–122.

O'Hare, J. L., & Earnshaw, J. J. (2007). The use of foam sclerotherapy for varicose veins: a survey of the members of the Vascular Society of Great Britain and Ireland. European journal of vascular and endovascular surgery : the official journal of the European Society for Vascular Surgery, 34(2), 232–235.

Onida, S., & Davies, A. H. (2013). Varicose veins: diagnosis and management. Nursing times, 109(41), 16–17.

ORBACH, E. J., & PETRETTI, A. K. (1950). The thrombogenic property of foam of a synthetic anionic detergent (sodium tetradecyl sulfate N.N.R.). Angiology, 1(3), 237–243.

Osman, O.A., El-Heeny, A.E., El-Razeq, M.A. (2019). Management of primary uncomplicated varicose veins, endovenous laser ablation with sclerotherapy versus traditional surgery: which is the best option?. Egypt J Surg, 38:319-27

Proebstle, T. M., Alm, B. J., Göckeritz, O., Wenzel, C., Noppeney, T., Lebard, C., Sessa, C., Creton, D., & Pichot, O. (2015). Five-year results from the prospective European multicentre cohort study on radiofrequency segmental thermal ablation for incompetent great saphenous veins. The British journal of surgery, 102(3), 212–218.

Rasmussen, L. H., Bjoern, L., Lawaetz, M., Blemings, A., Lawaetz, B., & Eklof, B. (2007). Randomized trial comparing endovenous laser ablation of the great saphenous vein with high ligation and stripping in patients with varicose veins: short-term results. Journal of vascular surgery, 46(2), 308–315.

Rasmussen, L. H., Lawaetz, M., Bjoern, L., Vennits, B., Blemings, A., & Eklof, B. (2011). Randomized clinical trial comparing endovenous laser ablation, radiofrequency ablation, foam sclerotherapy and surgical stripping for great saphenous varicose veins. The British journal of surgery, 98(8), 1079–1087.

Smith P. C. (2006). Chronic venous disease treated by ultrasound guided foam sclerotherapy. European journal of vascular and endovascular surgery : the official journal of the European Society for Vascular Surgery, 32(5), 577–583.

Subramonia, S., & Lees, T. (2010). Randomized clinical trial of radiofrequency ablation or conventional high ligation and stripping for great saphenous varicose veins. The British journal of surgery, 97(3), 328–336.

Tassie, E., Scotland, G., Brittenden, J., Cotton, S. C., Elders, A., Campbell, M. K., Campbell, B., Gough, M., Burr, J. M., Ramsay, C. R., & CLASS study team (2014). Cost-effectiveness of ultrasound-guided foam sclerotherapy, endovenous laser ablation or surgery as treatment for primary varicose veins from the randomized CLASS trial. The British journal of surgery, 101(12), 1532–1540.

Tessari, L. (2001). Extemporary sclerosing foam according to personal method: experimental clinical data and catheter usage. Int Angiol Suppl 1:54.

van der Velden, S. K., Biemans, A. A., De Maeseneer, M. G., Kockaert, M. A., Cuypers, P. W., Hollestein, L. M., Neumann, H. A., Nijsten, T., & van den Bos, R. R. (2015). Five-year results of a randomized clinical trial of conventional surgery, endovenous laser ablation and ultrasound-guided foam sclerotherapy in patients with great saphenous varicose veins. The British journal of surgery, 102(10), 1184–1194.

Venermo, M., Saarinen, J., Eskelinen, E., Vähäaho, S., Saarinen, E., Railo, M., Uurto, I., Salenius, J., Albäck, A., & Finnish Venous Study Collaborators (2016). Randomized clinical trial comparing surgery, endovenous laser ablation and ultrasound-guided foam sclerotherapy for the treatment of great saphenous varicose veins. The British journal of surgery, 103(11), 1438–1444.

Wichmann, A. B., Goltstein, L., Obihara, N. J., Berendsen, M. R., Van Houdenhoven, M., Morrison, R. S., Johnston, B. M., Engels, Y., & Radboud Honours Academy Think Tank (2020). QALY-time: experts' view on the use of the quality-adjusted LIFE year in COST-effectiveness analysis in palliative care. BMC health services research, 20(1), 659.

Winterborn, R. J., Campbell, W. B., Heather, B. P., & Earnshaw, J. J. (2004). The management of short saphenous varicose veins: a survey of the members of the vascular surgical society of Great Britain and Ireland. European journal of vascular and endovascular surgery : the official journal of the European Society for Vascular Surgery, 28(4), 400–403.

CHAPTER 3

INVESTIGATION OF MICROBIOLOGICAL QUALITY OF DRINKING AND USAGE WATER IN A FAST-GROWING METROPOLITAN CITY

Ibrahim BAYHAN[1], Benan YAZICI KARABULUT[2]

Mehmet Irfan YESILNACAR[3] , Abdullah Izzeddin KARABULUT[4]

[1] Dr., Provincial Health Directorate, Public Health Services Department, Environmental Health Unit, Sanliurfa, Turkey, ibayhan71@gmail.com, ORCID: 0000-0001-5516-6241

[2] Harran University, Faculty of Engineering, Department of Environmental Engineering, Sanliurfa, Turkey, benanyazici@harran.edu.tr, ORCID: 0000-0002-0140-204X

[3] Prof. Dr.,Harran University, Faculty of Engineering, Department of Environmental Engineering, Sanliurfa, Turkey, mirfan@harran.edu.tr, ORCID: 0000-0001-9724-8683

[4] Harran University, Graduate School of Natural and Applied Sciences, Remote Sensing and Geographic Information Systems, 100/2000 CoHE PhD Scholar, Sanliurfa, Turkey, ikarabulut@harran.edu.tr, ORCID: 0000-0002-9784-5549

INTRODUCTION

Water is one of the vital elements for human beings. Access to healthy drinking water is considered one of the most basic human rights. Unhealthy drinking water and the inadequate hygiene it causes lead to about 7% of diseases in the world (Toroglu, 2009; Bozkurt, 2010). Diarrhea that stems from unhealthy water is among the leading causes of morbidity and mortality in the world. About 20% of the world's population use unsafe drinking water, around 200 million people suffer from water-related diseases annually, and more than two million people die of diseases caused by polluted water (Çankaya et al., 2017). Problems in accessing clean drinking water in many developing countries have increased in recent years. The economic situation and the lack of adequate infrastructure cause a large part of the population to be adversely affected by this situation (Rochelle-Neval et al., 2015). In addition, contamination of surface waters and groundwater with raw manure and sewage remains a serious environmental problem (Park et al., 2015). The mucilage problem faced in the Marmara Sea in 2021 is a result of nutrient/uncontrolled discharges. In the areas of food, water safety and public health, the detection of pathogenic microorganisms has become a primary concern (Arya et al., 2011). Especially in drinking water, used by people for various daily and basic purposes, fecal pollution induced by the transport of pathogenic microorganisms poses an important threat. The presence of pathogenic microorganisms in the waters brings the risk of epidemics. That's why it's important to detect them.

Surface waters, including freshwater and seawater, drinking water and food sources are a habitat for many organisms. They are also used as a recreation area, as well. These environments are susceptible to microbial contamination stemming from streams, animal feces and wastewater discharges (Boehm et al., 2018). Microbial contamination of recreational waters such as rivers, lakes, streams, and beaches occur when processed or raw fecal matters are carried into waterways through some input sources. Point sources of fecal contamination, such as wastewater discharge from wastewater treatment plants or seepage from local livestock production facilities are contaminations that are relatively easier to identify, characterize and eliminate. Conversely, non-point sources of contamination, such as rainwater runoff, are more difficult to identify as contamination from sources

may be likely carried over great distances (Unno et al., 2018). Microbial contamination of water resources from fecal matter is a significant threat to public health in both industrialized and developing countries. According to the World Health Organization (WHO), 9% of the world's population do not have access to safe drinking water. For this reason, improving the quality and conditions of drinking water in accordance with health has become one of the important human requirements (Jofre et al., 2016).

Investigating the origin of fecal contamination is a crucial point in evaluating the actions necessary to address the health risks associated with it. The origin of this pollution can be traced genotypically and phenotypically and this is called microbial resource tracking. Characterizing fecal sources is necessary to control the major pollutants that cause water pollution. This leads to identifying a variety of chemical and microbial markers that help distinguish between human and non-human fecal sources (Devane et al., 2018).

Water quality needs to be carefully monitored, as anthropogenic fecal contamination of waters poses a major health and environmental threat. Various methods based on culturing, such as fecal indicators, have been used for a long time to determine the amount and presence of bacteria. However, these methods yield results slowly and the diagnostic information required to identify the source is insufficient in some cases (Jiang et al., 2018). Therefore, to investigate and prevent the transmission of waterborne pathogens, there is a need for faster testing methods in the field of microbiological water quality assessment that can be applied to monitor potential fecal inputs in waters (Bayhan et al., 2020).

In order for water sources to be hygienically reliable, it is necessary to determine whether the water is exposed to fecal contamination. The presence of a high number of bacteria in the water increases the risk of contracting enteric pathogens, especially in infants and children (Nwachuku and Gerba, 2004). Due to the water with poor hygienic quality, 1.7 million people die mainly of infectious diarrhea per year worldwide. On these deaths, 90% are in children and almost all are in developing countries (Ashbolt, 2004). The total mesophilic aerobic microorganism, known as standard plate count, is now called heterotrophic plate count (HPC). It is determined by counting after culturing aerobic and facultative anaerobic live bacteria to measure changes

during processing and distribution of water. Heterotrophic bacteria include some bacteria considered primary and secondary pathogens, as well as indicator bacteria such as coliform (Allen et al., 2004). The allowed limits for the number of HPC bacteria in the quality characteristics of drinking water are between 100-500 Cfu/ml in the world (Pavlov et al., 2004). Pepper et al. (2004) report that the number of HPC bacteria increases significantly from the distribution system to the consumer's tap. They also claim that bacteria originate from bacteria inside household faucets or household distribution systems rather than central distribution systems or water sources. Therefore, they conclude that consumers regularly receive more than 500 units/ml of HPC bacteria as a result of using household taps as drinking water.

Sanitary and quality water is one of the indispensable pre-requisites of food safety, nutrition, and public health. For this reason, the importance of water for human health, which does not contain pathogenic microorganisms, chemical and physical contaminants, and contains a balanced mineral distribution in terms of nutrition, has been proven by many researches. The most important feature of water suitable for health is its microbial quality. Due to the use of unsanitary water, 30.000–40.000 people die of cholera in the world every year. Likewise, 25.000 people die of typhoid and paratyphoid, 4 million of diarrheal diseases (especially children aged between 0–4), 25.000 of poliomyelitis, 20.000 of ascariasis, 200.000 of schistosomiasis, 1–2 million of malaria, and 20.000-50.000 of onchocerciasis (WHO, 2014). The microorganisms that are most common in drinking and usage water and pose a health problem are coliforms, the intestinal flora bacteria. Microbial analysis of water is also based on investigating the presence of coliform bacteria in water (Rompré et al., 2002). Fecal coliform bacteria and *E. coli* are considered as indicators of fecal contamination in water. Particularly, the pathogenic types of *E. coli* cause deadly diarrhea, nephropathy, meningitis, septicemia, arteriosclerosis, Hemolytic Uremic Syndrome (HUS), wound infections and various immunological diseases in humans and animals. Therefore, water containing total or fecal coliform bacteria should not be consumed by human without purification (Bayhan, 2021).

In this study, it is aimed to reveal the effects of environmental pressure on the changes in drinking and usage water quality. To do so, first, the conditions of the source, storage and network of drinking water and the

water supply methods in thirteen districts of the city were examined. Between January and September 2018, seasonal samples were taken, and the microbiological quality standards of the consumed water were determined. Analysis results were evaluated within the framework of ITASHY (Turkish Regulations on Water for Human Consumption), which is in line with the European Union Drinking Water Directive. In addition, obtained results were also evaluated in terms of environmental health.

1. MATERIALS AND METHODS

1.1. Study Area

The maps of the study area were produced from the topographic base maps of the region via ArcMap 10.8 software, one of the Geographical Information Systems software (Figure 1). Sanliurfa province is one of the fast-growing metropolitan city located in the center of the Southeastern Anatolia Region. The area of Sanliurfa land is 19,242 km^2 and it consists of plateaus (61.7%), mountains (22%) and arable plains (16%).

Figure 1: Location Map of The Study Area

Since Sanliurfa has mostly limestone rocks in terms of geological structure, karst structures are quite common. This provides a great advantage to the region in the feeding of groundwater during periods of sufficient rainfall. The largest surface water resources of Sanliurfa are the Euphrates River and the Ataturk and Birecik Dam Lakes built on it. Sanliurfa consists of Middle–Upper Eocene aged Birecik, Middle Eocene–Oligocene aged Gaziantep, Oligocene–Lower Miocene aged Tektek mountains, and Lower Miocene aged Euphrates formations, from bottom to top, respectively. It has a continental climate with hot and dry summers and rainy and relatively warm winters. Like many provinces in Turkey, Sanliurfa, which is under the influence of different climatic zones in summer and winter periods, is under the influence of Basra low pressure in summer.

In the metropolitan districts of Sanliurfa, the water coming from the exit mouth of the Sanliurfa tunnels in the Ataturk Dam Lake is used as a source of drinking and usage water. These tunnels were built to irrigate the Harran Plain and their construction was completed in 1994. Ataturk Dam Lake is also used as a water source in Hilvan district. There is no drinking water treatment plant in Hilvan district. In Suruç and Birecik districts, the caisson wells drilled in the water tanks of Birecik and Karkamış Dam Lake are used as drinking water sources. In Siverek, Viranşehir and Halfeti districts, deep boreholes and springs from groundwater are used. However, in Akçakale, Harran, Ceylanpınar and Bozova districts, deep boreholes are used as drinking water sources.

1.2. Sampling Points

From 77 sampling points created in thirteen district centers, 308 samples were taken to represent the entire network in winter, spring, summer and autumn seasons between January and September 2018. The samples were taken from the active fountains and taps directly connected to the network via the monitoring points determined by the Provincial and District Health Directorates. The samples were taken in accordance with the methods determined in the "Handbook on Sample Collection, Transport and Analysis of Water for Human Consumption" published by the Ministry of Health in 2008.

1.3. Material

Microbiological samples were taken in 500 ml pure thiosulfate polypropylene bottles, and physicochemical samples were taken in 1.5 liter polyethylene bottles. Hach brand device (colorimetric method) was used for free chlorine measurements, Portable Hach-Lange HQ40d multi-measurement device was used for pH and electrical conductivity.

Statistical analyzes were performed using the SPSS® Statistics software. Central tendency (mode, median, arithmetic mean, maximum and minimum values) and measures of distribution (variance, standard deviation, coefficient of variance) were found. By considering the maximum, minimum and arithmetic mean values of the data, they were compared with the ITASHY limit values, which are the standards related to drinking and usage water in Turkey. Normality tests were performed to determine whether the values of the measured parameters were normally distributed. In order to examine whether the difference between the seasonal values of the parameters is significant, Kruskal Wallis H test, which is one of the non-parametric tests, was applied. Distribution charts of microbiological parameters were created with Microsoft Office 365 Excel.

1.4. Method

Before taking samples for microbiological analysis, the spout of the faucet was wiped with a clean cloth and the strainer equipment etc. has been removed. Water was poured until the water temperature was stable. Then the tap was turned off and its mouth and surroundings were flamed. After the sample bottle was filled to the marked spot, its cap was quickly closed, and the bottle was labelled. Microbiological samples were taken in 500 ml polypropylene bottles with pure thiosulfate and transferred to the laboratory in cold chain (+4 ^{o}C) within 4–6 hours.

1.5. Drinking and Usage Water Quality Standards

Since drinking water is an important issue in terms of environment and public health, it has attracted a lot of attention by environmental and public health researches in Turkey and in the world. According to the report published by the World Health Organization in 2017, more than one billion people in the world do not have access to healthy and safe drinking water

(WHO, 2017). In a report of UNESCO published in 2016, it was emphasized that water should be protected at its source and that it should be managed correctly. National and international standards for drinking-usage water are presented in Table 1.

Table 1: National and Some International Quality Standards for Drinking and Usage Water Belonging to The Investigated Parameters

Parameter	Analysis Method	Unit	ITASHY (2005)	WHO (2017)	USEPA (2018)
Total coliform	membrane filtration	number/100 ml	0/100 ml	0/100 ml	0/100 ml
E. coli	membrane filtration	number/100 ml	0/100 ml	0/100 ml	0/100 ml
Enterococci	membrane filtration	number/100 ml	0/100 ml	0/100 ml	0/100 ml

2. RESULTS

2.1. Microbiological Analysis

Microbiological analyzes were carried out at SUSKI (General Directorate of Water and Sewerage Administration of Sanliurfa Metropolitan Municipality) Drinking Water Treatment Plant Laboratory with the financial support of HUBAP (The Coordinating Unit for Scientific Research Projects at Harran University, Project No: 17198). Total coliform (TC), *E. coli* (TS EN ISO 9308-1), and *Enterococci* (EC) (TS EN ISO 7899-2) measurements were performed via membrane filter method. The water samples were gently shaken to ensure homogeneity. 100 ml water sample was filtered from three membrane filters prepared for TC, *E. coli* and EC. After filtering process, TC and *E. coli* were incubated in chronogeneous agar broth at 37 ^{o}C for 24 hours whereas EC was incubated in Avida broth at 37 ^{o}C for 48 hours. Colonies formed at the end of the incubation period were counted. It was observed that red colonies were formed for TC, blue for *E. coli* and cherry color colonies for EC (Figure 2).

Figure 2: Microbiology Laboratory and Some Analysis Images

Detected anomalies are nonconformities caused by external contamination. It has been reported that nitrate and conductivity problems are more common particularly in irrigated agriculture areas (Kahraman et al., 2016, Yazici-Karabulut et al., 2019, Yazici-Karabulut et al., 2021). As a result of this preliminary data, it was determined to examine TC, *E. coli*, and EC within microbiological parameters.

2.1.1. Sanliurfa

The sampling points of Sanliurfa city center are shown in Figure 3.

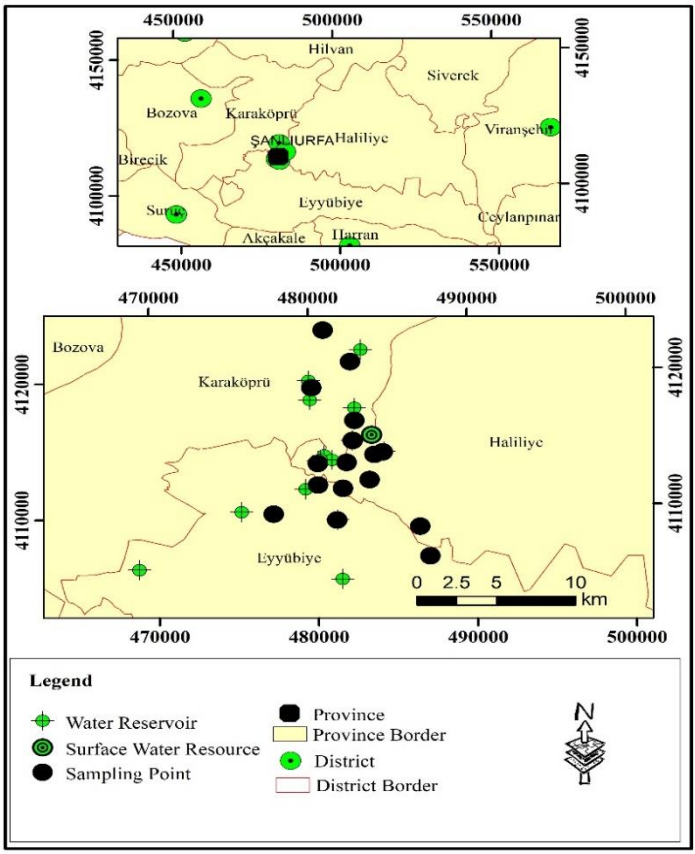

Figure 3: Sampling Points of Şanlıurfa City Center

In the analyzes of microbiological parameters, nonconformities on TC (50 Cfu/100 ml and 24 Cfu/100 ml respectively) were detected in the monitoring point of M16 in summer and autumn. The observation point of M16 is at the end point of the water network. Free chlorine values of 0.2 ppm and 0.3 ppm were detected respectively at the chlorine measurements carried out at the periods at which the nonconformities were detected. Apart from that, no inconsistency with ITASHY regulations was detected in terms of microbiological parameters. Microbiological nonconformities were detected when chlorination was found to be insufficient.

2.1.2. Akçakale

The sampling points of Akçakale district center are shown in Figure 4.

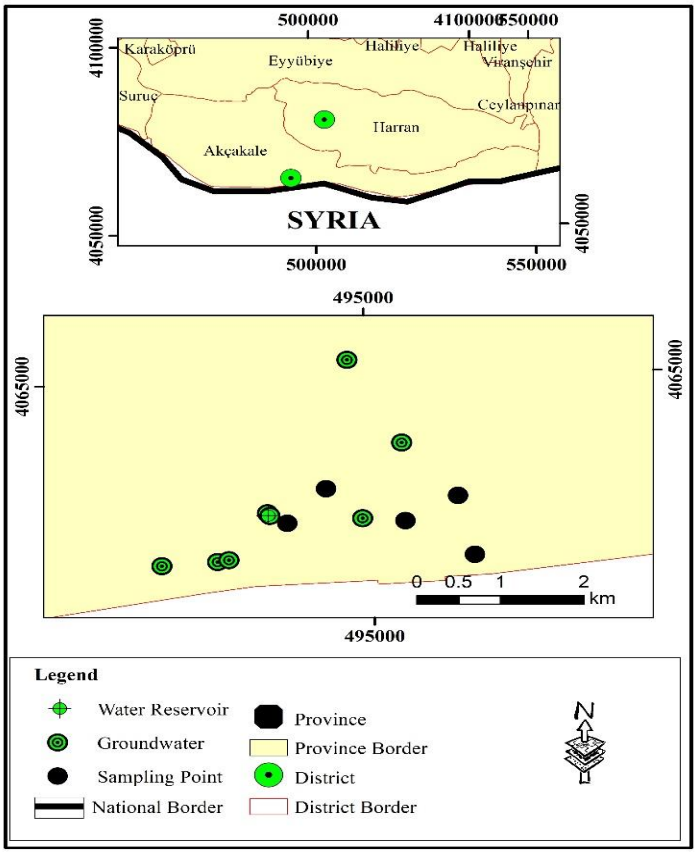

Figure 4: Sampling Points of Akçakale District

Focusing on seasonal microbiological values, no nonconformity was detected in winter. At the sampling point of A3, TC (100 Cfu/250 ml), *E. coli* (25 Cfu/250 ml) and EC (35 Cfu/250 ml) were detected in spring. In summer, TC (27 Cfu/250 ml) at the sampling point of A4 and TC (250 Cfu/250 ml) and *E. coli* (250 Cfu/250 ml) at the sampling point of A5 were detected. In autumn, TC (27 Cfu/250 ml) at the sampling point of A2 and TC (261 Cfu/250 ml) and EC (10 Cfu/250 ml) at the sampling point of A4 were observed. Depending on the observations, much more nonconformities were detected in summer and autumn (Figure 5).

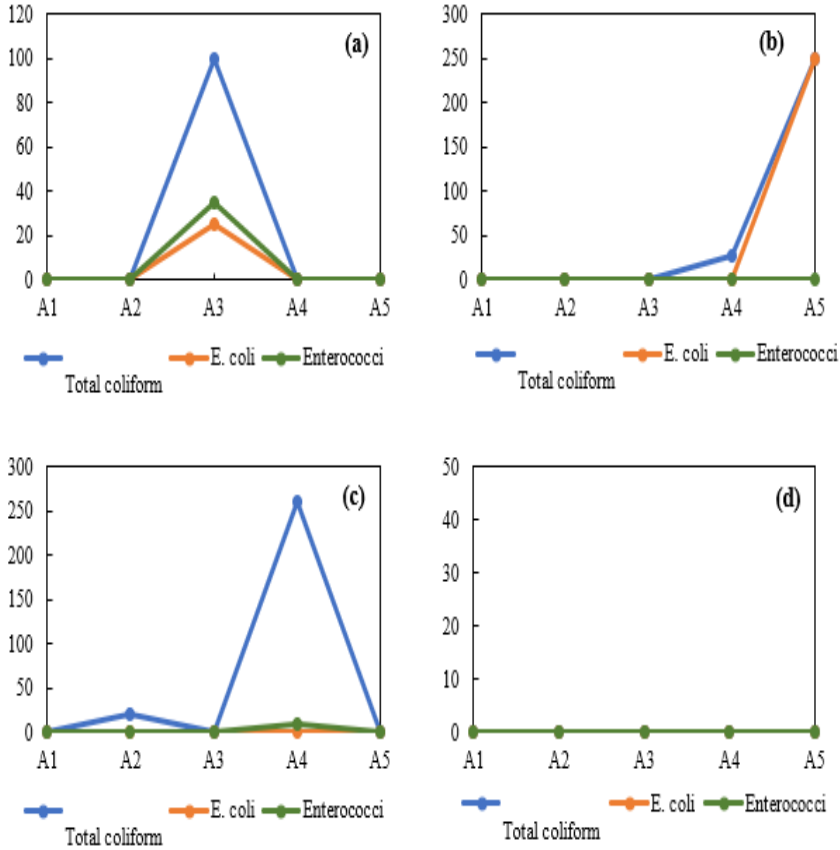

Figure 5: Seasonal Microbiological Analysis Values of Akçakale District: (a) Spring, (b) Summer, (c) Autumn, (d) Winter

2.1.3. Birecik

The sampling points of Birecik district center are shown in Figure 6.

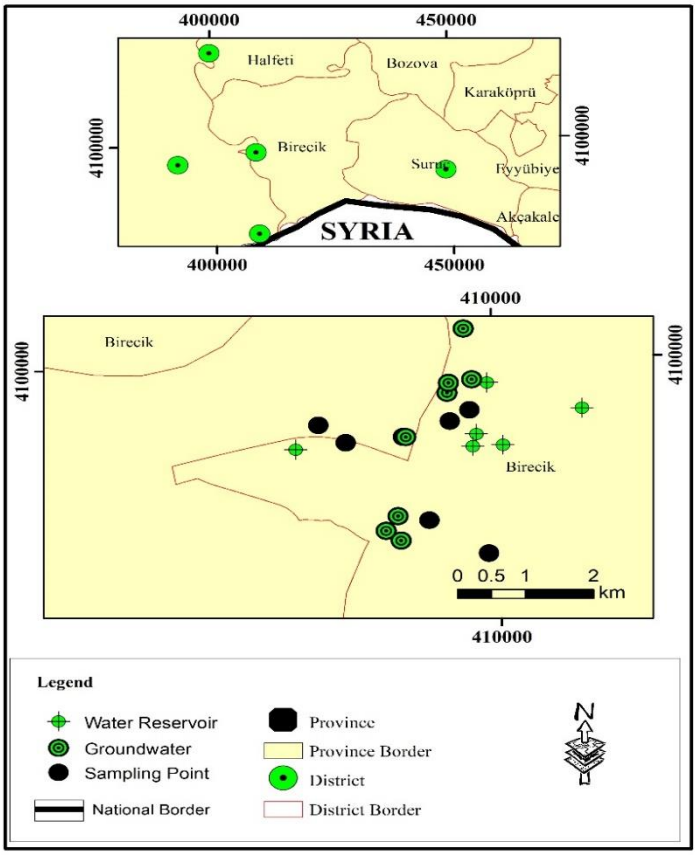

Figure 6: Sampling Points of Birecik District

In winter, *E. coli* was detected at only the sampling point of B2. The analyzes results at all sampling points were reached in accordance with the microbiological regulations. While *E. coli* and EC were not detected in summer, TC was detected at the sampling points of B1 (100 Cfu/100 ml), B5 (250 Cfu/100 ml) and B6 (72 Cfu/100 ml). However, in autumn, TC was detected at the sampling points of B3 (258 Cfu/100 ml), B5 (4 Cfu/100 ml) and B6 (4 Cfu/100 ml) whereas *E. coli* and EC were not detected (Figure 7). Even though the water includes free chlorine, it is likely that sufficient contact time of microbiological nonconformities in summer and autumn with chlorine cannot be provided because of direct connection of wells to water network.

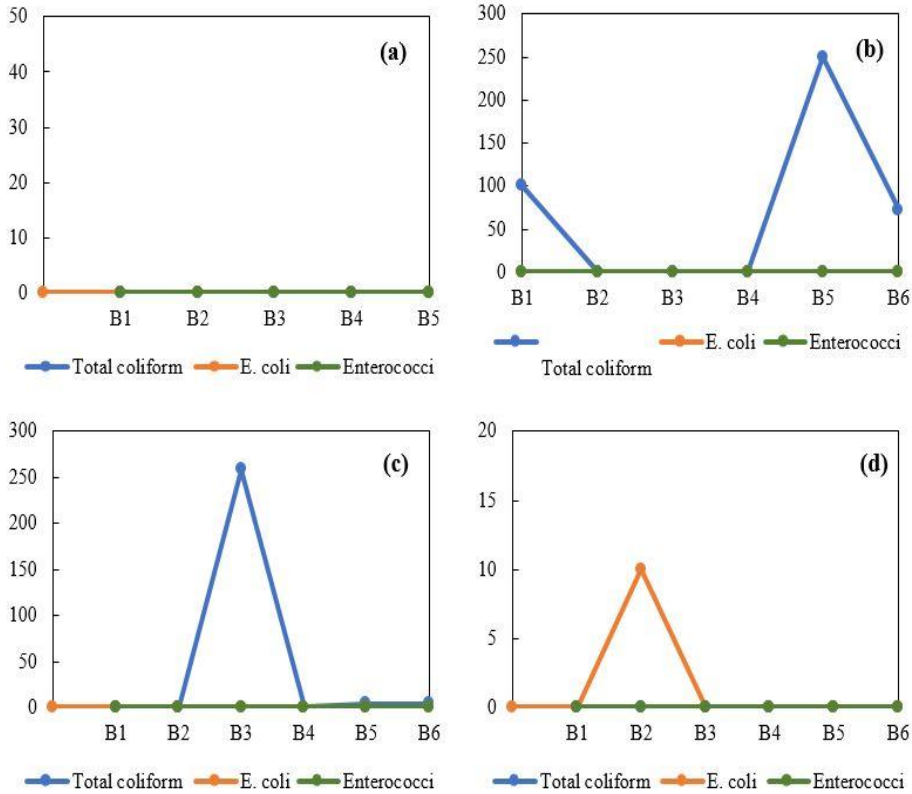

Figure 7: Seasonal Microbiological Analysis Values of Birecik District: (a) Spring, (b) Summer, (c) Autumn, (d) Winter

2.1.4. Bozova

The sampling points of Bozova district center are shown in Figure 8.

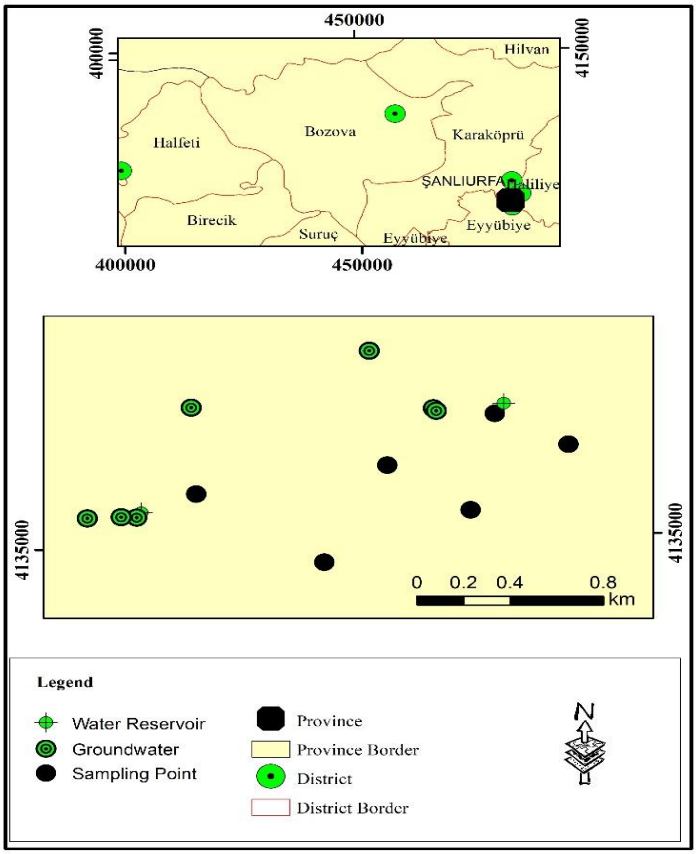

Figure 8: Sampling Points of Bozova District

In microbiological analyzes, nonconformities on TC (5 Cfu/100 ml) and *E. coli* (10 Cfu/100 ml) at Bz6 sampling point in winter, TC (5 Cfu/100 ml) at Bz5 sampling point in spring, TC (250 Cfu/100 ml), *E. coli* (250 Cfu/100 ml) and EC (100 Cfu/100 ml) again at Bz5 sampling point in summer were detected. In autumn, no inconsistency with ITASHY regulations was observed in Bozova (Figure 9).

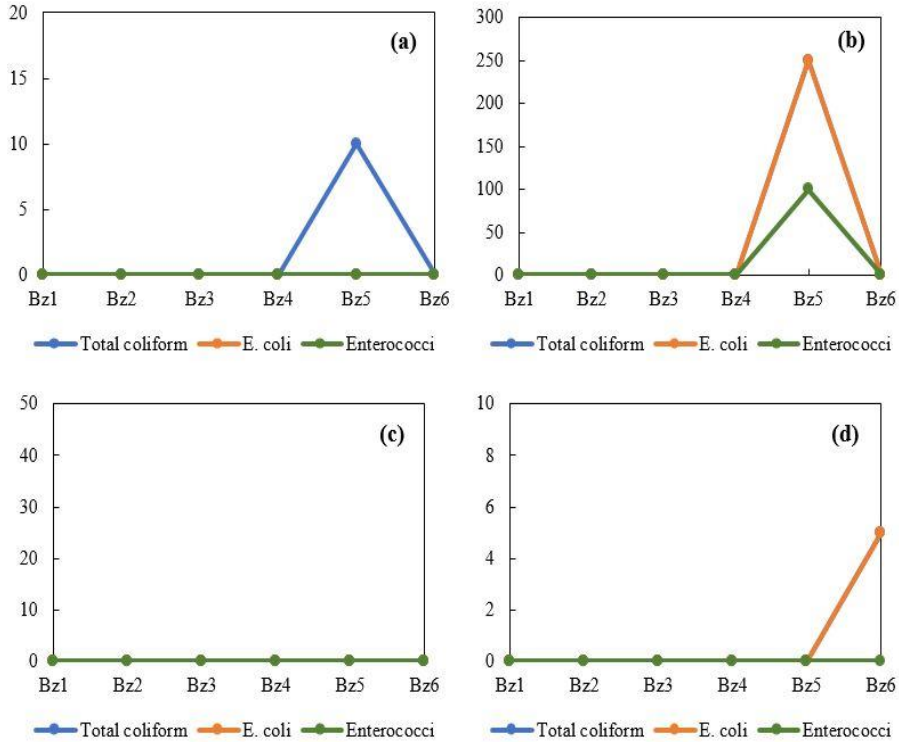

Figure 9: Seasonal Microbiological Analysis Values of Bozova District: (a) Spring, (b) Summer, (c) Autumn, (d) Winter

2.1.5. Ceylanpınar

The sampling points of Ceylanpınar district center are shown in Figure 10.

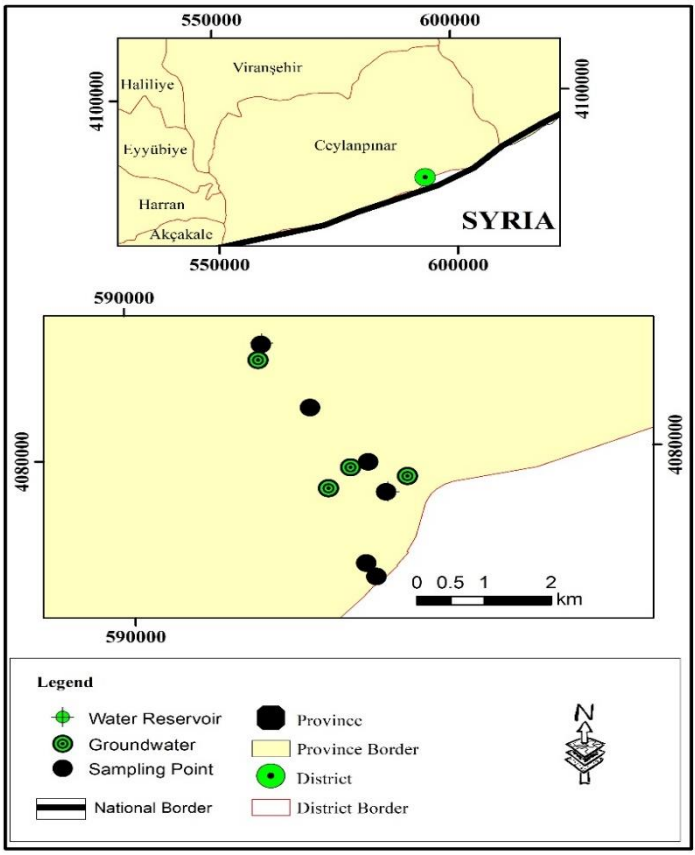

Figure 10: Sampling Points of Ceylanpınar District

In the samples taken in winter, nonconformities on TC were observed at the sampling points of C1 (5 Cfu/100 ml) and C2 (27 Cfu/100 ml). TC was detected at the points of C2 (45 Cfu/100 ml), C3 (55 Cfu/100 ml) and C4 (13 Cfu/100 ml) in spring. In summer, TC at the sampling points of C1 (60 Cfu/100 ml), C3 (80 Cfu/100 ml) and C4 (100 Cfu/100 ml), and *E. coli* at the sampling point of C4 (20 Cfu/100 ml) were noticed. No nonconformity was detected in autumn (Figure 11).

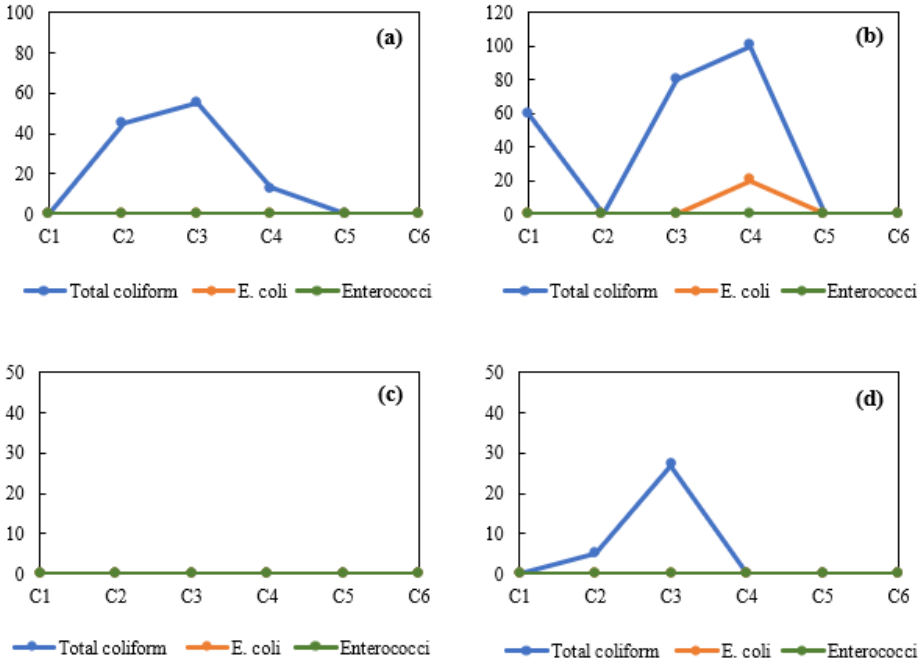

Figure 11: Seasonal Microbiological Analysis Values of Ceylanpınar District: (a) Spring, (b) Summer, (c) Autumn, (d) Winter

2.1.6. Halfeti

The sampling points of Halfeti district center are shown in Figure 12.

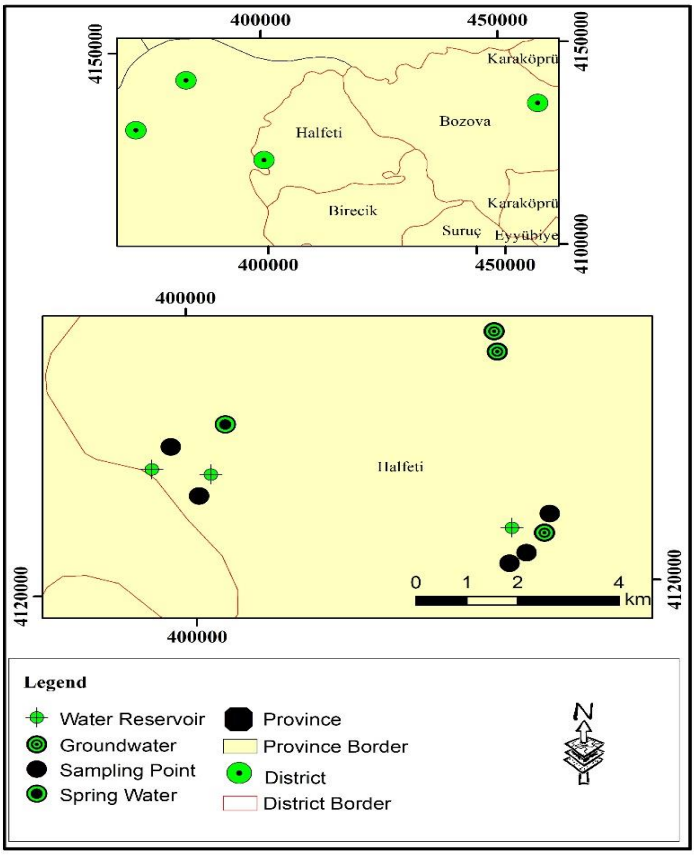

Figure 12: Sampling Points of Halfeti District

In microbiological analysis carried out in Halfeti district in winter, TC (5 Cfu/100 ml) and *E. coli* (5 Cfu/100 ml) were detected at the sampling point of H2. In Summer, TC (24 Cfu/100 ml) was observed at the sampling point of H4, but for all samples, no microbiological nonconformity was noticed in spring and autumn (Figure 13).

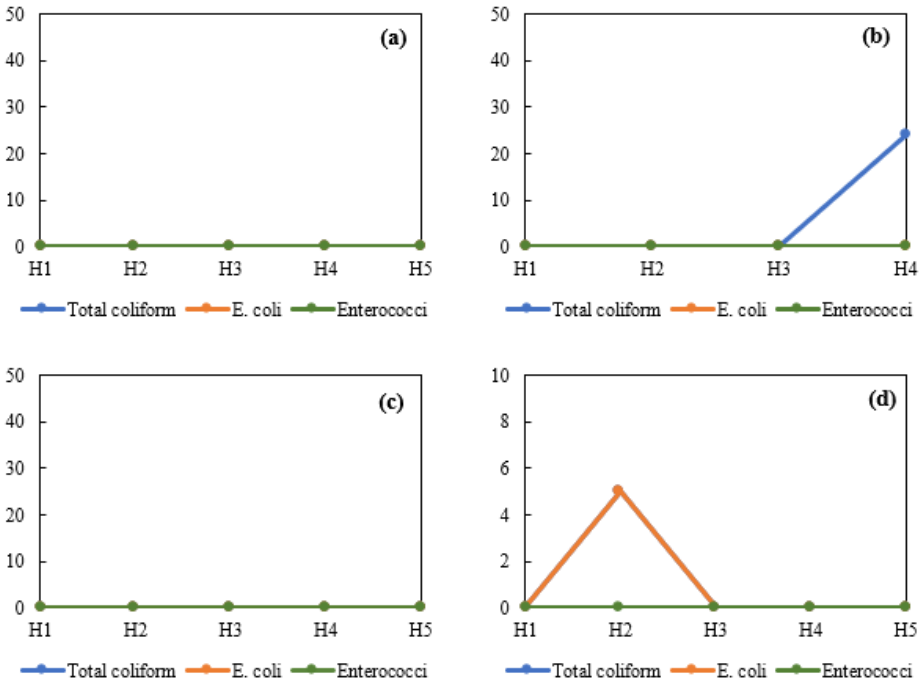

Figure 13: Seasonal Microbiological Analysis Values of Halfeti District: (a) Spring, (b) Summer, (c) Autumn, (d) Winter

2.1.7. Harran

Many researches carried out in terms of water quality entire the Harran Plain (Yesilnacar and Gulluoglu, 2007; Yesilnacar et al., 2008; Yesilnacar and Gulluoglu, 2008; Yetiş et al., 2021, Yenigun et al., 2021). However, almost all of these studies are related to the chemical and physical quality of drinking ground water. Therefore, it is striking and important that this study is aimed at microbiological drinking and usage water. The sampling points of Harran district center are shown in Figure 14.

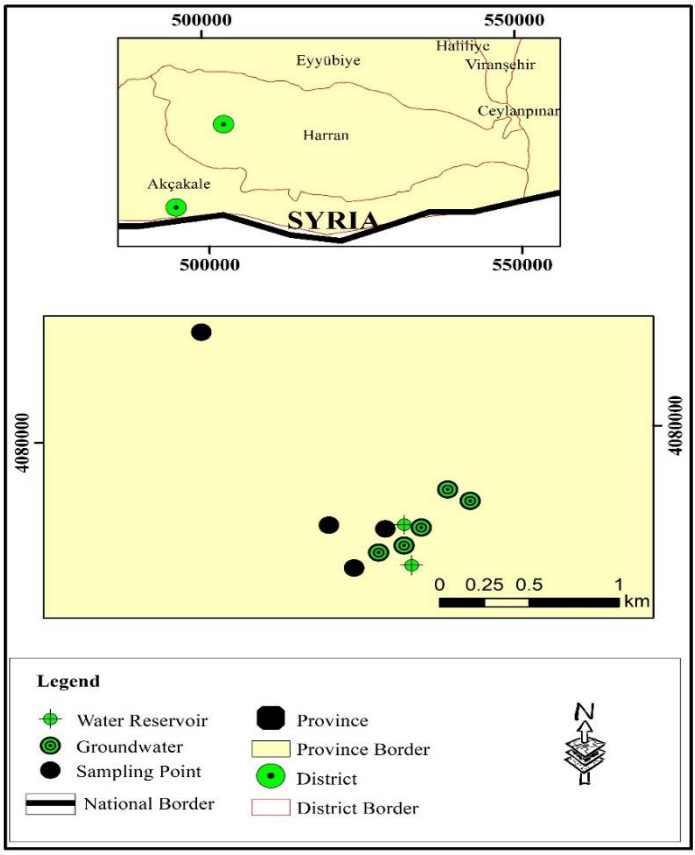

Figure 14: Sampling Points of Harran District

From all the samples collected in winter, nonconformity on TC (5 Cfu/100 ml) was observed only at the sampling point of H2. In spring, TC (35, 37 and 60 Cfu/100 ml, respectively) was detected at the sampling points of H1, H2 and H3. *E. coli* and EC were observed in both seasons. No microbiological nonconformity was noticed for any samples in summer. However, a high-level microbiological nonconformity was observed in autumn during which residual chlorine was insufficient in mains water. In this season, TC (180, 150, 50, 200 Cfu/100 ml, respectively) was detected in all sampling points. In addition, *E. coli* (70, 20 and 50 Cfu/100 ml, respectively) at the sampling points of H1, H2 and H4, and EC (20, 10 and 40 Cfu/250 ml, respectively) at the sampling points of H1, H3 and H4 were detected in same season (Figure 15).

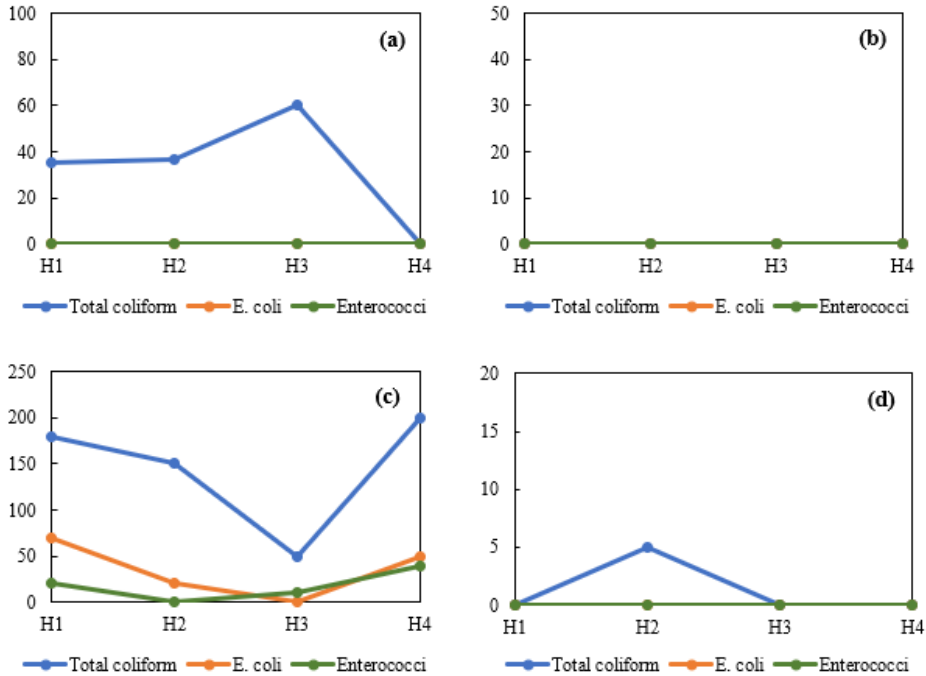

Figure 15: Seasonal Microbiological Analysis Values of Harran District: (a) Spring, (b) Summer, (c) Autumn, (d) Winter

2.1.8. Hilvan

The sampling points of Harran district center are shown in Figure 16.

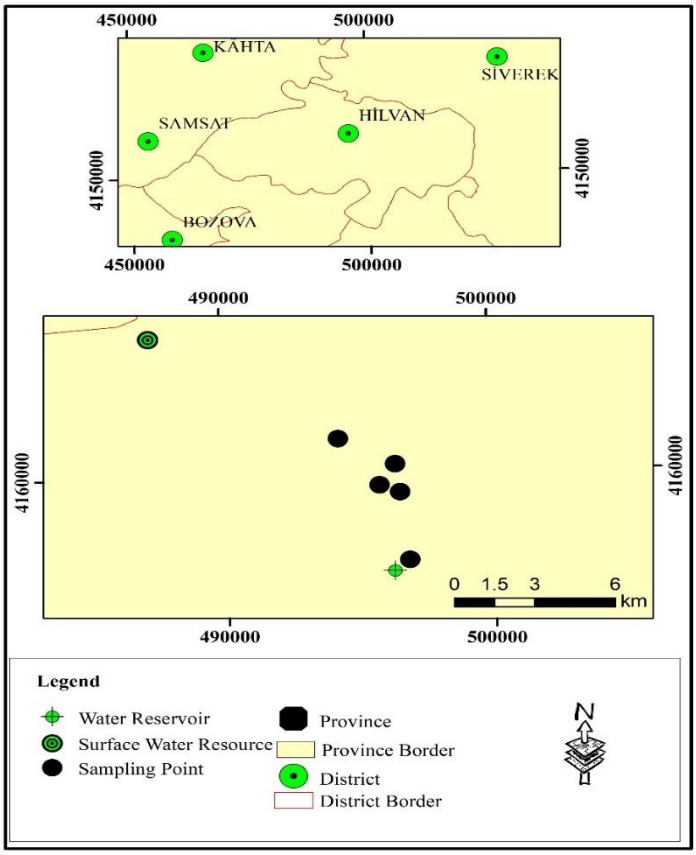

Figure 16: Sampling Points of Hilvan District

Based on the samples taken from Hilvan district in winter, TC (5 Cfu/100 ml) and EC (100 Cfu/250 ml) were detected at the sampling point of Hi1 at which free chlorine was measured as 0 ppm. In the water tank in which free chlorine was detected as 0 in spring, TC (50 Cfu/100 ml) and *E. coli* (20 Cfu/100 ml) were observed. Additionally, in summer when no sufficient free chlorine was detected all across the water network. TC (250 Cfu/100 ml) and *E. coli* (250 Cfu/100 ml) were detected at both the sampling points of Hi3 and Hi5. However, no microbiological nonconformity was observed in autumn at which there was sufficient free chlorine in water network (Figure 17).

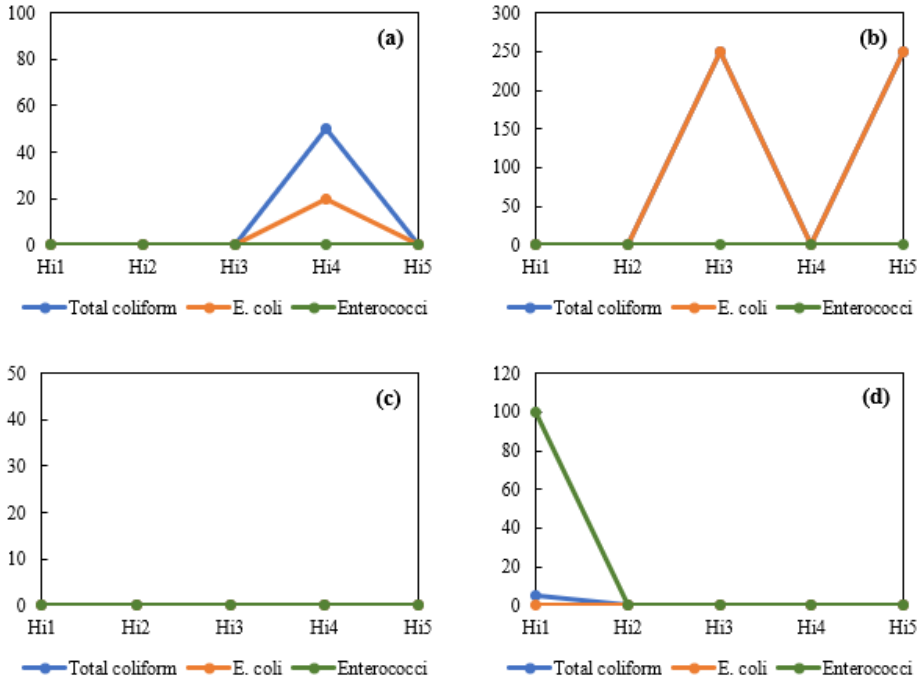

Figure 17: Seasonal Microbiological Analysis Values of Hilvan District: (a) Spring, (b) Summer, (c) Autumn, (d) Winter

2.1.9. Siverek

The sampling points of Siverek district center are shown in Figure 18.

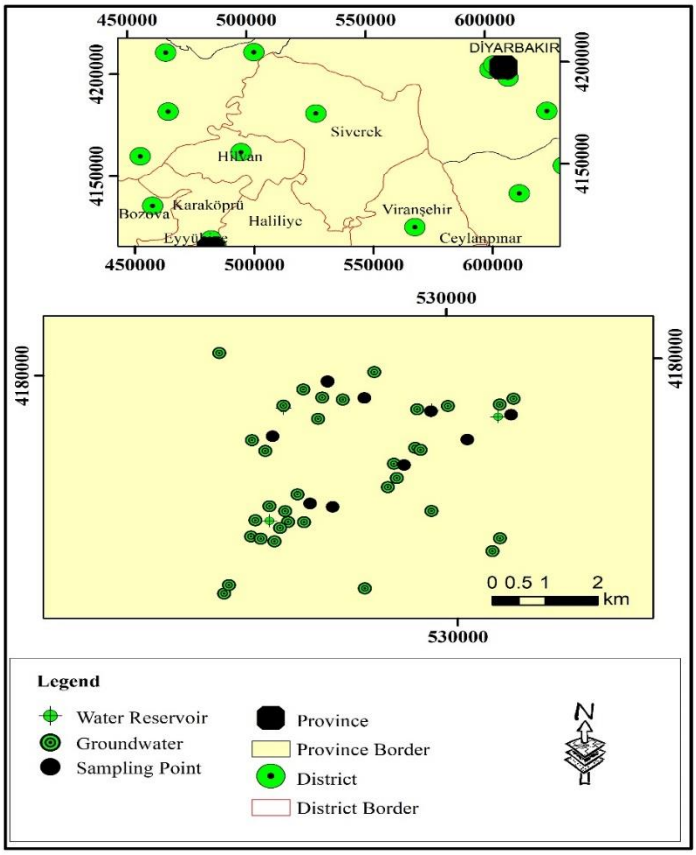

Figure 18: Sampling Points of Siverek District

According to all microbiological analyzes, it was detected that there were TC in 15 samples (42%), *E. coli* in 9 samples (25%) and EC in 3 samples (0.8%) respectively. The highest-level nonconformities were detected in summer and autumn. The level of free chlorine in water was observed as "0" at the sampling points at which microbiological nonconformities were high. Another feature of those sampling points was that they were the fields which were supported by the wells directly connected to the network without any transferring to tanks (Figure 19).

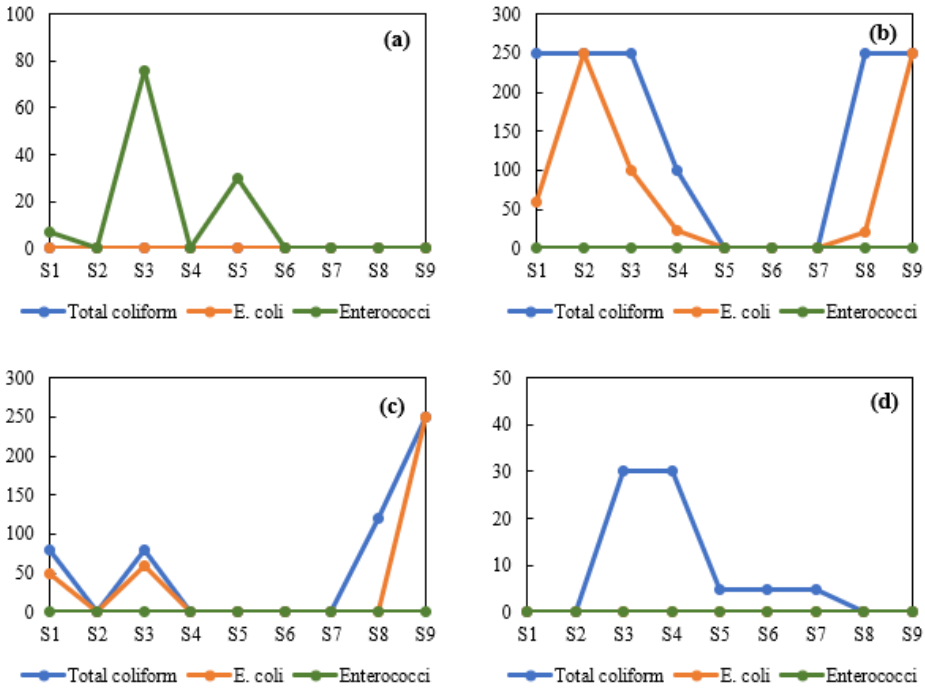

Figure 19: Seasonal Microbiological Analysis Values of Siverek District: (a) Spring, (b) Summer, (c) Autumn, (d) Winter

2.1.10. Suruç

The sampling points of Suruç district center are shown in Figure 20.

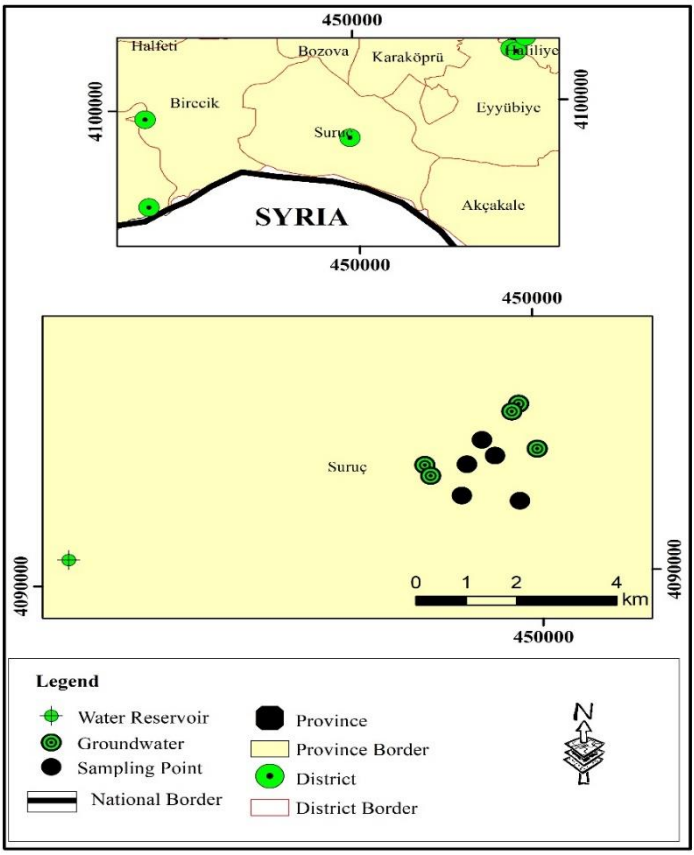

Figure 20: Sampling Points of Suruç District

The maximum numbers of nonconformities were noted in Suruç district based on all the province-wide analyzes. In winter, TC (5 Cfu/100 ml) was observed at the sampling points of Src1, Src2 and Src3. At the sampling point of Src2, TC at the value of 250 Cfu/100 ml was detected in winter. The value of TC for other sampling points were 100 Cfu/100 ml again in winter. *E. coli* at the value of 50 Cfu/100 ml was noted at the sampling point of Src6, and for other points, it was 100 Cfu/100 ml. As to EC, the detected the value for the sampling point Src2 was 90 Cfu/100 ml, and it was 60 Cfu/100 ml for Src6. However, at the other sampling points, EC (100 Cfu/100 ml) was observed. In summer, TC (250, 250, 250, 100, 120, 90 Cfu/100 ml, respectively), *E. coli* (100, 50, 120, 50, 70, 25 Cfu/100 ml, respectively) and EC (60, 50, 30, 30, 30, 20 Cfu/100 ml, respectively) were detected at all the

sampling points. In autumn, TC (240, 323, 50, 220, 200, 376 Cfu/100 ml, respectively) and EC (20, 20, 10, 25, 10, 1 Cfu/100 ml, respectively) were detected again at all the sampling points (Figure 21).

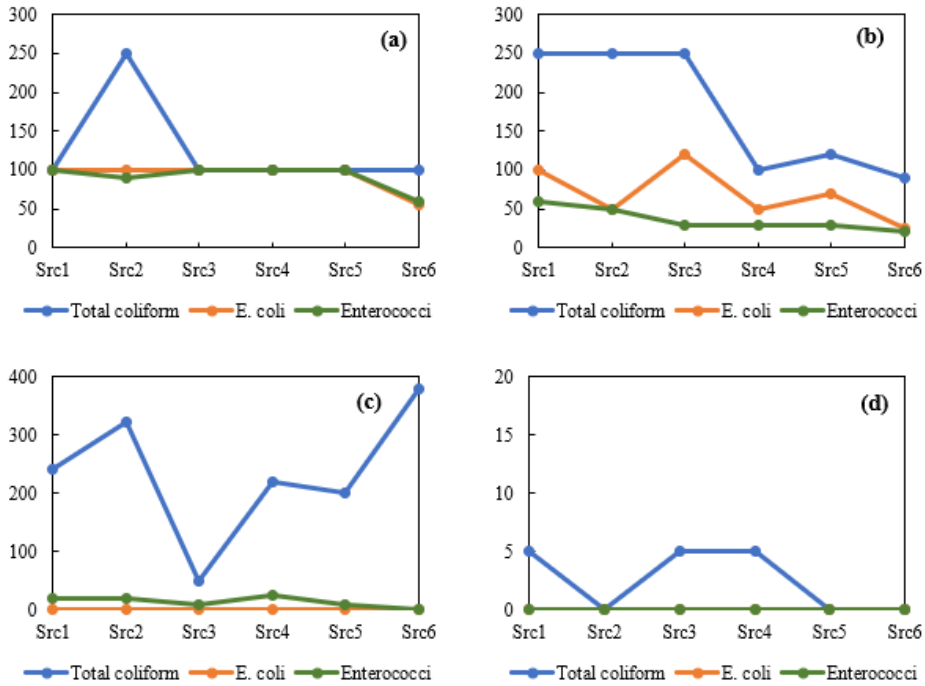

Figure 21: Seasonal Microbiological Analysis Values of Suruç District: (a) Spring, (b) Summer, (c) Autumn, (d) Winter

2.1.11. Viranşehir

The sampling points of Viranşehir district center are shown in Figure 22.

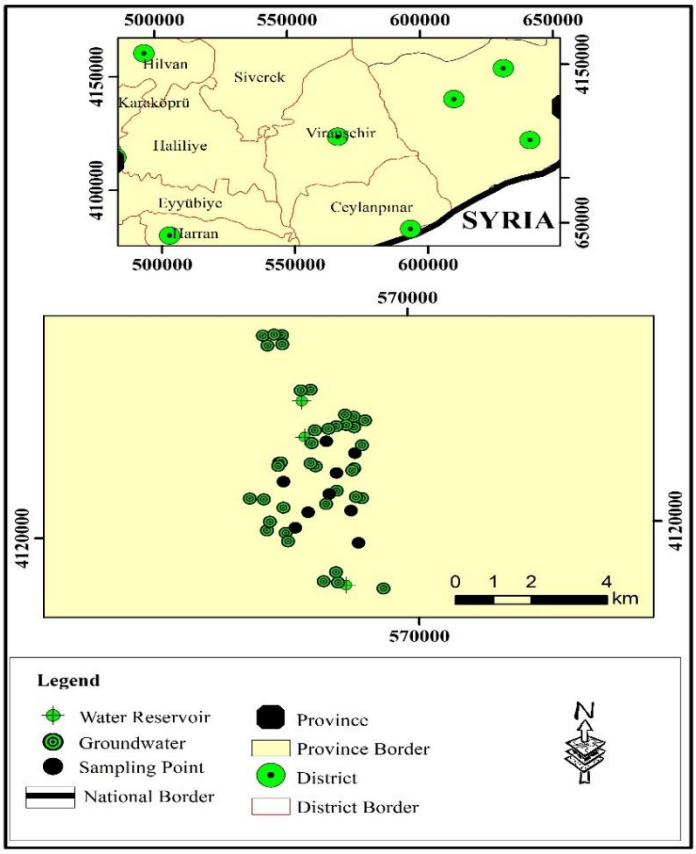

Figure 22: Sampling Points of Viranşehir District

Focusing on the microbiological samples of Viranşehir district, we can note that TC (19 and 100 Cfu/100 ml, respectively) was detected at the sampling points of V5 and V8. The values of TC observed at the sampling points of V2 and V9 for spring were 100 and 20 Cfu/100 ml, respectively. In summer, when the microbiological nonconformities were observed at highest values, TC was detected at the sampling points of V2 (17 Cfu/100 ml), V4 (40 Cfu/100 ml), V5 (24 Cfu/100 ml), V6 (100 Cfu/100 ml) and V8 (50 Cfu/100 ml). Moreover, in summer, EC was noticed at the sampling points of V2 (5 Cfu/100 mL), V4 (20 Cfu/100 ml), V5 (20 Cfu/100 ml) and V8 (25 Cfu/100 ml). In autumn, it was observed that there was TC (16 Cfu/100 ml) at the sampling point of V6 (Figure 23).

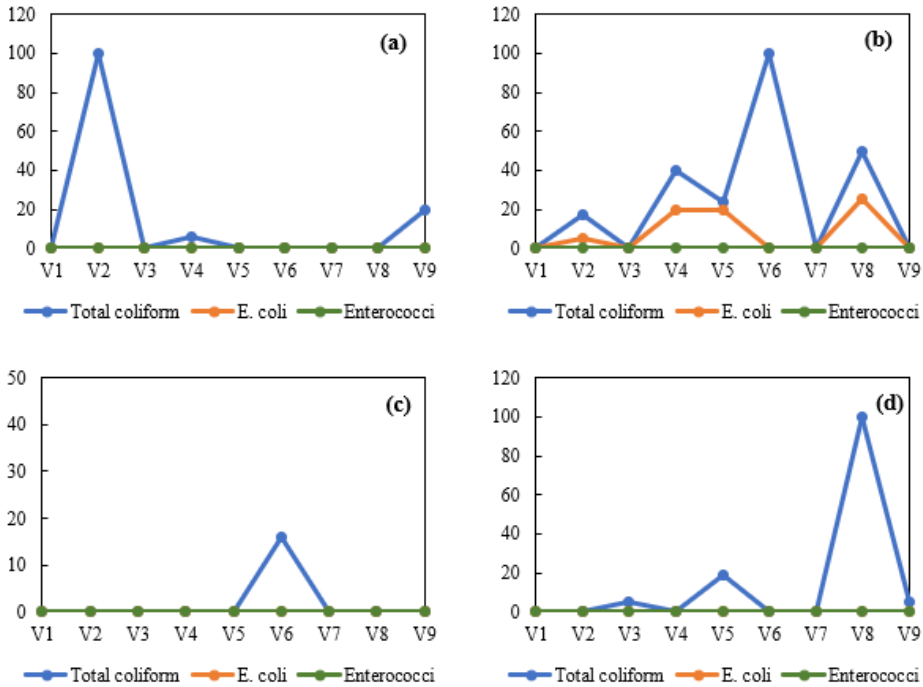

Figure 23: Seasonal Microbiological Analysis Values of Viranşehir District: (a) Spring, (b) Summer, (c) Autumn, (d) Winter

3. DISCUSSION

Sanliurfa has the surface water sources like Birecik and Ataturk Dam and also underground sources like Ceylanpınar plain which has the capacity to meet one fifth of Turkey's overall water need (Yetiş, 2013). Despite all, water cut is often experienced due to insufficiency in all districts apart from the metropolitan ones. These water cuts are seriously problematic for public health. Due to old and detracted water network, the negative pressure stemming from those cuts leads the leaks of foul waters to drinking-water network, and hereby it often causes many diseases such as diarrhea, typhoid, cholera and dysentery.

The tanks and water networks of all districts, except for metropolitan ones, are proved to be insufficient to meet the water needs of district centers whose populations have gradually increased due to the factors such as rural-urban migration, high birthrate and vice versa. The water need of new neighborhoods is tried to meet via the direct connection of numerous wells in

street alleys to the network. It was observed that chlorinators were fixed to wells to chlorinate the water before transferring it to the network, and problematic control and failure in chlorination were likely to emerge since there were numerous wells even though chlorine was usually detected at the sampling points. In addition, microbiological nonconformities were observed in some samples because adequate contact time was not able to provide for disinfection even though chlorine was found in network.

The contaminations in drinking and usage waters were mostly noticed after diseases or epidemics emerged. The authorities started working out the details and reasons of contamination and took the precautions even after noticing the problems. Most of the community were affected from the epidemic till the precautions were taken since the microbiological analyzes took much time. According to Sorensen et al. (2015), due to the water pollution, many people catch the diseases that are contaminated with water and even some of them die. It is stated that most of those diseases stem from the enteric noxas that are leaked to water in the places where infrastructure of drinking water and sewage is old and in bad condition. It is noted that hydrochemical and physical analyzes on nitrate, ammonium and water turbidity, and also microbiological analyzes for detection of indicator organisms like *E. coli* were conducted in order to detect whether there is any infection. It is emphasized that a special lab, qualified staff and more than eighteen hours of work are needed for concluding the analyzes. Moreover, another remarked point is that process of concluding analyzes takes a very long time in critical conditions which are likely to cause an epidemic. At this stage, it is emphasized that keeping the pace with technological developments and specifically using mobile devices for on-site measurement will be faster and more economic.

According to Sahan et al. (2016)'s field researches which were carried out in Elbistan District of Kahramanmaraş Province upon the increasing complaints of naussa-vomitting, stomachache and diarrhea, norovirus was detected in patients' stool and in drinking and usage water of district. It is noted that no chlorine was detected in residual chlorine measurements in periods in which augmentations in case numbers were observed, and again based on the analyzes results in same periods, no physicochemical nonconformity was observed regarding ITASHY regulations. However, a high

level of microbiological nonconformity was noticed in same measurements. It is emphasized that a very big number of people (77.510 patients according to inquisitions in healthcare facilities) with the complaints of diarrhea and vomiting applied the hospitals until the detection process was concluded.

New wells have been drilled in street alleys since the current drinking and usage water network is proved to be insufficient to meet the water need of increasing population of city centers which have rapidly grown due to constant rural-urban migration. These wells are in danger of pollution stemming from surface run-off and the leaks of sewage systems. Number of such wells is very high in Siverek and Viranşehir districts, and there, microbiological nonconformities were detected due to insufficient contact time for disinfection even though chlorination was performed in those districts. These microbiological nonconformities have always been seriously problematic in terms of public health. According to the fieldwork carried out by Gemci (2016) in Kahramanmaraş, it is noted that there is the risk of mixing of sewage to water sources and thus, some precautions must be taken immediately even though no nonconformity has been detected in physicochemical parameters. As similar to fieldwork above, Khan et al. (2013) detected microbiological nonconformities in the fieldworks on drinking-water supplying wells in Charsadda region of Pakistan. Another significant work was conducted by Çankaya et al. (2017) in Trabzon. Water samples for this work were taken from public taps in city center. According to analyzes, 11 percent of samples were found to be not convenient regarding pH parameters regulations. In addition, microbiological nonconformities were detected in those samples.

CONCLUSION

The tanks and drinking water network is new, and water sources are sufficient in metropolitan districts. However, water shortages emerge in dry periods since water tunnels of Sanliurfa which are utilized as drinking water sources are also used in irrigation for Harran plain. According to the analyzes results, TC (50 Cfu/100 ml and 24 Cfu/100 ml, respectively) was observed in only one monitoring point in late summer and autumn, and apart from that, no microbiological nonconformity was detected. Besides, in Akcakale, no microbiological nonconformity was detected in sampling points which are

directly supported by the tank since chlorination is implemented sufficiently. However, again in Akcakale, due to both disruption in chlorination and insufficient contact time, microbiological nonconformities of TC (25%), *E. coli* (10%) and EC (10%) were observed at the points which were supported by two wells connected directly to network of district.

As to Birecik district, there are six tanks, and the water provided from some of caisson wells is supplied by being transferred to these tanks. It was observed that this condition led a set of water disinfection problems since sufficient contact time could not be reached. TC (25%) and *E. coli* (4%) were detected particularly in summer and autumn. Bozova is one of the districts that are not far from city center, and there the water taken from five bores is transferred to network by being supplied to constitutively-active tank of district. Hence, it was observed that there was sufficient free chlorine in sampling periods. Additionally, it was observed that the ratios of nonconformities on TC (8%), *E. coli* (8%), and EC (4%) were less when compared to other districts according to microbiological analyzes.

In Ceylanpınar, farthest district to city center, there are three wells, and the water taken from these wells is transferred to the network by being supplied to two tanks of the district. The nonconformities of TC (33%) and *E. coli* (4%) were detected in microbiological analyzes. As to the microbiological analyzes of Halfeti, TC (10%) and *E. coli* (5%) were noted. Located in a wide agriculture and historical site area, Harran has five bores and two tanks, one of which is elevated. Irrigation canals and flumes of Sanliurfa were completed, and hereby irrigated farming began in the region. Thus, underground water quality of the region was profoundly decreased. According to microbiological analyzes, TC was observed in one sampling point in winter, but in spring and autumn, it was observed in all points. In autumn, four sampling points were in scope, and *E. coli* and EC were detected in three of them.

Hilvan district is used as drinking and usage water source of Ataturk Dam Lake. Nonconformities on TC, *E. coli* and EC were detected at the sampling points at which chlorination was not implemented, or sufficient free chlorine was not observed. In Siverek, nonconformities on TC, *E. coli* and EC were detected in sampling points at which sufficient chlorination was not implemented. In addition, in some periods, microbiological nonconformities

were observed in sampling points which were supplied by wells directly connected to network even though there was free chlorine in water. The reason of this was insufficient contact time of water with chlorine.

As to Suruç district, due to excessive precipitation in spring, spates led the water to mix the wells, and hence the district faced water turbidity for a while. That's why, very high degree of nonconformities on TC, *E. coli* and EC were detected in the samples taken in this period. In Viranşehir, the second largest district of Sanliurfa, water network is insufficient, and hence many houses have their own private wells. In this area, samples were taken in all seasons, and it was observed that there were microbiological nonconformities in all samples.

To solve the problems on water quality, water management plans must be formed, and these plans must involve rural areas of province and also be sustainable. Sanliurfa severely experiences climate change and therefore droughts. Thus, it is urgently advised that actions like water balance sheet, immediate action plans should be initiated for a sustainable water management.

Acknowledgments

This study was funded by the Scientific Research Projects Coordinating of Harran University (HÜBAP) under Grant No. 17198.

REFERENCES

Allen, M. J., Edberg, S. C., Reasoner, D. J. (2004). Heterotrophic Plate Count Bacteria-What is Their Higher Significance in Drinking Water, International Journal of Food Microbiology, Vol.92, pp 265–274

Arya, S. K., Singh, A., Naidoo, R., Wu, P., McDermott, M. T., Evoy, S. (2011). Chemically Immobilized T4-bacteriophage for Specific Escherichia coli Detection Using Surface Plasmon Resonance, Analyst, Vol.136, pp 486–492

Ashbolt, N. J. (2004). Microbial Contamination of Drinking Water and Disease Outcomes in Developing Regions, Toxicology, Vol.198, pp 229–238

Bayhan, İ. (2021). Şanlıurfa İli İçme Kullanma Sularının Fiziksel Kimyasal ve Mikrobiyolojik Kalitesinin Araştırılması. Harran Üniversitesi, Fen Bilimleri Enstitüsü, Doktora Tezi, Şanlıurfa, pp 225 (in Turkish)

Bayhan, İ., Yeşilnacar, M. İ., Demir Yetiş, A., Tutkun, E. (2020). An Evaluation of Drinking-Usage Water Quality in terms of Environmental Health: A Case Study of Siverek (Sanliurfa), Turkey, Turkish Bulletin of Hygiene & Experimental Biology, Vol.77, pp 107–120

Boehm, A. B., Graham, K. E., Jennings, W. C. (2018). Can we swim yet? Systematic Review, Meta-Analysis, and Risk Assessment of Aging Sewage in Surface Waters, Environmental Science & Technology, Vol.52, pp 9634–9645, https://doi.org/10.1021/acs.est.8b01948

Bozkurt, A. İ. (2010). Kentlerde Sağlıklı Içme ve Kullanma Suyu Yönetimi, Kentli Dergisi, Vol.2, pp 50–52 (in Turkish)

Çankaya, S., Topbaş, M., Yavuzyılmaz, A., Yeşilbaş-Üçüncü, Ş., Karakullukçu, S., Kolaylı, C. C., Dilaver, İ., Acar, G., Parlak, B., Şahin, K., Hamzaoğlu, K., Bölükbaş, C., Çan, G., Beyhun, N. E. (2017). Trabzon Halk Çeşmelerinin Fiziksel, Kimyasal, Mikrobiyolojik Yönden Değerlendirilmesi. Türk Hijyen ve Deneysel Biyoloji Dergisi, Vol.7, No.41, pp 21–28 (in Turkish)

Devane, M. L., Weaver, L., Singh, S. K., Gilpin, B. J. (2018). Fecal Source Tracking Methods to Elucidate Critical Sources of Pathogens and Contaminant Microbial Transport Through New Zealand Agricultural Watersheds, A review. Journal of Environmental Management, Vol.222, pp 293–303

Gemci, E. (2016). Kahramanmaraş İline İçme Suyu Sağlayan Pınarbaşı, Karasu ve Ayvalı Kaynaklarının İçme Suyu Kalitesinin Araştırılması. Kahramanmaraş Sütçü İmam Üniversitesi, Fen Bilimleri Enstitüsü, Yüksek Lisans Tezi, Kahramanmaraş, pp 84 (in Turkish)

ITASHY (2005). Resmi Gazete 2005. İnsani Tüketim Amaçlı Sular Hakkında Yönetmelik. Resmi Gazete 17 Şubat 2005-Sayı: 25730 (in Turkish)

Jiang, Y. S., Riedel, T. E., Popoola, J. A., Morrow, B. R., Cai, S., Ellington, A. D., Bhadra, S. (2018). Portable Platform for Rapid in-field Identification of Human Fecal Pollution in Water. Water Research, Vol.131, pp 186–195

Jofre, J., Lucena, F., Blanch, A. R., Muniesa, M. (2016). Coliphages as Model Organisms in The Characterization and Management of Water Resources, Water, Vol.8, pp 199, http://dx.doi.org/10.3390/w8050199

Kahraman, N., Yazici-Karabulut, B., Atasoy, A. D., Yeşilnacar, M. İ. (2016). Harran Ovası Serbest Akiferinde Yaz ve Kış Dönemleri Nitrat Kirliliğinin Araştırılması (2014–2015), Harran University Journal of Engineering, Vol.2, pp 01–08 (in Turkish)

Khan, S., Shahnaz, M., Jehai, N., Rehman, S., Shah, M. T., Din, S. (2013). Drinking Water Quality and Human Health Risk in Charsadda District, Pakistan. Journal of Cleaner Production, Vol.60, pp 93–101

Nwachuku, N., Gerba, C. P. (2004). Microbial Risk Assessment: Don't Forget the Children, Current Opinion in Microbiyology, Vol.7, pp 206–209

Park, S., Lee, S., Kim, M. (2015). Modified Multiple Antibiotic Resistance Analysis for The Nonpoint Source Tracking of Fecal Pollution. KSCE Journal of Civil Engineering, Vol.19, pp 2017–2023, https://doi.org/10.1007/s12205-015-0507-9

Pavlov, D., Wet, C. M. E. de, Grabow, W. O. K. Ehlers, M. M. (2004). Potentially Pathogenic Features of Heterotrophic Plate Count Bacteria Isolated from Treated and Untreated Drinking Water, International Journal of Food Microbiology, Vol.92, pp 275–287

Pepper, I. L., Rusin, P., Quintanar, D. R., Haney, C., Josephson, K. L., Gerba, C. P. (2004). Tracking The Concentration of Heterotrophic Plate Count Bacteria from The Source to The Consumer's Tap, International Journal of Food Microbiology, Vol.92, pp 289–295

Rochelle-Newall, E., Nguyen, T. M. H., Le, T. P. Q., Sengtaheuanghoung, O., Ribolzi, O. (2015). A Shortreview of Fecal Indicator Bacteria in Tropical Aquaticecosystems: Knowledge Gaps and Future Directions, Frontiers in Microbiology, Vol.6, pp 308

Rompré, A., Servais, P., Baudart, J., de-Roubin, M. R., Laurent, P. (2002). Detection and Enumeration of Coliforms in Drinking Water: Current Methods and Emerging Approaches. Journal of Microbiological Methods, Vol.49, No.1, pp 31–54

Şahan, S., Yılmaz, Ş., Topal, S., Özarslan, F., Çeliker Yenice, A., Cemil-Göktaş, D., Temel, F., Göktepe, A., Şencan, İ. (2017). Kahramanmaraş Ili Elbistan Ilçesinde Görülen AKut BArsak Enfeksiyonu Vaka Artışı Incelemesi,

Ağustos 2016. Türk Hijyen ve Deneysel Biyoloji Dergisi, Vol.74, pp 13–20 (in Turkish)

Sorensen, J. P. R., Lapworth, D. J., Marchant, B. P., Nkhuwa, D. C. W., Pedley, S., Stuart, M. E., Bell, R. A., Chirwa, M., Kabika, J., Liemisa, M., Chibesa, M. (2015). In-situ Tryptophan-like Fluorescence: A Real-time Indicator of Faecal Contamination in Drinking Water Supplies, Water Research, Vol.81, pp 38–46

Toroglu, E., Toroglu, S. (2009). Microbial Pollution of Water in Golbasi Lake in Adiyaman, Turkey. Journal of Environmental Biology, Vol.30, No.1, pp 33–38

Unno, T., Staley, C., Brown, C. M., Han, D., Sadowksy, M. J., Hur, H-G. (2018). Fecal Pollution: New Trends and Challenges in Microbial Source Tracking Using Next-Generation-Sequencing. Environmental Microbiology, doi:https://doi.org/10.1111/1462-2920.14281

USEPA (United States Environmental Protection Agency), (2018). 2018 edition of the drinking water standards and health advisories, EPA 822-S-12-001. Washington, DC: Office of Water US Environmental Protection Agency

WHO, (2014). Antimicrobial Resistance: Global Report on Surveillance. Geneva, Switzerland: World Health Organization

WHO, (2017). Guidelines for Drinking-Water Quality: Fourth Edition Incorporating the First Addendum. World Health Organization

Yazici-Karabulut, B., Atasoy, A. D., Can, O. T., Yesilnacar, M. I. (2021). Electrocoagulation for Nitrate Removal in Groundwater of Intensive Agricultural Region: A Case Study of Harran Plain, Turkey. Environmental Earth Science, Vol.80, pp 190 https://doi.org/10.1007/s12665-021-09488-8

Yazici-Karabulut, B., Atasoy, A.D., Yesilnacar, M. I. (2019). Removal of Nitrate from Aqueous Solutions by Batch Electrocoagulation Process Using Al and Fe Plate Electrodes. Harran University Journal of Engineering, Vol.4 pp 79–88

Yenigun, I., Bilgili, A.V., Yesilnacar, M. I., Yalcin, H. (2021). Seasonal and Spatial Variations in Water Quality of Deep Aquifer in The Harran Plain, GAP Project, Southeastern Anatolia, Turkey, Environmental Earth Sciences, Vol.80, pp 568, https://doi.org/10.1007/s12665-021-09858-2

Yesilnacar, M. I., Gulluoglu, M. S. (2007). The Effects of The Largest Irrigation of GAP Project on Groundwater Quality, Sanliurfa-Harran Plain, Turkey. Fresenius Environmental Bulletin, Vol.16, No.2, pp 206–211

Yesilnacar, M. I., Gulluoglu, M. S. (2008). Hydrochemical Characteristics and The Effects of Irrigation on Groundwater Quality in Harran Plain, GAP Project, Turkey. Environmental Geology, Vol.54, pp 183–196

Yesilnacar, M. I., Sahinkaya, E., Naz, M., Ozkaya, B. (2008). Neural Network Prediction of Nitrate in Groundwater of Harran Plain, Turkey, Environmental Geology, Vol.56, pp 19–25

Yetis, A. D., Kahraman, N., Yesilnacar, M. I., Kara, H. (2021). Groundwater Quality Assessment Using GIS Based on Some Pollution Indicators over The Past 10 Years (2005–2015): a Case Study from Semi-Arid Harran Plain, Turkey, Water Air Soil Pollution, Vol.232, pp 11, https://doi.org/10.1007/s11270-020-04963-7

Yetiş, R., Atasoy, A. D., Demir Yetiş, A., Yesilnacar, M. I. (2013). Hydrogeochemical Characteristics and Quality Assessment of Groundwater in Balikligol Basin, Sanliurfa, Turkey, Environmental Earth Sciences, Vol.78, pp 3310

CHAPTER 4

DIAGNOSIS AND TREATMENT OF DYSPHONIA AFTER THYROIDECTOMY

Salih CELEPLİ[1] , İrem BİGAT[2]

[1] Dr.,Gülhane Training and Research Hospital, Department of General Surgery, Ankara, Turkey. dr.salih.celepli@gmail.com, ORCID: 0000-0002-3596-7938
[2] TOBB University of Economics and Technology, Graduate School of Science and Technology, Department of Biomedical Engineering, Ankara, Turkey. irembigat@gmail.com, ORCID: 0000-0003-0067-1675

INTRODUCTION

The injury of the recurrent laryngeal nerve (RLN), superior laryngeal nerve (SLN) or parathyroid glands after surgery in patients undergoing thyroidectomy can lead to serious consequences that impair their quality of life. Since thyroidectomies performed in the first half of the 19th century had a mortality rate of up to 40% and resulted in serious complications, it was recommended to perform this procedure only in emergencies during that time (Hanbury & Boyd, 1963; Hegner, 1932). However, with further studies in the field of anatomy, which has provided a better understanding of the thyroid gland, parathyroid gland, laryngeal nerve and vascular structures, as well as technological developments, thyroidectomy procedures have now become safer (Hegner, 1932).

In a retrospective cohort study on the database of the American College of Surgeons National Surgical Quality Improvement Program, a total of 40,025 patients that had undergone thyroidectomy were evaluated, and the early complication rate was reported as 7.74%. Preoperative factors affecting the complication rates of thyroidectomies were determined as an age of 70 years or over, Caucasian race, dependent functional status, history of congestive heart failure, smoking history, bleeding disorder and preoperative sepsis, and malignant thyroid pathology ($P < 0.05$) (Caulley et al., 2017). In the literature, factors that increase the risk of complication development after a thyroidectomy are listed as male gender, thyrotoxicosis, presence of malignancy, prevalence of resection and revision surgery (Balentine & Sippel, 2016; Doran et al., 2012; Sørensen & Klug, 2015; Stack et al., 2012), previous cervical surgery (Lefevre et al., 2007), cervical or central lymph node dissection (Flynn et al., 1994), presence of thyroid pathologies, such as thyroiditis and cancer (Goldfarb et al., 2011), size of the thyroid gland (Stavrakis et al., 2007), and surgeon experience (Duclos et al., 2012).

The most common complications after thyroidectomy are hypocalcemia, dysphonia, and hemorrhage. Hypocalcemia is the most common complication and can be treated with the administration of vitamin D in addition to calcium for at least 10 days. It has been reported that hypoparathyroidism may be temporary in 20-30% of cases and permanent in 1-4% (Thomusch et al., 2000).

The adduction of the vocal cords due to bilateral recurrent laryngeal nerve palsy, which is seen in less than 0.1% of cases after thyroidectomy, requires urgent intervention as it causes life-threatening dyspnea. It is stated that dysphonia, which is a complication specific to thyroidectomy, may be temporary in 5-11% of cases and permanent in 1-3.5%. Since most cases of RLN paralysis resolve spontaneously, it is recommended not to perform any invasive treatment for at least six months, except for emergency applications. In patients with RLN paralysis, laryngeal surgical techniques can be applied if phonation or respiratory sequelae last longer than six months, and significant improvement can be achieved with these techniques (Christou & Mathonnet, 2013).

Bleeding complications are usually due to the slippage of the ligament in one of the main artery pedicles, bleeding from the cut parenchymal surface, or injury to the jugular vein. These complications can develop even after the first six hours postoperatively. The incidence of postoperative bleeding ranges from 0% to 6.5%. Compressive hematoma in the neck compartment can be life-threatening and requires emergency surgical decompression. Postoperative compressive hematoma with acute dyspnea is a rare but serious complication that can cause death or serious long-term sequelae. Factors that may cause increased bleeding risk include male gender, presence of thyroid cancer, history of surgery, and surgeon experience (Christou & Mathonnet, 2013).

CLINICOPATHOLOGICAL FEATURES OF DYSPHONIA

Although dysphonia is the main symptom of verbal communication disorders, it also manifests with other symptoms, such as difficulty in maintaining voiced speech (asthenia), vocal fatigue, change in habitual vocal fundamental frequency, hoarseness, lack of voice volume and projection, loss of vocal effectiveness, and weakness during speech. Dysphonia can be etiologically classified as functional, organofunctional, organic, and work-related voice disorder.

After hypocalcemia, which is the most common complication after thyroidectomy, dysphonia (Kuhn et al., 2013) is the most common cause of malpractice cases postoperatively (Abadin et al., 2010; Rosenthal et al.,

2007). Thyroidectomies are responsible for 33% of iatrogenic unilateral vocal cord immobility and 80% of iatrogenic bilateral vocal cord immobility (Rosenthal et al., 2007). Studies have reported that dysphonia develops in 87% of individuals after thyroidectomy and more than 80,000 people who undergo thyroidectomy each year in the United States develop a potential disability due to postoperative voice disorders (PTVDs) (Harness et al., 1995; Sinagra et al., 2004). Kuhn et al. determined that the frequency of PTVDs after thyroid cancer surgery was 51.1%. The authors noted that hoarseness was temporary in 85.9% of these cases, and patients described deterioration in their voices as loss of loudness and shouting or inability to sing most frequently. A quarter of the patients stated that the deterioration in their voices had negative effects on their professional or personal lives. Voice therapy was recommended in only 3.4% of these patients with PTVDs, and it was reported that only 73.7% of those who received therapy achieved partial recovery (Kuhn et al., 2013).

Unilateral RLN damage presents with unilateral vocal fold immobility, dyspnea due to laryngeal paralysis, and swallowing problems, especially for liquids. In the presence of bilateral RLN damage, the dramatic consequences of life-threatening and acutely developing dyspnea can be seen. In a study by Rosato et al., the frequency of life-threatening dyspnea associated with bilateral RLN was estimated to be 0.4% of all thyroidectomies (Rosato et al., 2004).

Causes of Dysphonia

In the literature, the causes of dysphonia reported after thyroidectomy include injury to the RLN and/or external branch of the superior laryngeal nerve (EBSLN), intubation, laryngotracheal fixation of the strap muscles, and altered laryngeal vein drainage (Debruyne et al., 1997; Echternach et al., 2009; Hong & Kim, 1997).

In a previous, study the incidence of RLN damage was reported to be 9.8% in the early postoperative period and 2.3% at the end of the first year. In that study, it was stated that the use of indirect mirror laryngoscopy and fiberoptic laryngoscopy as postoperative diagnostic tools resulted in a difference in the rate of patients that developed RLN, with the incidence

varying between 2 and 6% depending on the diagnostic tool (Jeannon et al., 2009).

In a study by Bhattacharyya et al., it was reported that the rate of RLN damage in dysphonia after thyroidectomy varied between 1 and 13.3% (Bhattacharyya & Fried, 2002; Roy et al., 1956). In dysphonia cases, true nerve transection is rare dysphonia, and RLN is usually intact. Bergenfelz A. et al., evaluating a thyroidectomy series of 3,660 cases, detected unilateral RLN palsy in 142 (3.9%) of the patients in the first month after surgery, but nerve damage was only present in 14 (11.4%) (Bergenfelz et al., 2008). Some studies in the literature reported a 0-28% incidence of RLN damage during thyroidectomy (Dackiw et al., 2002; Marcus et al., 2003). In other studies, the rate of PTVD was reported to range from 16 to 89% among patients that did not evidence of RLN damage (Sinagra et al., 2004; Stojadinovic et al., 2008).

The symptoms of EBSLN injury are hoarseness, decreased pitch or voice level, and vocal fatigue, and the risk of injury in thyroid surgery is reported to vary between 37 and 72% (Hurtado-Lopez & Zaldivar-Ramírez, 2002).

Risk Factors for the Development of Dysphonia

In the literature, factors responsible for the increase in the incidence of RLN damage are described as reoperative thyroidectomy, surgery for malignant thyroid disease and neck dissection (Chan et al., 2006; de Roy van Zuidewijn et al., 1995), revision surgery, enlargement of the thyroid gland extending to the retrosternal region, abnormal anatomy (Affleck et al., 2003; Cernea et al., 2009; More et al., 2013), and presence of cancer invading adjacent structures (Duclos et al., 2010). In a meta-analysis including 14,934 patients, the incidence of RLN paralysis was determined as 3.4% for all thyroid pathologies, and it was stated that RLN paralysis was more common among patients with malignant tumors (5.7%) compared to those with benign pathologies. In the same study, the incidence of RLN paralysis was reported as 1.4% for differentiated cancers, depending on the histopathological type of thyroid cancer, but this rate increased up to 16.5% in pathologies where RLN was invaded, such as anaplastic and undifferentiated cancers (Rosato et al., 2004). In another study, it was stated that the coexistence of chronic thyroiditis and Graves' disease increased the risk of RLN damage (Dralle et

al., 2004). In addition, it has been reported that the volume of the operated thyroid lobe increases and the risk of RLN damage increases, especially in the substernal goiter (Hartl et al., 2005). There are studies in the literature indicating that the experience of the surgeon is also effective in the risk of RLN damage (Acun et al., 2004; Duclos et al., 2010). Other factors that increase the risk of RLN damage include neck hyperextension resulting in nerve traction (de Roy van Zuidewijn et al., 1995), the degree of RLN branching (Sancho et al., 2008) (anterior branches are always motor nerves) (Hartl et al., 2005), and the size of the recurrent nerve (Serpell et al., 2009).

Histopathological Features in Laryngeal Nerve Injuries

Nerve injuries can be classified as neuropraxia, axonotmesis, and neurotmesis (Seddon, 1942). Neurapraxia (injury to the myelin sheath) or axonotmesis (axonal rupture with Wallerian degeneration) may occur despite the meticulous dissection of the recurrent nerve (Hartl et al., 2005).

Neurapraxia is the temporary loss of function of an intact nerve and is recovered within days or weeks. It is caused by the compression or stretching of RLN during thyroidectomy. In axonotmesis, unlike neuropraxia, there is a macroscopic injury to the myelin sheath, which is caused by compression or stretching, similar to neuropraxia. Neurotmesis is caused by severe stretching/crushing and can cause damage to the endoneural, perineural and epineural sheaths. In this type of damage, full recovery is not possible in RLN. It can cause a lack of proper coordination in the abductor and adductor muscles innervated by the nerve, resulting in weak or no contraction. The term synkinesis refers to the simultaneous contraction of the antagonist muscles, which explains the immobility of the vocal folds despite re-innervation (Flint et al., 1991).

While the spontaneous recovery of function can occur in just a few days with a “firm nerve” in neuropraxia, in cases of axonotmesis, recovery may take up to one year, and even when the healing process is complete, recovery in muscle function may be incomplete (Hartl et al., 2005; Lynch & Parameswaran, 2017). These lesions are called paresis rather than paralysis. Axonal regrowth and healing are poor if the neural sheath is torn or if the nerve is split completely, as in neurothymesis.

DIAGNOSTIC METHODS USED IN DYSPHONIA

Vocal dysfunction is closely related to the patient's quality of life, and one of the most common causes is RLN damage during thyroidectomy (Kasemsuwan & Nubthuenetr, 1997). This damage results in impaired mobility and atrophy in the vocal cords (Abboud et al., 1999), decreased phonation time, and increased perturbation parameters (Hong & Kim, 1997). In addition, injury to the EBSLN during thyroidectomy causes the paralysis of the cricothyroid muscle, resulting in a lower pitched and hoarse voice, fatigue, and reduced range (Robinson et al., 2005).

Studies on voice dysfunction after thyroidectomy in patients without significant palsy in RLN or EBSLN suggest that possible causes of voice change are transient neural conduction disorder of RLN and EBSLN, movement disorder of the cricothyroid muscle, temporary disruption of strep muscles resulting from the surgical approach, laryngotracheal fixation (Hong & Kim, 1997), mucosal damage, hematoma, inflammation, consolidation of vocal folds due to intubation (Peppard & Dickens, 1983; Tanaka et al., 2003), and laryngeal edema caused by venous and/or lymphatic drainage disorders (Akyildiz et al., 2008).

Postoperative voice complaints can be predicted with voice assessment tools, such as the Consensus Auditory-Perceptual Sound Evaluation and Voice Handicap Index (VHI) (Stojadinovic et al., 2008). The Dysphonia Severity Index, a multi-parameter objective tool, can predict vocal complaints immediately after surgery, but it does not correlate with dysfunctions lasting more than one month. It is stated that VHI and other objective measurements are not sensitive in detecting voice changes that affect patients' quality of life. In the absence of laryngeal nerve injury, there is no correlation between PTVD and videostroboscopic laryngeal findings (Van Lierde et al., 2010).

Acoustic Voice Analysis

Acoustic voice analysis is the examination of a sound sample taken from the patient using various software. In patients with a history of thyroidectomy, five acoustic parameters are generally examined to measure voice quality: mean fundamental frequency (F0), jitter (Jitt), shimmer (Shim), noise-harmonic ratio (NHR), and maximum phonation time (MPT). F0 is the

lowest vibration rate of the vocal folds and is affected by the size and tension of the vocal folds. MPT is the measure of voice capacity, and a decrease in MPT is observed in case of vocal dysfunction or laryngeal pathology. Jitt shows frequency variability, Shim shows amplitude variability, and NHR shows increasing noise component (Kanase et al., 2019).

Studies show that Jitt, Shim and NHR values increase in the early period after thyroidectomy, while MPT decreases, and they all return to their baseline values in the late period. While some studies show a decrease in F0, others indicate no change (Lang et al., 2016; Maeda et al., 2013). Although the movement disorder of the cricothyroid muscle and laryngotracheal fixation do not cause a decrease in F0, there is no significant change in F0 if EBSLN and the cricothyroid muscle are preserved during the operation (Hong & Kim, 1997). Decreased MPT in thyroidectomy patients suggests incomplete glottic closure (Gidaye et al., 2020). Vocal cord mucosal stiffness may shorten the glottal closure time, which may require extra airflow in phonation. Therefore, it can cause frequency irregularity and amplitude variation. If RLN and EBSLN during thyroidectomy, are preserved and there is no significant damage to the vocal cords, the deterioration in these parameters at different rates is usually temporary (Maeda et al., 2013).

Voice Signal Processing Method

Signal processing techniques that aim to objectively evaluate the effect of voice in thyroid diseases have been the focus of attention of many researchers in recent years due to the advantages they can provide. Sound recordings taken using this method can be examined at the time-frequency level through various algorithms, and thus changes and losses in frequencies can be detected in the time-frequency domain.

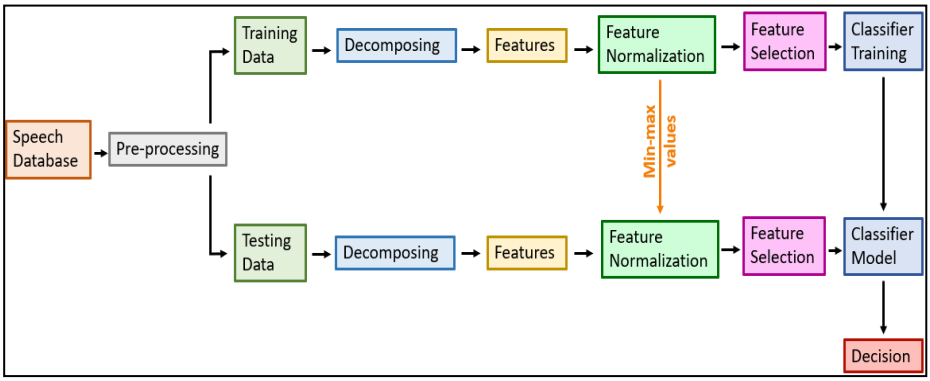

Figure 1. Voice disorder evaluation steps with voice signal processing

Figure 1 presents the various steps involved in the detection and classification of voice disturbance by voice signal processing. For classification, first, the data set is divided into training and test sets, and then a model is created on the dataset. In this algorithm, both healthy and pathological voice samples are removed from the database and separated as the training set and the test set. In the training phase, a classifier model is developed using normal and pathological sound samples. In the test set, sound samples are tested using a classifier model. The dataset is preprocessed because the data are often incomplete, noisy, and inconsistent. Amplitude normalization, framing and windowing steps are applied in the preprocessing stage. Signals obtained after preprocessing are decomposed into different levels using appropriate transforms. Energy and statistical measurements are extracted from the details and approximation coefficients of each level. Optimal features are selected. Normalization is used to bring all the features to the same scale before they are fed to the classifier. This process standardizes the dataset. After normalizing the training data, the minimum and maximum values of each feature are used to normalize the test data. After the training and testing phases, the decision phase starts (Gidaye et al., 2020). The transforms, selected features and classifier used are very important in terms of the specificity and accuracy of the system. Since an algorithm that can be accepted as a standard has not been established yet, studies in this area are continuing.

Interventional Diagnostic Methods

With the electromyography (EMG) of the intrinsic and extrinsic laryngeal muscles, RLN and/or SLN injuries can be diagnosed and prognostic information can be provided. However, this diagnostic method is rarely used in clinical practice due to the invasive nature of the procedure. The main muscles to be evaluated in this method are the cricothyroid and thyroarytenoid muscles. Electrical models are analyzed for their spontaneous and evoked potentials. The first sign of denervation after injury is electrical silence. Fibrillation potentials and sharp positive waves appear after about 10 days and remain silent indefinitely if there is no regrowth (Min et al., 1994). Reinnervation begins at least two months after damage to motor units and may last more than a year. In the first six months, 60% of patients with action potential induced by voluntary activity regain laryngeal motility. However, after six months, the prognostic value of EMG decreases as the correlation between the EMG signal and function differs. Fiber optic flexible endoscopy, another diagnostic tool used in patients with dysphonia, allows for the excellent visualization of the vocal cords and observation of patients who perform breathing and phonation exercises (Lynch & Parameswaran, 2017). In addition, another diagnostic method, laryngeal electromyography, is the gold standard method for the diagnosis of injury in the presence of EBSLN injury suspicion (Sulica, 2004).

METHODS OF PROTECTION FROM LARYNGEAL NERVE INJURY

If there are findings suggestive of vocal cord abnormality in the examination of patients and if they have previously undergone cervical surgery, to prevent RLN damage, the examination of the vocal cords should be performed to detect laryngeal dysfunction caused by previous surgery. In a previous study, 761 patients with 365 RLNs at risk of injury underwent systematic preoperative and postoperative laryngoscopy. At the end of the study, it was shown that 20% of patients with postoperative laryngeal dysfunction had either a change in the vocal cord (18%) or RLN damage (1.8%) preoperatively (Echternach et al., 2009). In addition to the preoperative examination of the vocal cords, it is necessary to carefully

dissect RLN, avoid excessive traction, and choose a reasonable hemostatic technique during the operation (Richer & Randolph, 2009).

Laryngeal dysfunction is not always due to RLN damage. Vocal cord trauma from the endotracheal tube, mucosal erosion, edema, or subluxation of the arytenoid cartilage (0.4-3% of cases) may also cause dysphonia (Lang et al., 2016). When difficulties in endotracheal intubation are foreseen in cases of tracheal compression or deviation due to patient anatomy, such as a short neck and a large goiter, intubation should be performed under the guidance of fiberoptic imaging (Laccourreye et al., 2009).

Surgical Laryngeal Nerve Anatomy

In the development process of surgery, a thorough understanding of the thyroid and parathyroid is the most important factor in increasing the safety and efficacy of thyroid surgery (Mohebati & Shaha, 2012). Since RLN and EBSLN, which are affected during thyroid surgery, are the motor and sensory nerves of the larynx, damage to these nerves leads to life-threatening consequences in larynx functions. Functionally, the larynx is a sphincter that closes during swallowing, protecting the airway and allowing for phonation (Negus, 1957). The motor and sensory innervation of the larynx originates from RLN and SLN branching from the nervus vagus. SLN arises from the vagal ganglion and receives a branch from the superior cervical sympathetic ganglion. It descends along the pharynx and divides into internal and external laryngeal nerves. The sensation of the larynx mucosa up to the level of the vocal cord is provided by the internal laryngeal nerve. The outer branch of SLN innervates the cricothyroid muscle, which has an important function in phonation at high frequencies (Sakorafas et al., 2012).

Recurrent Laryngeal Nerve Anatomy

The course of RLN is anterior to the aortic arches. During embryonic development, RLNs are pulled down by the aortic arch as the heart and great vessels descend and the neck lengthens. The right RLN recurs around the fourth arch, the right subclavian artery, while the left recurs around the sixth arch, the ligamentum arteriosum (Langman & Sadler, 1990). During thyroid surgery, RLN is classically defined based on the Simon triangle formed by the esophagus medially, the carotid artery laterally, and the inferior thyroid artery superiorly (Simon, 1943). As the right RLN curves around the right

subclavian artery, it enters the base of the neck in a more lateral position and its course is less predictable than the left RLN (Hunt et al., 1968). The length of the left RLN from the aorta to the cricothyroid joint is approximately 12 cm, while that of the right RLN from the subclavian joint to the cricothyroid joint is approximately 5-6 cm (Weisberg et al., 1997).

RLN has both motor and sensory components and innervates the intrinsic muscles of the larynx. Although RLN provides the sensory innervation of the glottic larynx, it divides into inner branches that provide motor function for the four intrinsic laryngeal muscles other than the cricothyroid muscle, an outer branch, vocal cords, and sensation to the subglottic region (Ardito et al., 2004). RLN in the neck is supplied by branches of the inferior thyroidal artery (ITA), which supplies the trachea and part of the esophagus, while its distal part is supplied by a branch of the inferior laryngeal artery (Monfared et al., 2002). Studies have concluded that it may be more reliable to identify the nerve from the distal, and this can also reduce the risk of disrupting the blood flow to RLN (Mohebati & Shaha, 2012).

In a study conducted by Nemiroff et al., a total of 153 RLN variations were observed, of which 41.2% were divided into the extralaryngeal branches of different sizes (Nemiroff & Katz, 1982). In another study in the literature, of the 1,177 RLNs examined in 719 patients, 63% were bifurcated or tripartite 0.5 cm below the cricoid cartilage. A total of 170 patients were reported to have bilateral nerve bifurcation (Katz & Nemiroff, 1993). Yalçın reported that he observed 20 different configurations according to the location of the main body of RLN and its branches entering the larynx. He also noted that while RLN was mostly anterior to the artery on the right, it was often behind two branches of the artery on the left (Yalçin, 2006).

In a study by Lekacos et al., which included 172 thyroidectomy cases, 191 RLNs were defined, and it was stated that 82.6% of the left RLNs and 85.4% of the right RLNs were either posterior to or between the branches of the inferior thyroidal artery, with only a small percentage of these nerves being anterior to the artery. Most of the nerves were found within 3 mm of the Berry ligament. As a result of the study, the authors concluded that the relationship of RLN with ITA and the Berry ligament did not follow a fixed anatomical pattern (Lekacos et al., 1992). In a cadaver study conducted by

Leow and Webb at the level of the cricoid cartilage, the mean distance between the attachment of the Berry ligament to the cricoid cartilage and the entry point of RLN to the larynx was determined as 1.9 mm (Leow & Webb, 1998).

The Zukerkandl tubercle is a critical anatomical point that can be useful in identifying RLN. In a study of 104 lobectomies by Pelizzo et al., the Zukerkandl tubercle was detected in 78.2% of the patients that underwent right lobectomies and 75.5% of those that underwent left lobectomies. The authors concluded that the identification of this tubercle would facilitate the detection of RLN (Pelizzo et al., 1998).

Non-Recurrent Nerve Anatomy

During embryological development, when a segment of the fourth right aortic arch is lost between the right common carotid and the right subclavian, this results in a break in the primitive arterial rings. A fracture in the ring causes the left aortic arch to form and the right subclavian artery to protrude under the left subclavian artery (Langman & Sadler, 1990). Due to this abnormal origin, the right subclavian artery must cross the midline behind the esophagus to reach the right arm (Myssiorek, 2004), Leading to esophageal compression and dysphagia. As a result of this atresia, there is no innominate artery under which the right RLN can recur to rise above the neck; therefore, the right RLN originates from the vagus in the cervical region (Randolph, 2020; Sanders et al., 1983).

Henry et al. observed 31 cases of right non-recurrent laryngeal nerve in 4,921 dissections (0.63%). In addition, two (0.04%) of 4,673 dissections describe a left-sided non-recurrent laryngeal nerve; however, the authors stated that both patients had a right aortic arch associated with situs inversus (Henry et al., 1988). In the literature, it is reported that the preoperative diagnosis of non-recurrent laryngeal nerve can be made by defining an abnormal right subclavian artery or “arteria lusoria” using ultrasonography and computed tomography. It is stated that this preoperative diagnosis may be beneficial for operation planning (Iacobone et al., 2008; Wang et al., 2011).

Another pitfall during thyroid surgery concerns the branches of communication between the cervical sympathetic nervous system and RLN. These branches may arise from the middle cervical chain ganglion and the

lower cervical chain ganglion. In a series of 656 right-sided dissection, it was reported that the rate of anastomotic branches between the sympathetic nervous system and the non-recurrent laryngeal nerve was 0.45% and the rate of those between the sympathetic nervous system and RLN was 1.5%. Although these sympathetic branches may be similar in diameter to RLN, they may be confused with the non-recurrent laryngeal nerve during thyroid surgery and neck dissection (Raffaelli et al., 2000).

Superior Laryngeal Nerve Anatomy

EBSLN sends motor fibers to the cricothyroid muscle and innervates portions of the laryngeal mucous membrane (Moran & Castro, 1951). It has been reported that the risk of injury to EBSLN during thyroidectomy is 37-72% (Hurtado-Lopez & Zaldivar-Ramírez, 2002). SLN is one of the first branches of the vagus that departs from the carotid bifurcation at approximately 4 cm of the nodose ganglion and descends posterior and medial to the carotid sheath (Randolph, 2020). During this descent, it passes in front of the superior sympathetic cervical ganglion (Monfared et al., 2002) and divides into internal and external branches approximately 1.5 cm below the ganglion (Randolph, 2020).

Understanding the relationship between EBSLN and the upper thyroid pole and STA is crucial for the preservation of this nerve during surgery (88). EBSLN almost always approaches the larynx through the sternothyrolaryngeal (Joll's) triangle. The borders of this triangle are the lower laryngeal constrictor and cricothyroid muscle medially, the sternothyroid muscle anteriorly, and the upper thyroid pole anteriorly (Randolph, 2020). In a study by Kierner et al., it is reported that EBSLN passes STA 1 cm above the upper pole of the thyroid gland in 42% of cases, 1 cm near the upper pole in 30%, and under the upper pole or just above the upper pole of the thyroid gland in 28% (Kierner et al., 1998). In another study by Cernea et al., it was reported that 60% of EBSLNs were detected 1 cm above the thyroid upper pole in 15 cadavers, 17% were less than 1 cm above the upper pole, and 20% were crossing the vessels below the thyroid upper pole (Cernea et al., 1992).

The inner branch of the superior laryngeal nerve (IBSLN), together with STA, pierces the thyrohyoid membrane and provides the sensory innervation of the laryngeal mucosa. IBSLN is divided into three divisions:

upper, middle and lower (Sulica, 2004). The upper section supplies the mucous membrane of the laryngeal surface of the epiglottis, the middle section supplies the mucosa of the true and false vocal cords and the aryepiglottic fold, and the lower section supplies the mucosa of the arytenoid region, subglottis, anterior wall of the hypopharynx, and upper esophageal sphincter (Sanders & Mu, 1998). It has been suggested that some fibers of IBSLN provide motor innervation for the interarytenoid muscle (Wu et al., 1994).

Use of Neuromonitoring for Protection from Laryngeal Nerve Injury

The precise role of intraoperative neuromonitoring in RLN preservation in thyroidectomies remains unclear. This technology was first developed in the 1960s to allow for the intraoperative evaluation of nerve integrity and predict postoperative vocal cord mobility (Flisberg & Lindholm, 1969). Neuromonitoring is also used to elucidate the mechanisms of postoperative RLN damage (Chiang et al., 2010).

In a prospective series of 447 patients in the literature, it was reported that the use of neuromonitoring had a 40% positive predictive value and 100% negative predictive value, with 63% sensitivity and 97% specificity for nerve damage (Cernea et al., 2012). In a study by Barczynski et al. evaluating 1,000 patients, standard RLN dissection and RLN dissection with neuromonitoring were compared, and the latter was shown to reduce the incidence of transient RLN paresis. In the same study, the incidence of paresis was found to be 2.9% for high-risk patients and 0.9% for low-risk patients (Barczyński et al., 2009). In a meta-analysis by Higgins et al. that included seven randomized and comparative studies, the rate of RLN damage was 3.25% when neuromonitoring was used, compared to 3.12% for nerve visualization. The authors concluded that the best technique to prevent nerve injury was still the visualization of RLN (Higgins et al., 2011). In another study, Alesina PF et al. reported that the use of neuromonitoring did not reduce the risk of RLN damage in cases of recurrent thyroidectomy (Alesina et al., 2012).

Although the use of neuromonitoring has a long learning curve in the literature, it has been reported that it changes the surgeon's nerve dissection technique (Abboud et al., 1999) and helps identify the nerve, even if the nerve

is not classically recurrent (the incidence of non-recurrent laryngeal nerve may be as high as 6%) (Brauckhoff et al., 2011; Donatini et al., 2013; Duclos et al., 2011). A recent meta-analysis compared neuromonitoring versus dissection alone in six randomized controlled trials involving a total of 1,602 patients and 3,064 RLNs. This meta-analysis reported no statistically significant reduction in the risk of RLN damage with the use of neuromonitoring, but there was a reduction in EBSLN injury (Sanabria et al., 2013). However, it is also suggested that the use of neuromonitoring can help surgeons with less experience during thyroidectomy (Dralle et al., 2008; Hermann et al., 2004); thus, it can contribute to the improvement of surgeons' RLN dissection performance. Another benefit of neuromonitoring is its value in predicting normal postoperative cord function. The positive predictive value and sensitivity of neuromonitoring in the presence of a normal signal have been reported as 11.6% and 45.9%, respectively (Thomusch et al., 2004).

Appropriate Surgical Technique for Protection from Laryngeal Nerve Injury

RLN can be damaged through a variety of mechanisms, including stretching, crushing, thermal injury, electrical injury, and transection (Affleck et al., 2003). The surgical technique is important in preventing injury, and studies initiated by Hague and Hoover in the 1930s for the identification and dissection of RLN continue (Lahey & Hoover, 1938). To achieve hemostasis during thyroidectomy, hemostasis techniques have been enriched with classical clamp and ligature techniques, metallic clips, and newer modalities, such as monopolar or bipolar electrocautery, thermofusion, and ultrasonic hemostasis. In the literature, two meta-analyses have been undertaken to compare traditional hemostasis techniques with thermofusion (Yao et al., 2009) and ultrasound (Ecker et al., 2010) techniques in terms of the incidence of RLN damage during thyroidectomy. As a result of the meta-analysis, although the incidence of RLN damage for traditional and new modalities was similar, it was found to be 2.5% for temporary nerve damage and 0.5% for permanent nerve damage. Energy devices are generally reported to be safe to use, as these devices operate at low temperatures and have minimal lateral thermal dissipation (Hoenig et al., 1996). In a recent study, Thunderbeat was used on a pig model, and the results indicated that the device could be safely

used up to 3 mm from RLN but for less than 8 seconds in closer positions (Kwak et al., 2016).

Three techniques have been described for the dissection of RLN: lateral approach (defines RLN in its middle part), inferior approach (defines RLN at the exit level from the rib cage), and upper approach (defines RLN at the entrance level to the larynx). The advantage of the lateral approach is that surgeons are familiar with this approach and RLN is protected by Berry's suspensory ligament. The disadvantage is that the extralaryngeal branches of the RLN are usually distant and pose risks for reoperative surgery. The advantage of the latter method is that it provides an easy approach to RLN for reoperative thyroidectomy and allows for the nerve to be identified and isolated before branching. The disadvantage is that it requires the dissection of RLN over a long distance and increases the risk of nerve devascularization. It also increases the risk of devascularization of the inferior parathyroid glands. The upper approach is indicated for patients with a large volume or substernal goiter. The most stable anatomical localization facilitates the identification of the anterior branch of RLN and SLN. The disadvantage of the upper approach is that dissection is sometimes difficult due to possible adhesions between RLN and the suspensory ligament of Berry. The most common technique used by surgeons is the lateral approach, while the lower approach (detecting the nerve below the level of the thyroid gland) may be safer if neck exploration has been previously undertaken,. All three define RLN systematically and significantly reduce damage to the nerve (Lahey & Hoover, 1938).

Future Technologies in Nerve Protection

Fluorescently labeled markers that will provide complete nerve preservation in future are promising for the development of surgical techniques (Nguyen & Tsien, 2013). Indocyanine green (van der Vorst et al., 2012) and fluorescein sodium are the only probes currently used in the intraoperative setting (Gurtner et al., 2013). In their experimental models, Cotero VE et al. reported that GE3111 fluorescence showed the nerves very clearly (Cotero et al., 2012). However, to date, no study has been conducted to evaluate these techniques for thyroid surgery.

TREATMENT MODALITIES IN DYSPHONIA

Spontaneous Recovery

Recovery in patients with RLN damage without nerve incision after thyroidectomy is adversely affected by factors such as age, diabetes, smoking, and systemic disease (Affleck et al., 2003). The spontaneous recovery of nerve function and axonal regrowth are reported to be worse in elderly patients, smokers, diabetics, and patients with severe comorbidities compared to those without these conditions (Hartl et al., 2005).

Voice Therapy

In a seven-year study on 74 patients with unilateral vocal fold paralysis who followed a specific vocal exercise program, it was reported that 68.9% regained vocal fold motility (Mattioli et al., 2011). Similarly, other studies show an improvement in objective and subjective assessment of vocal quality and an increased rate of glottic closure. Patients with minor glottic insufficiency (<1 mm in phonation) without major symptoms are good candidates for vocal cord augmentation using speech therapy (D'Alatri et al., 2008; Schindler et al., 2008).

Approach to Unilateral RLN Damage

Unilateral RLN damage may present with minimal symptoms, and therefore the visualization of vocal cord function should be performed postoperatively systematically, even in the absence of dysphonia. It is recommended that the treatment should be symptomatic and the patient is referred to an otolaryngologist after diagnosis (Hartl et al., 2005; Rubin & Sataloff, 2008). First, the patient's tolerance and the effects of nerve palsy on the patient's quality of life, respiratory function and phonation should be evaluated (de Roy van Zuidewijn et al., 1995). The spontaneous recovery of vocal function by nerve regeneration or contralateral vocal cord compensation is possible for up to 12 months postoperatively, even if milder functional impairment persists. Emergency response should be reserved for patients at risk of severe aspiration or who poorly tolerate dysphonia (Hartl et al., 2005).

Approach to Bilateral RLN Nerve Injury

In bilateral vocal fold paralysis, the vocal cords are adducted. Clinically, patients present with bilateral vocal fold paralysis present with acute dyspnea and dyspnea during extubation. The first step is to maintain and reapply ventilation through the reintubation of the patient for emergency airway management. In addition, high-dose corticosteroid therapy is administered for 48 hours to reduce laryngeal edema. In this treatment, 20 to 60 mg solumedrol or 4 to 10 mg dexamethasone daily is administered through a slow intravenous infusion for 30 minutes every eight to 12 hours. In addition to corticotherapy, broad-spectrum antibiotics and proton pump inhibitors should be given. In the literature, it is stated that this treatment reduces the risk of laryngeal granuloma formation (Dispenza et al., 2012). The removal of the endotracheal tube should be performed in the operating room under laryngoscopic control.

Approach to Superior Laryngeal Nerve Injury

EBSLN is very close to the thyroid vessels in the upper pole and is seen during surgery in only 2.5-10% of cases. This nerve innervates the cricothyroid muscle, which stretches the vocal cords. In 0.4-3% of thyroidectomies, injury to this nerve causes a decrease in the stretching ability of the vocal cord and a decrease in vocal power and the ability to sing at higher pitches (Hartl et al., 2005). In most cases, these problems regress within a month, through cross-innervation from the other branches of the ansa hypoglossi that anastomose with the upper and lower laryngeal nerves (Migueis et al., 1989). Voice re-education and administration of aerosolized corticosteroids may be of some benefit (Laccourreye et al., 2009).

Surgical Treatment Methods in Dysphonia

Tracheostomy is required in cases of persistent vocal cord paralysis and severe dyspnea after thyroidectomy. The aim of long-term treatment is to restore the vocal cord and swallowing function after the removal of the tracheostomy at the end of treatment, as well as to provide the patient with a satisfactory quality of life. Although the spontaneous recovery of vocal cord mobility is unusual, recovery has been reported 12 months after surgery (Dispenza et al., 2012).

If the patient exhibits signs of unsafe swallowing, immediate intervention is required to reduce the risk of aspiration pneumonia. The chin tilt technique is useful in situations where aspiration has occurred. The risk of aspiration can be reduced by enlarging the vocal cord with temporary injections for the first few months. Definitive treatment is usually delayed for six to 12 months to allow time for the re-innervation of RLN. Early medialization procedures may result in vocal cord atrophy due to continued RLN degeneration and consequently lead to glottal regurgitation. However, EMG evidence revealing severe neuronal degeneration with no history of complete nerve severing or evidence of recovery suggests the need for medialization procedures within three to nine months (Rosen & Simpson, 2008).

Surgical options can be categorized as vocal cord augmentation by a temporary or permanent injection, laryngeal framework surgery to medialize and improve vocal cord mechanical functionality (either by an external approach with an implant or by traction on the arytenoid), and reinnervation (Lynch & Parameswaran, 2017).

Posterior vocal cord resection and arytenoidectomy, which are surgical treatment options for bilateral vocal cord paralysis, provide a space for air passage and respiratory function at the expense of temporary aspiration and severe vocal sequelae during swallowing (Dispenza et al., 2012).

Vocal Cord Injection Strengthening Method

Vocal cord strengthening is a minimally invasive procedure consisting of a lateral injection into the thyroarytenoid muscle in the paraglottic space to restore glottic competence (Rosen & Simpson, 2008). Injection is effective in eliminating the risk of aspiration and improving voice quality (Hartl et al., 2001; Mallur & Rosen, 2010). Vocal cord strengthening can be performed within the first six months after RLN damage. Many studies suggest that early injection (within the first three months) can avoid laryngoplasty (Alghonaim et al., 2013; Friedman et al., 2010). The objective markers of voice improvement increase with an early injection (Prendes et al., 2012). The complications of this procedure are rare, with the most common being infection or hematoma at the injection site (Mathison et al., 2009).

Medialization Laryngoplasty Method

Medialization laryngoplasty (type I thyroplasty) involves opening a window in the thyroid ala cartilage to place an implant to permanently medialize the vocal cord. It is the gold standard method for the permanent treatment of patients with vocal cord paralysis and paresis (Payr, 1915). Ideal candidates for surgery are those with moderate to severe glottic insufficiency (more than 2 mm in phonation), weak breathing dysphonia, and dysphagia. Patients with minor glottic insufficiency (<1 mm in phonation) without major symptoms are likely to be better candidates for vocal cord reinforcement with an injection or speech therapy. Contraindications include prior radiation surgery to the larynx, underlying malignant disease, and poor abduction of the contralateral fold (Lynch & Parameswaran, 2017).

The formation of a permanent posterior glottic space, inadequate medialization, and improper sizing or misplacement of the implant can lead to poor surgical outcomes (Hartl et al., 2001). Other rare complications that can be seen include airway obstruction (13.8%), shortness of breath due to the development of hematoma or edema, and extrusion or migration of the implant (0.8%) (Lynch & Parameswaran, 2017).

Arytenoid Adduction Method

Arytenoid adduction acts through direct traction on the arytenoid cartilage in the muscle process (using a suture). The aim is to improve closure of the posterior glottis by placing the vocal process in a more natural position (Hess et al., 2011). It can often be used in conjunction with laryngoplasty and injection to achieve better posterior vocal closure in selected patients. The disadvantages of the combined procedure include the need for greater dissection, a longer operative time, and the risk of reducing the size of the glottic airway to an unhealthy degree during inspiration. In a systematic review of the literature, Chester and Stewart found the combined approach to be of only little use (Chester & Stewart, 2003). In the literature, it is suggested that there is a slight improvement in symptoms and a higher risk of complications with the combined technique (Abraham et al., 2002; McCulloch et al., 2000).

Cricothyroid Subluxation Method

Cricothyroid subluxation aims to resolve the problem of shortened vocal cords. Zeitels et al. suggested that the vocal range was limited by a loose denervated cord (Zeitels et al., 1999) and recommended increasing the distance from the cricoarytenoid joint to the anterior commissure of the thyroid cartilage by subluxing the cricothyroid joint on the side of the cord palsy. This causes the anterior commissure to rotate in the opposite direction from the midline to the side of the cord paralysis, providing additional length for the cord. Although this method is occasionally performed with arytenoid adduction, medialization can also be performed together with laryngoplasty.

Reinnervation Procedures

Although normal function is unlikely to return due to synkinesis in reinnervation procedures, dysphonic voice due to damaged RLN can be improved in tone and strength. Using the reinnervation method allows for the better medialization of the vocal cord position and prevents the progressive atrophy of the thyroarytenoid muscle. In addition, it provides the opportunity to perform larynx surgery in future, and it can also eliminate the need for implants.

Different methods are available to re-innervate RLN. Techniques used to repair the nerve in the case of a transection injury are primary end-to-end anastomosis, ansa cervicalis-to-RLN anastomosis, and primary interposition graft. However, when there is a gap larger than 5 mm, grafts can be taken from the ansa cervicalis, transverse cervical nerve or supraclavicular nerve (Sanuki et al., 2010). Techniques in which the ansa cervicalis is used are mostly preferred (Zheng et al., 1996). It is stated that the primary transposition of the ansa cervicalis to the distal RLN should be considered in cases where a part of the nerve needs to be removed for oncological reasons (Dzodic et al., 2016). Case series show generally favorable outcomes with reinnervation procedures (Lee et al., 2007; Lorenz et al., 2008). Zabrodsky et al. reported that in cases where they performed the immediate revision of suspected bilateral RLN damage with anastomosis, none of the anastomized nerves regained their function, but a good muscle tone was observed (Zábrodský et al., 2012).

In a multicenter randomized controlled study evaluating medialization versus reinnervation surgery, Paniello RC et al. reported that there was no significant difference between the groups in terms of general symptoms at 12 months, but symptoms improved in the reinnervation group compared to the medialization group in patients younger than 55 years old (Paniello et al., 2011).

CONCLUSION

In patients who are planned to undergo thyroidectomy, first, the vocal cords should be evaluated preoperatively using the mirror or fiberoptic laryngoscopy method. The risk factors and comorbidities of patients for dysphonia should be reviewed. It seems imperative that the surgeon who will perform thyroidectomy has a good knowledge of anatomy. The specialist who will administer anesthesia to the patient should determine the anatomically difficult cases in detail and use appropriate technological support and methods. During surgery, thermal injury should be avoided and devices with modern technology should be used. The visualization of nerves during thyroidectomy is the most reliable method of avoiding damage, and intraoperative neuromonitoring should be used in recurrent cases and if the surgeon has less experience. Intraoperative neuromonitoring may be beneficial in high-risk patients (such as patients undergoing reoperative procedures or those with abnormal anatomy), but there is no strong evidence for the routine use of this method. Fluorescence-guided surgery techniques using myelin-specific agents, which are still in the experimental stage, may be a valuable option in future for the better visualization and preservation of nerves.

Although various indices are used in the diagnosis and evaluation of dysphonia, intensive studies are continuing on software that makes sound quality measurement and evaluation in the frequency-time interval in order to make more objective evaluations and predictions. While there is a lack of evidence for the positive effects of voice therapy techniques in dysphonic patients, it is considered that this therapy, at least, does not impede recovery. It seems likely that an early injection into the vocal cords will result in a better prognosis and it will reduce the incidence of frame surgery requirement. It is stated that an early injection is beneficial in the management of dyspnea

caused by fluid aspiration due to vocal cord paralysis. Laryngoplasty and arytenoid adduction are effective and can be complementary. Cricothyroid subluxation is a new procedure whose role has not yet been clearly defined. Reinnervation procedures require specialist skills but appear to be effective.

REFERENCES

Abadin, S. S., Kaplan, E. L., & Angelos, P. (2010). Malpractice litigation after thyroid surgery: the role of recurrent laryngeal nerve injuries, 1989-2009. Surgery, 148(4), 718-722; discussion 722-713.

Abboud, B., Tabchy, B., Jambart, S., Hamad, W. A., & Farah, P. (1999). Benign disease of the thyroid gland and vocal fold paralysis. J Laryngol Otol, 113(5), 473-474.

Abraham, M. T., Bains, M. S., Downey, R. J., Korst, R. J., & Kraus, D. H. (2002). Type I thyroplasty for acute unilateral vocal fold paralysis following intrathoracic surgery. Ann Otol Rhinol Laryngol, 111(8), 667-671.

Acun, Z., Cihan, A., Ulukent, S. C., Comert, M., Ucan, B., Cakmak, G. K., & Cesur, A. (2004). A randomized prospective study of complications between general surgery residents and attending surgeons in near-total thyroidectomies. Surg Today, 34(12), 997-1001.

Affleck, B. D., Swartz, K., & Brennan, J. (2003). Surgical considerations and controversies in thyroid and parathyroid surgery. Otolaryngol Clin North Am, 36(1), 159-187, x.

Akyildiz, S., Ogut, F., Akyildiz, M., & Engin, E. Z. (2008). A multivariate analysis of objective voice changes after thyroidectomy without laryngeal nerve injury. Arch Otolaryngol Head Neck Surg, 134(6), 596-602.

Alesina, P. F., Rolfs, T., Hommeltenberg, S., Hinrichs, J., Meier, B., Mohmand, W., Hofmeister, S., & Walz, M. K. (2012). Intraoperative neuromonitoring does not reduce the incidence of recurrent laryngeal nerve palsy in thyroid reoperations: results of a retrospective comparative analysis. World J Surg, 36(6), 1348-1353.

Alghonaim, Y., Roskies, M., Kost, K., & Young, J. (2013). Evaluating the timing of injection laryngoplasty for vocal fold paralysis in an attempt to avoid future type 1 thyroplasty. J Otolaryngol Head Neck Surg, 42(1), 24.

Ardito, G., Revelli, L., D'Alatri, L., Lerro, V., Guidi, M. L., & Ardito, F. (2004). Revisited anatomy of the recurrent laryngeal nerves. Am J Surg, 187(2), 249-253.

Balentine, C. J., & Sippel, R. S. (2016). Outpatient Thyroidectomy: Is it Safe? Surg Oncol Clin N Am, 25(1), 61-75.

Barczyński, M., Konturek, A., & Cichoń, S. (2009). Randomized clinical trial of visualization versus neuromonitoring of recurrent laryngeal nerves during thyroidectomy. Br J Surg, 96(3), 240-246.

Bergenfelz, A., Jansson, S., Kristoffersson, A., Mårtensson, H., Reihnér, E., Wallin, G., & Lausen, I. (2008). Complications to thyroid surgery: results as reported

in a database from a multicenter audit comprising 3,660 patients. Langenbecks Arch Surg, 393(5), 667-673.

Bhattacharyya, N., & Fried, M. P. (2002). Assessment of the morbidity and complications of total thyroidectomy. Arch Otolaryngol Head Neck Surg, 128(4), 389-392.

Brauckhoff, M., Machens, A., Sekulla, C., Lorenz, K., & Dralle, H. (2011). Latencies shorter than 3.5 ms after vagus nerve stimulation signify a nonrecurrent inferior laryngeal nerve before dissection. Ann Surg, 253(6), 1172-1177.

Caulley, L., Johnson-Obaseki, S., Luo, L., & Javidnia, H. (2017). Risk factors for postoperative complications in total thyroidectomy: A retrospective, risk-adjusted analysis from the National Surgical Quality Improvement Program. Medicine (Baltimore), 96(5), e5752.

Cernea, C. R., Brandão, L. G., Hojaij, F. C., De Carlucci, D., Jr., Brandão, J., Cavalheiro, B., & Sondermann, A. (2012). Negative and positive predictive values of nerve monitoring in thyroidectomy. Head Neck, 34(2), 175-179.

Cernea, C. R., Ferraz, A. R., Nishio, S., Dutra, A., Jr., Hojaij, F. C., & dos Santos, L. R. (1992). Surgical anatomy of the external branch of the superior laryngeal nerve. Head Neck, 14(5), 380-383.

Cernea, C. R., Hojaij, F. C., De Carlucci, D., Jr., Gotoda, R., Plopper, C., Vanderlei, F., & Brandão, L. G. (2009). Recurrent laryngeal nerve: a plexus rather than a nerve? Arch Otolaryngol Head Neck Surg, 135(11), 1098-1102.

Chan, W. F., Lang, B. H., & Lo, C. Y. (2006). The role of intraoperative neuromonitoring of recurrent laryngeal nerve during thyroidectomy: a comparative study on 1000 nerves at risk. Surgery, 140(6), 866-872; discussion 872-863.

Chester, M. W., & Stewart, M. G. (2003). Arytenoid adduction combined with medialization thyroplasty: an evidence-based review. Otolaryngol Head Neck Surg, 129(4), 305-310.

Chiang, F. Y., Lee, K. W., Chen, H. C., Chen, H. Y., Lu, I. C., Kuo, W. R., Hsieh, M. C., & Wu, C. W. (2010). Standardization of intraoperative neuromonitoring of recurrent laryngeal nerve in thyroid operation. World J Surg, 34(2), 223-229.

Christou, N., & Mathonnet, M. (2013). Complications after total thyroidectomy. J Visc Surg, 150(4), 249-256.

Cotero, V. E., Siclovan, T., Zhang, R., Carter, R. L., Bajaj, A., LaPlante, N. E., Kim, E., Gray, D., Staudinger, V. P., Yazdanfar, S., & Tan Hehir, C. A. (2012). Intraoperative fluorescence imaging of peripheral and central nerves through a myelin-selective contrast agent. Mol Imaging Biol, 14(6), 708-717.

D'Alatri, L., Galla, S., Rigante, M., Antonelli, O., Buldrini, S., & Marchese, M. R. (2008). Role of early voice therapy in patients affected by unilateral vocal fold paralysis. J Laryngol Otol, 122(9), 936-941.

Dackiw, A. P., Rotstein, L. E., & Clark, O. H. (2002). Computer-assisted evoked electromyography with stimulating surgical instruments for recurrent/external laryngeal nerve identification and preservation in thyroid and parathyroid operation. Surgery, 132(6), 1100-1106; discussion 1107-1108.

de Roy van Zuidewijn, D. B., Songun, I., Kievit, J., & van de Velde, C. J. (1995). Complications of thyroid surgery. Ann Surg Oncol, 2(1), 56-60.

Debruyne, F., Ostyn, F., Delaere, P., & Wellens, W. (1997). Acoustic analysis of the speaking voice after thyroidectomy. J Voice, 11(4), 479-482.

Dispenza, F., Dispenza, C., Marchese, D., Kulamarva, G., & Saraniti, C. (2012). Treatment of bilateral vocal cord paralysis following permanent recurrent laryngeal nerve injury. Am J Otolaryngol, 33(3), 285-288.

Donatini, G., Carnaille, B., & Dionigi, G. (2013). Increased detection of non-recurrent inferior laryngeal nerve (NRLN) during thyroid surgery using systematic intraoperative neuromonitoring (IONM). World J Surg, 37(1), 91-93.

Doran, H. E., England, J., & Palazzo, F. (2012). Questionable safety of thyroid surgery with same day discharge. Ann R Coll Surg Engl, 94(8), 543-547.

Dralle, H., Sekulla, C., Haerting, J., Timmermann, W., Neumann, H. J., Kruse, E., Grond, S., Mühlig, H. P., Richter, C., Voss, J., Thomusch, O., Lippert, H., Gastinger, I., Brauckhoff, M., & Gimm, O. (2004). Risk factors of paralysis and functional outcome after recurrent laryngeal nerve monitoring in thyroid surgery. Surgery, 136(6), 1310-1322.

Dralle, H., Sekulla, C., Lorenz, K., Brauckhoff, M., & Machens, A. (2008). Intraoperative monitoring of the recurrent laryngeal nerve in thyroid surgery. World J Surg, 32(7), 1358-1366.

Duclos, A., Lifante, J. C., Ducarroz, S., Soardo, P., Colin, C., & Peix, J. L. (2011). Influence of intraoperative neuromonitoring on surgeons' technique during thyroidectomy. World J Surg, 35(4), 773-778.

Duclos, A., Peix, J. L., Colin, C., Kraimps, J. L., Menegaux, F., Pattou, F., Sebag, F., Touzet, S., Bourdy, S., Voirin, N., & Lifante, J. C. (2012). Influence of experience on performance of individual surgeons in thyroid surgery: prospective cross sectional multicentre study. Bmj, 344, d8041.

Duclos, A., Voirin, N., Touzet, S., Soardo, P., Schott, A. M., Colin, C., Peix, J. L., & Lifante, J. C. (2010). Crude versus case-mix-adjusted control charts for safety monitoring in thyroid surgery. Qual Saf Health Care, 19(6), e17.

Dzodic, R., Markovic, I., Santrac, N., Buta, M., Djurisic, I., & Lukic, S. (2016). Recurrent Laryngeal Nerve Liberations and Reconstructions: A Single Institution Experience. World J Surg, 40(3), 644-651.

Echternach, M., Maurer, C. A., Mencke, T., Schilling, M., Verse, T., & Richter, B. (2009). Laryngeal complications after thyroidectomy: is it always the surgeon? Arch Surg, 144(2), 149-153; discussion 153.

Ecker, T., Carvalho, A. L., Choe, J. H., Walosek, G., & Preuss, K. J. (2010). Hemostasis in thyroid surgery: harmonic scalpel versus other techniques--a meta-analysis. Otolaryngol Head Neck Surg, 143(1), 17-25.

Flint, P. W., Downs, D. H., & Coltrera, M. D. (1991). Laryngeal synkinesis following reinnervation in the rat. Neuroanatomic and physiologic study using retrograde fluorescent tracers and electromyography. Ann Otol Rhinol Laryngol, 100(10), 797-806.

Flisberg, K., & Lindholm, T. (1969). Electrical stimulation of the human recurrent laryngeal nerve during thyroid operation. Acta Otolaryngol Suppl, 263, 63-67.

Flynn, M. B., Lyons, K. J., Tarter, J. W., & Ragsdale, T. L. (1994). Local complications after surgical resection for thyroid carcinoma. Am J Surg, 168(5), 404-407.

Friedman, A. D., Burns, J. A., Heaton, J. T., & Zeitels, S. M. (2010). Early versus late injection medialization for unilateral vocal cord paralysis. Laryngoscope, 120(10), 2042-2046.

Gidaye, G., Nirmal, J., Ezzine, K., & Frikha, M. (2020). Wavelet sub-band features for voice disorder detection and classification. Multimedia Tools and Applications, 79(39), 28499-28523.

Goldfarb, M., Perry, Z., R, A. H., & Parangi, S. (2011). Medical and surgical risks in thyroid surgery: lessons from the NSQIP. Ann Surg Oncol, 18(13), 3551-3558.

Gurtner, G. C., Jones, G. E., Neligan, P. C., Newman, M. I., Phillips, B. T., Sacks, J. M., & Zenn, M. R. (2013). Intraoperative laser angiography using the SPY system: review of the literature and recommendations for use. Ann Surg Innov Res, 7(1), 1.

Hanbury, E. M., Jr., & Boyd, D. P. (1963). HISTORY OF THYROID SURGERY. Surgery, 54, 550-556.

Harness, J. K., Organ, C. H., Jr., & Thompson, N. W. (1995). Operative experience of U.S. general surgery residents in thyroid and parathyroid disease. Surgery, 118(6), 1063-1069; discussion 1069-1070.

Hartl, D. M., Hans, S., Vaissière, J., Riquet, M., Laccourreye, O., & Brasnu, D. F. (2001). Objective voice analysis after autologous fat injection for unilateral vocal fold paralysis. Ann Otol Rhinol Laryngol, 110(3), 229-235.

Hartl, D. M., Travagli, J. P., Leboulleux, S., Baudin, E., Brasnu, D. F., & Schlumberger, M. (2005). Clinical review: Current concepts in the management of unilateral recurrent laryngeal nerve paralysis after thyroid surgery. J Clin Endocrinol Metab, 90(5), 3084-3088.

Hegner, C. F. (1932). A History of Thyroid Surgery. Ann Surg, 95(4), 481-492.

Henry, J. F., Audiffret, J., Denizot, A., & Plan, M. (1988). The nonrecurrent inferior laryngeal nerve: review of 33 cases, including two on the left side. Surgery, 104(6), 977-984.

Hermann, M., Hellebart, C., & Freissmuth, M. (2004). Neuromonitoring in thyroid surgery: prospective evaluation of intraoperative electrophysiological responses for the prediction of recurrent laryngeal nerve injury. Ann Surg, 240(1), 9-17.

Hess, M., Schroeder, D., & Püschel, K. (2011). Sling arytenoid adduction. Eur Arch Otorhinolaryngol, 268(7), 1023-1028.

Higgins, T. S., Gupta, R., Ketcham, A. S., Sataloff, R. T., Wadsworth, J. T., & Sinacori, J. T. (2011). Recurrent laryngeal nerve monitoring versus identification alone on post-thyroidectomy true vocal fold palsy: a meta-analysis. Laryngoscope, 121(5), 1009-1017.

Hoenig, D. M., Chrostek, C. A., & Amaral, J. F. (1996). Laparosonic coagulating shears: alternative method of hemostatic control of unsupported tissue. J Endourol, 10(5), 431-433.

Hong, K. H., & Kim, Y. K. (1997). Phonatory characteristics of patients undergoing thyroidectomy without laryngeal nerve injury. Otolaryngol Head Neck Surg, 117(4), 399-404.

Hunt, P. S., Poole, M., & Reeve, T. S. (1968). A reappraisal of the surgical anatomy of the thyroid and parathyroid glands. Br J Surg, 55(1), 63-66.

Hurtado-Lopez, L. M., & Zaldivar-Ramírez, F. R. (2002). Risk of injury to the external branch of the superior laryngeal nerve in thyroidectomy. Laryngoscope, 112(4), 626-629.

Iacobone, M., Viel, G., Zanella, S., Bottussi, M., Frego, M., & Favia, G. (2008). The usefulness of preoperative ultrasonographic identification of nonrecurrent inferior laryngeal nerve in neck surgery. Langenbecks Arch Surg, 393(5), 633-638.

Jeannon, J. P., Orabi, A. A., Bruch, G. A., Abdalsalam, H. A., & Simo, R. (2009). Diagnosis of recurrent laryngeal nerve palsy after thyroidectomy: a systematic review. Int J Clin Pract, 63(4), 624-629.

Kanase, N. V., Pangaonkar, S. A., & Panat, A. R. (2019, 29-30 March 2019). Approaches of Detecting and Analyzing the Thyroid Disease: A Review. 2019 2nd International Conference on Signal Processing and Communication (ICSPC),

Kasemsuwan, L., & Nubthuenetr, S. (1997). Recurrent laryngeal nerve paralysis: a complication of thyroidectomy. J Otolaryngol, 26(6), 365-367.

Katz, A. D., & Nemiroff, P. (1993). Anastamoses and bifurcations of the recurrent laryngeal nerve--report of 1177 nerves visualized. Am Surg, 59(3), 188-191.

Kierner, A. C., Aigner, M., & Burian, M. (1998). The external branch of the superior laryngeal nerve: its topographical anatomy as related to surgery of the neck. Arch Otolaryngol Head Neck Surg, 124(3), 301-303.

Kuhn, M. A., Bloom, G., & Myssiorek, D. (2013). Patient perspectives on dysphonia after thyroidectomy for thyroid cancer. J Voice, 27(1), 111-114.

Kwak, H. Y., Dionigi, G., Kim, D., Lee, H. Y., Son, G. S., Lee, J. B., Bae, J. W., & Kim, H. Y. (2016). Thermal injury of the recurrent laryngeal nerve by THUNDERBEAT during thyroid surgery: findings from continuous intraoperative neuromonitoring in a porcine model. J Surg Res, 200(1), 177-182.

Laccourreye, O., Malinvaud, D., Ménard, M., & Bonfils, P. (2009). Immobilités laryngées unilatérales après chirurgie de la glande thyroïde. Journal de Chirurgie, 146(6), 553-558.

Lahey, F. H., & Hoover, W. B. (1938). INJURIES TO THE RECURRENT LARYNGEAL NERVE IN THYROID OPERATIONS: THEIR MANAGEMENT AND AVOIDANCE. Ann Surg, 108(4), 545-562.

Lang, B. H., Wong, C. K., & Ma, E. P. (2016). A systematic review and meta-analysis on acoustic voice parameters after uncomplicated thyroidectomy. Laryngoscope, 126(2), 528-537.

Langman, J., & Sadler, T. W. (1990). Langman's medical embryology. Philadelphia, 1990, 7.

Lee, W. T., Milstein, C., Hicks, D., Akst, L. M., & Esclamado, R. M. (2007). Results of ansa to recurrent laryngeal nerve reinnervation. Otolaryngol Head Neck Surg, 136(3), 450-454.

Lefevre, J. H., Tresallet, C., Leenhardt, L., Jublanc, C., Chigot, J. P., & Menegaux, F. (2007). Reoperative surgery for thyroid disease. Langenbecks Arch Surg, 392(6), 685-691.

Lekacos, N. L., Tzardis, P. J., Sfikakis, P. G., Patoulis, S. D., & Restos, S. D. (1992). Course of the recurrent laryngeal nerve relative to the inferior thyroid artery and the suspensory ligament of Berry. Int Surg, 77(4), 287-288.

Leow, C. K., & Webb, A. J. (1998). The lateral thyroid ligament of Berry. Int Surg, 83(1), 75-78.

Lorenz, R. R., Esclamado, R. M., Teker, A. M., Strome, M., Scharpf, J., Hicks, D., Milstein, C., & Lee, W. T. (2008). Ansa cervicalis-to-recurrent laryngeal nerve anastomosis for unilateral vocal fold paralysis: experience of a single institution. Ann Otol Rhinol Laryngol, 117(1), 40-45.

Lynch, J., & Parameswaran, R. (2017). Management of unilateral recurrent laryngeal nerve injury after thyroid surgery: A review. Head Neck, 39(7), 1470-1478.

Maeda, T., Saito, M., Otsuki, N., Morimoto, K., Takahashi, M., Iwaki, S., Inoue, H., Tomoda, C., Miyauchi, A., & Nibu, K. (2013). Voice quality after surgical treatment for thyroid cancer. Thyroid, 23(7), 847-853.

Mallur, P. S., & Rosen, C. A. (2010). Vocal fold injection: review of indications, techniques, and materials for augmentation. Clin Exp Otorhinolaryngol, 3(4), 177-182.

Marcus, B., Edwards, B., Yoo, S., Byrne, A., Gupta, A., Kandrevas, J., Bradford, C., Chepeha, D. B., & Teknos, T. N. (2003). Recurrent laryngeal nerve monitoring in thyroid and parathyroid surgery: the University of Michigan experience. Laryngoscope, 113(2), 356-361.

Mathison, C. C., Villari, C. R., Klein, A. M., & Johns, M. M., 3rd. (2009). Comparison of outcomes and complications between awake and asleep injection laryngoplasty: a case-control study. Laryngoscope, 119(7), 1417-1423.

Mattioli, F., Bergamini, G., Alicandri-Ciufelli, M., Molteni, G., Luppi, M. P., Nizzoli, F., Grammatica, A., & Presutti, L. (2011). The role of early voice therapy in the incidence of motility recovery in unilateral vocal fold paralysis. Logoped Phoniatr Vocol, 36(1), 40-47.

McCulloch, T. M., Hoffman, H. T., Andrews, B. T., & Karnell, M. P. (2000). Arytenoid adduction combined with Gore-Tex medialization thyroplasty. Laryngoscope, 110(8), 1306-1311.

Migueis, A., Ucelay, I., Migueis, J., Urtasun, A., & Traissac, L. (1989). [Galen's anastomosis, an anatomic study in man]. Rev Laryngol Otol Rhinol (Bord), 110(4), 423-425. (Anse de Galien, étude anatomique chez l'homme.)

Min, Y. B., Finnegan, E. M., Hoffman, H. T., Luschei, E. S., & McCulloch, T. M. (1994). A preliminary study of the prognostic role of electromyography in laryngeal paralysis. Otolaryngol Head Neck Surg, 111(6), 770-775.

Mohebati, A., & Shaha, A. R. (2012). Anatomy of thyroid and parathyroid glands and neurovascular relations. Clin Anat, 25(1), 19-31.

Monfared, A., Gorti, G., & Kim, D. (2002). Microsurgical anatomy of the laryngeal nerves as related to thyroid surgery. Laryngoscope, 112(2), 386-392.

Moran, R. E., & Castro, A. F. (1951). The superior laryngeal nerve in thyroid surgery. Ann Surg, 134(6), 1018-1021.

More, Y., Shnayder, Y., Girod, D. A., Sykes, K. J., Carlisle, M. P., Chalmers, B., Kraemer, C., & Tsue, T. T. (2013). Factors influencing morbidity after surgical management of malignant thyroid disease. Ann Otol Rhinol Laryngol, 122(6), 398-403.

Myssiorek, D. (2004). Recurrent laryngeal nerve paralysis: anatomy and etiology. Otolaryngol Clin North Am, 37(1), 25-44, v.

Negus, V. (1957). The mechanism of the larynx. Laryngoscope, 67(10), 961-986.

Nemiroff, P. M., & Katz, A. D. (1982). Extralaryngeal divisions of the recurrent laryngeal nerve. Surgical and clinical significance. Am J Surg, 144(4), 466-469.

Nguyen, Q. T., & Tsien, R. Y. (2013). Fluorescence-guided surgery with live molecular navigation--a new cutting edge. Nat Rev Cancer, 13(9), 653-662.

Paniello, R. C., Edgar, J. D., Kallogjeri, D., & Piccirillo, J. F. (2011). Medialization versus reinnervation for unilateral vocal fold paralysis: a multicenter randomized clinical trial. Laryngoscope, 121(10), 2172-2179.

Payr, E. (1915). Plastik am schildknorpel zur Behebung der Folgen einseitiger Stimmbandlahmung. Dtsch Med Wochenschr, 43(1), 65-61.

Pelizzo, M. R., Toniato, A., & Gemo, G. (1998). Zuckerkandl's tuberculum: an arrow pointing to the recurrent laryngeal nerve (constant anatomical landmark). J Am Coll Surg, 187(3), 333-336.

Peppard, S. B., & Dickens, J. H. (1983). Laryngeal injury following short-term intubation. Ann Otol Rhinol Laryngol, 92(4 Pt 1), 327-330.

Prendes, B. L., Yung, K. C., Likhterov, I., Schneider, S. L., Al-Jurf, S. A., & Courey, M. S. (2012). Long-term effects of injection laryngoplasty with a temporary agent on voice quality and vocal fold position. Laryngoscope, 122(10), 2227-2233.

Raffaelli, M., Iacobone, M., & Henry, J. F. (2000). The "false" nonrecurrent inferior laryngeal nerve. Surgery, 128(6), 1082-1087.

Randolph, G. W. (2020). Surgery of the Thyroid and Parathyroid Glands E-Book. Elsevier Health Sciences.

Richer, S. L., & Randolph, G. W. (2009). Management of the recurrent laryngeal nerve in thyroid surgery. Operative Techniques in Otolaryngology-Head and Neck Surgery, 20(1), 29-34.

Robinson, J. L., Mandel, S., & Sataloff, R. T. (2005). Objective voice measures in nonsinging patients with unilateral superior laryngeal nerve paresis. J Voice, 19(4), 665-667.

Rosato, L., Avenia, N., Bernante, P., De Palma, M., Gulino, G., Nasi, P. G., Pelizzo, M. R., & Pezzullo, L. (2004). Complications of thyroid surgery: analysis of a multicentric study on 14,934 patients operated on in Italy over 5 years. World J Surg, 28(3), 271-276.

Rosen, C. A., & Simpson, C. B. (2008). Operative techniques in laryngology. Springer Science & Business Media.

Rosenthal, L. H., Benninger, M. S., & Deeb, R. H. (2007). Vocal fold immobility: a longitudinal analysis of etiology over 20 years. Laryngoscope, 117(10), 1864-1870.

Roy, A. D., Gardiner, R. H., & Niblock, W. M. (1956). Thyroidectomy and the recurrent laryngeal nerves. Lancet, 270(6930), 988-990.

Rubin, A. D., & Sataloff, R. T. (2008). Vocal fold paresis and paralysis: what the thyroid surgeon should know. Surgical oncology clinics of North America, 17(1), 175-196.

Sakorafas, G. H., Kokoropoulos, P., Lappas, C., Sampanis, D., & Smyrniotis, V. (2012). External branch of the superior laryngeal nerve: applied surgical anatomy and implications in thyroid surgery. Am Surg, 78(9), 986-991.

Sanabria, A., Ramirez, A., Kowalski, L. P., Silver, C. E., Shaha, A. R., Owen, R. P., Suárez, C., Khafif, A., Rinaldo, A., & Ferlito, A. (2013). Neuromonitoring in thyroidectomy: a meta-analysis of effectiveness from randomized controlled trials. Eur Arch Otorhinolaryngol, 270(8), 2175-2189.

Sancho, J. J., Pascual-Damieta, M., Pereira, J. A., Carrera, M. J., Fontané, J., & Sitges-Serra, A. (2008). Risk factors for transient vocal cord palsy after thyroidectomy. Br J Surg, 95(8), 961-967.

Sanders, G., Uyeda, R. Y., & Karlan, M. S. (1983). Nonrecurrent inferior laryngeal nerves and their association with a recurrent branch. Am J Surg, 146(4), 501-503.

Sanders, I., & Mu, L. (1998). Anatomy of the human internal superior laryngeal nerve. Anat Rec, 252(4), 646-656.

Sanuki, T., Yumoto, E., Minoda, R., & Kodama, N. (2010). The role of immediate recurrent laryngeal nerve reconstruction for thyroid cancer surgery. J Oncol, 2010, 846235.

Schindler, A., Bottero, A., Capaccio, P., Ginocchio, D., Adorni, F., & Ottaviani, F. (2008). Vocal improvement after voice therapy in unilateral vocal fold paralysis. J Voice, 22(1), 113-118.

Seddon, H. J. (1942). A Classification of Nerve Injuries. Br Med J, 2(4260), 237-239.

Serpell, J. W., Yeung, M. J., & Grodski, S. (2009). The motor fibers of the recurrent laryngeal nerve are located in the anterior extralaryngeal branch. Ann Surg, 249(4), 648-652.

Simon, M. M. (1943). Recurrent laryngeal nerve in thyroid surgery: Triangle for its recognition and protection. The American Journal of Surgery, 60(2), 212-220.

Sinagra, D. L., Montesinos, M. R., Tacchi, V. A., Moreno, J. C., Falco, J. E., Mezzadri, N. A., Debonis, D. L., & Curutchet, H. P. (2004). Voice changes after thyroidectomy without recurrent laryngeal nerve injury. J Am Coll Surg, 199(4), 556-560.

Sørensen, K. R., & Klug, T. E. (2015). Routine outpatient thyroid surgery cannot be recommended. Dan Med J, 62(2).

Stack, B. C., Jr., Spencer, H. J., Lee, C. E., Medvedev, S., Hohmann, S. F., & Bodenner, D. L. (2012). Characteristics of inpatient thyroid surgery at US academic and affiliated medical centers. Otolaryngol Head Neck Surg, 146(2), 210-219.

Stavrakis, A. I., Ituarte, P. H., Ko, C. Y., & Yeh, M. W. (2007). Surgeon volume as a predictor of outcomes in inpatient and outpatient endocrine surgery. Surgery, 142(6), 887-899; discussion 887-899.

Stojadinovic, A., Henry, L. R., Howard, R. S., Gurevich-Uvena, J., Makashay, M. J., Coppit, G. L., Shriver, C. D., & Solomon, N. P. (2008). Prospective trial of voice outcomes after thyroidectomy: evaluation of patient-reported and clinician-determined voice assessments in identifying postthyroidectomy dysphonia. Surgery, 143(6), 732-742.

Sulica, L. (2004). The superior laryngeal nerve: function and dysfunction. Otolaryngol Clin North Am, 37(1), 183-201.

Tanaka, A., Isono, S., Ishikawa, T., Sato, J., & Nishino, T. (2003). Laryngeal resistance before and after minor surgery: endotracheal tube versus Laryngeal Mask Airway. Anesthesiology, 99(2), 252-258.

Thomusch, O., Machens, A., Sekulla, C., Ukkat, J., Lippert, H., Gastinger, I., & Dralle, H. (2000). Multivariate analysis of risk factors for postoperative complications in benign goiter surgery: prospective multicenter study in Germany. World J Surg, 24(11), 1335-1341.

Thomusch, O., Sekulla, C., Machens, A., Neumann, H. J., Timmermann, W., & Dralle, H. (2004). Validity of intra-operative neuromonitoring signals in thyroid surgery. Langenbecks Arch Surg, 389(6), 499-503.

van der Vorst, J. R., Schaafsma, B. E., Verbeek, F. P., Hutteman, M., Mieog, J. S., Lowik, C. W., Liefers, G. J., Frangioni, J. V., van de Velde, C. J., & Vahrmeijer, A. L. (2012). Randomized comparison of near-infrared fluorescence imaging using indocyanine green and 99(m) technetium with or without patent blue for the sentinel lymph node procedure in breast cancer patients. Ann Surg Oncol, 19(13), 4104-4111.

Van Lierde, K., D'Haeseleer, E., Wuyts, F. L., Baudonck, N., Bernaert, L., & Vermeersch, H. (2010). Impact of thyroidectomy without laryngeal nerve injury on vocal quality characteristics: an objective multiparameter approach. Laryngoscope, 120(2), 338-345.

Wang, Y., Ji, Q., Li, D., Wu, Y., Zhu, Y., Huang, C., Shen, Q., Wang, Z., Zhang, L., & Sun, T. (2011). Preoperative CT diagnosis of right nonrecurrent inferior laryngeal nerve. Head Neck, 33(2), 232-238.

Weisberg, N. K., Spengler, D. M., & Netterville, J. L. (1997). Stretch-induced nerve injury as a cause of paralysis secondary to the anterior cervical approach. Otolaryngol Head Neck Surg, 116(3), 317-326.

Wu, B. L., Sanders, I., Mu, L., & Biller, H. F. (1994). The human communicating nerve. An extension of the external superior laryngeal nerve that innervates the vocal cord. Arch Otolaryngol Head Neck Surg, 120(12), 1321-1328.

Yalçin, B. (2006). Anatomic configurations of the recurrent laryngeal nerve and inferior thyroid artery. Surgery, 139(2), 181-187.

Yao, H. S., Wang, Q., Wang, W. J., & Ruan, C. P. (2009). Prospective clinical trials of thyroidectomy with LigaSure vs conventional vessel ligation: a systematic review and meta-analysis. Arch Surg, 144(12), 1167-1174.

Zábrodský, M., Bouček, J., Kastner, J., Kuchař, M., Chovanec, M., & Betka, J. (2012). Immediate revision in patients with bilateral recurrent laryngeal nerve palsy after thyroid and parathyroid surgery. How worthy is it? Acta Otorhinolaryngol Ital, 32(4), 222-228.

Zeitels, S. M., Hillman, R. E., Desloge, R. B., & Bunting, G. A. (1999). Cricothyroid subluxation: a new innovation for enhancing the voice with laryngoplastic phonosurgery. Ann Otol Rhinol Laryngol, 108(12), 1126-1131.

Zheng, H., Li, Z., Zhou, S., Cuan, Y., & Wen, W. (1996). Update: laryngeal reinnervation for unilateral vocal cord paralysis with the ansa cervicalis. Laryngoscope, 106(12 Pt 1), 1522-1527.

CHAPTER 5

MESENCHYMAL STEM CELLS TREATMENT IN PREMATURE OVARIAN FAILURE

Büşra ÇETİNKAYA ÜN[1] , Burak ÜN[2]

[1] MD.,University of Health Sciences Adana City Training and Research Hospital, Adana, Turkey busracetinkayaun@gmail.com. ORCID ID: 0000-0001-9466-4278
[2] MD.,University of Health Sciences Adana City Training and Research Hospital, Adana, Turkey.burakun81@gmail.com. ORCID ID: 0000-0002-8885-7062

INTRODUCTION

Infertility is defined as the inability to achieve pregnancy despite unprotected sexual intercourse for one year. With regular unprotected sexual intercourse, 90% of couples achieve pregnancy at the end of one year (Rowe et al. 1993, Gnoth et al. 2005). Obtaining pregnancy more than one year after pregnancy planning is called subfertility (Gnoth et al. 2005). Fecundability is defined as the probability of pregnancy achieved per cycle, while fecundity is defined as the probability of obtaining a live birth after one cycle. Sterility is defined as the absence of the possibility of spontaneous pregnancy (Rowe et al. 1993, Wang et al. 2003, Zinaman et al. 1996). In the world, 8-12% of couples of reproductive age are thought to be infertile (Johnson et al. 2012). As age progresses, oocyte quality decreases, follicular atresia increases, and ovarian reserve decreases (Hendershot et al. 1982). The percentage of women who cannot have children after unprotected intercourse is 6% between the ages of 20-24, 9% between the ages of 25-29, 15% between the ages of 30-34, 30% between the ages of 35-39 and 64% between the ages of 40-44 (Menken et al. 1986). The main causes of infertility; male factor, decreased ovarian reserve, ovulatory factor, tubal factor, uterine factor, pelvic factor and unexplained infertility. In infertile cases, there are 15-20% ovulation disorders, 30-40% pelvic factors, and 30-40% male factors. No cause could be found in 20-30% of infertile couples and it was defined as unexplained infertility (Bradshaw, Carr. 1993, Ray et al. 2012).

Ovarian Reserve and Reduced Ovary Reserve

Primordial germ cells that appear on the wall of the yolk sac at the end of the 3rd week of the embryo migrate from here and reach the gonad drafts at the beginning of the 5th week and turn into oogoniums. Their number reaches 7 million by the 5th month of intrauterine life. Although most oogonia have transformed into primary oocytes at 7 months of gestation, most primary oocytes also undergo atresia by programmed cell death and the number of oocytes decreases. Thus, at puberty, there are approximately 300,000 oocytes in the ovaries. The primary function of the ovaries is to produce mature oocyte capable of fertilization. The definition of ovarian reserve indicates the quantity and quality of oocytes that can provide dominant follicle formation at any age, in the late phase of the follicular phase of the menstrual cycle. Most

of the women with decreased ovarian reserve have regular menses and it has been determined that the number of ovarian follicles is reduced. Depending on this situation, limited response to ovarian stimulation and decreased fecundity were detected in the treatment of infertility. Age-related infertility is closely related to loss of viable oocytes (Hoffman et al. 2016, Ross, Pawlina. 2016, Hall. 2015, Kierszenbaum, Tres. 2015, Committee on Gynecologic P. 2015). With aging, the risk of genetic anomalies and mitochondrial deletion increases significantly in remaining oocytes. These factors cause a decrease in pregnancy rates and an increase in pregnancy losses both spontaneously and treatment cycles. The general indicator of low ovarian reserve can be defined as the development of less than 3-5 follicles in IVF cycles. Advanced reproductive age (over 35 years), familial history of early menopause, genetic diseases (eg, 45X mosaicism), FMR1 premutation (Fragile X), conditions that cause ovarian injury (eg, endometriosis, pelvic infection), previous ovarian surgery (eg, endometrioma) Surgery), oophorectomy, gonadotoxic treatment for cancer and history of pelvic radiation, history of gonadotoxic treatment and smoking are risk factors for decreased ovarian reserve (Hoffman et al. 2016, Committee on Gynecologic P. 2015, Billig et al. 1996, Laml et al. 2000, Amsterdam et al. 1997).

Premature Ovarian Insufficiency

Premature ovarian failure or primary ovarian failure was first described by Fuller Albright in 1942 as hypergonadotropic hypogonadism in women younger than 40 years. It is defined as the presence of amenorrhea for four months or longer in a woman under the age of 40 and the level of follicle stimulating hormone (FSH) measured at two different intervals in the menopausal range (FSH> 40 mIU/L). Physiological and psychological problems arise with hypergonadism and the decrease in the level of sex steroids in the blood. Ovarian insufficiency may occur as a result of decreased follicular reserve and accelerated follicular atresia (Nelson. 2009, Albright et al. 1942). Premature ovarian failure; It may occur due to chromosomal etiology (eg Turner syndrome), FMR1 premutation (Fragile X carrier), infections (Mumps, HIV, CMV), autoimmune lymphocytic oophoritis, galactosemia, Perrault syndrome. Iatrogenic causes constitute 80-90% of the cases. Pelvic surgery, which is one of the iatrogenic causes, can lead to POF

by disrupting the ovarian blood supply, causing inflammation or directly causing follicle loss. Among the iatrogenic causes, the most common causes of POF are radiotherapy and chemotherapy. POF can occur at radiation doses above 6 Gy, and sterility develops at doses above 8 Gy. Alkylating chemotherapeutics such as cyclophosphamide may cause POF by affecting non-dividing oocytes and primordial follicles (Cooper et al. 2011, Rebar. 2009). Infertility is common in women with POF, and only 5-10% of women can become pregnant (van Kasteren, Schoemaker, 1999). ART techniques such as oocyte and embryo cryopreservation are used in patients at risk of developing POF. However, the methods that can be used after POF are limited. Today, the highest pregnancy probability in POF patients can be achieved with oocyte donation. (Cobo et al. 2010, Oktay, Oktem. 2010). Advances in stem cell therapy and studies on this subject suggest that stem cell and stem cell conditioned media will be a new treatment option for these patients (Zhang. 2020, Sheikhansari. 2018)

Mesenchymal Stem Cells and Conditioned Medium

In the 21st century, as stem cell technology develops, hope for regenerative medicine is increasing day by day. As the characteristics of stem cells are defined, it has been shown that stem cells can differentiate into various tissue types (Majumdar. 1998). Regeneration of damaged cells, tissues or structures after disease, damage or aging is the goal of regenerative medicine. Nowadays, embryonic development and tissue restoration are tried to be understood with the help of stem cell biology (Alonso, Fuchs. 2003, Harada, Rodan. 2003, Radtke, Clevers. 2005, Stocum. 2012). Stem cells are unique cells that can proliferate for a long time and differentiate into various cell types with their own signals (Odorico. 2001). Stem cells can reproduce by symmetrical cell division, preserving the characteristics of the parent cell. In addition, they can differentiate into progenitor cells of different tissues by asymmetric division (Stocum. 2001). Friedenstein et al. showed that when they transplanted the bone marrow stroma to another tissue in mice, it could differentiate into cells such as bone, fat, and cartilage (Friedenstein et al. 1966). Thus, it has been stated that there are other non-hematopoietic precursor cells in the bone marrow, and these cells have been reported to be the precursors of fibroblasts (Friedenstein et al. 1970). Because these cells can

transform into different cell lines (multipotency) and renew themselves, these cells are defined as mesenchymal stem cells (MSC) (Caplan. 1991, Prockop. 1997). Because MSCs are heterogeneous, specific cell surface markers alone are not sufficient for their identification. Instead, the functional properties of MSCs are defined by the combination of their differentiation into various cells and their phenotypic characters (Liu et al. 2009). The minimal criteria for the cell population to be considered as MSC are: (1) The isolated cells have the ability to adhere to plastic, (2) the expression of cell surface markers such as CD105, CD73 and CD90 is greater than 95%, (3) CD34, CD45, CD14 , Cd11b, CD79α or CD19 and HLA-DR markers have very low or no expression, (4) MSCs need to differentiate into cells such as bone, fat and cartilage (Dominici, 2006). Although MSCs are usually isolated from bone marrow, they can also be obtained from adipose tissue, umbilical cord, periosteum, skeletal muscle, placenta, tooth, pericyte, trabecular bone, articular cartilage, liver and thymus, or various other tissues (Bianco et al. 2008, Zuk et al. 2002).

MSCs are present in the bone marrow at a rate of 0.01-0.1% (Pittenger et al. 1999). MSCs have a fibroblastic morphology and are spindle-shaped. After the MSCs are isolated, media supplemented with serum are usually used for their proliferation, and growth factors can be added for the differentiation of these cells (Barry, Murphy. 2004). Even after prolonged migration and initiation of the immune response, these cells can become established in a variety of tissues. MSCs can migrate to the damaged area via factors released after tissue damage. The therapeutic value of MSCs increases with their high potential for regenerative medicine (Minguell et al. 2001).

In studies, growth factors and paracrine activity of cytokines released by transplanted stem cells explain the therapeutic potential of stem cells (Baglio et al. 2012, Makridakis. 2013). Studies have determined that stem cells in degenerative diseases can exert their beneficial effects on damaged tissues by their ability to secrete trophic factors. Different studies have shown that factors released by stem cells can regenerate tissues under different conditions in the absence of stem cells (Yang et al. 2013). There are factors released in the medium in which stem cells, called secretome, are cultured, and this medium is called conditioned medium. Hepatocyte growth factor (HGF) is a cytokine that provides follicle maturation and suppresses apoptosis

in ovarian follicles and granulosa cells (Fu et al. 2008). Another growth factor, basic fibroblastic growth factor (bFGF), plays a role as initiator of folliculogenesis, inducing primordial follicle development (Wang et al. 2013). Other studies have also shown that stem cells secrete these cytokines and growth factors into their conditioned media. Despite the benefit of stem cells, conditioned media containing secretome has many advantages such as being packable, can be frozen for a long time, transported more easily, and does not require donor-recipient matching (Pawitan. 2014, Bhang et al. 2014).

Mesenchymal Stem Cells and Conditioned Medium Therapy in Ovarium Damage

In a study, the reactivity of damaged ovaries was investigated. For this, first of all, an ovarian damage model was created using the anticancer agent cyclophosphamide (CTX). In a study, the adipose-derived MSCs (AD-MSCs) on ovarian function were then investigated. It has been shown that MSCs can induce angiogenesis and increase the number of follicles and corpus lutenin in the ovary. No deformation, tumor formation or death was observed in MSC transplanted animals. It has been observed that AD-MSCs secrete higher levels of vascular endothelial cell growth factor (VEGF), insulin-like growth factor-1 (IGF-1), and hepatocyte growth factor (HGF) from fibroblast cells. High VEGF, IGF-1 and HGF expression levels were determined in the ovaries. These findings suggest that MSCs can promote damaged ovarian function and may be beneficial for regenerative medicine (Takehara et al. 2013).

Human amniotic fluid stem cells (hAFCs) are able to differentiate into multiple cell lines and thus have the potential to be a source of donor cells for regenerative medicine. Following cell injection into the ovaries of mice sterilized by intraperitoneal injection of CTX and busulfan, ovarian morphology was restored and many follicle-containing oocytes were identified at each stage of development. It has been shown that stem cells labeled with GFP survive and differentiate into granulosa cells that enable oocyte maturation (Lai et al. 2013).

MSCs that are immunologically weak and have potent immunosuppressive activity are described as promising cellular therapeutics for the treatment of many diseases. Mesenchymal-like cells called umbilical

cord matrix stem cells (UCMSCs) obtained from Wharton gel are reported to secrete cytokines and growth factors. UCMSCs used for the treatment of POF have been reported to have reduced apoptosis of cumulus cells and improved ovarian function in an ovarian injury model after transplantation. Thus, it shows that UCMSCs can ameliorate ovarian tissue and inhibit apoptosis of granulosa cells (Wang et al. 2013).

Skin-derived MSCs (SMSCs) are seen as a new source for use in tissue therapy due to their ability to differentiate into three embryonic germ layers. Recent research has shown that skin-derived stem cells can differentiate into cells expressing germ cell specific markers in vitro and form oocytes in vivo. To determine the ability of SMSCs to reactivate the damaged ovary, a mouse model of damaged ovarian damage via busulfan and CTX was established. Real-time PCR showed decreased expression levels of pro-inflammatory cytokines such as TNFα, TGF-β, IL-8, IL-6, IL-1β and IFNγ after administration of SMSCs to mice with ovarian damage model. In addition, it was determined that the expression of oogenesis marker genes Nobox, Nanos3, and Lhx8 increased in the ovaries of mice treated with SMSC. Thus, it suggests that SMSCs may play a role in restoring the function of the damaged ovary (Lai et al. 2014).

Female patients receiving chemotherapy often face premature ovarian failure (POF). Menstrual-derived stem cells (MenSCs) have been reported to show MSC-like properties. Therefore, MenSCs are thought as a new source of stem cells that for regenerative medicine. In the study by Wang et al, a mouse model of POF was established by cisplatin, and then MenSCs or MenSC-conditioned medium (MenSC-CM) was injected into tail vein. After 7 or 21 days of treatment, MenSC transplantation has been shown to ameliorate the ovarian niche by inhibiting apoptosis in granulosa cells and ovarian interstitium fibrosis. It has also been reported to increase the number of follicles and sex hormone levels to normal values. In addition, it has been reported that MenSCs and CM partially secrete FGF2 and exert a protective effect on ovarian damage (Wang et al. 2017).

In a study, the chemotherapeutic agent Cyclophosphamide was administered to rats and ovarian damage occurred. Bone marrow-derived MSCs (BM-MSC) and their conditioned medium were directly injected into the damaged ovaries with Cyclophosphamide. The restorative effect of BM-

MSCs has been determined. In addition, in this study, when the effect of BM-MSCs was compared with the effect of the conditioned medium, it was shown that both had healing and restorative effects and there was no significant difference between them (Khanmohammadi et al. 2018).

Human amniotic epithelial cells (hAECs) are important candidates for regenerative medicine and have the potential to be replaced by dysfunctional cells and can achieve functional recovery after injury. Previous studies have shown that hAECs effectively reduce ovarian damage by inhibiting apoptosis of granulosa cells in animal models of premature ovarian failure/deficiency (POF/POI) (Zhang et al. 2015, Zhang et al. 2017). To investigate the effects of cytokines secreted by hAECs on chemotherapy-induced ovarian damage, hAECs or hAEC culture medium (hAEC-CM) were injected into the ovaries of mice with a POF/POI model. It was determined that there are 507 human cytokines in serum-free medium obtained from hAECs, and 109 cytokines in hAEC-CM can participate in various biological processes such as apoptosis, angiogenesis, cell cycle and immune response. The presence of healthy and mature follicles was observed in ovaries treated with hAECs or hAEC-CM. However, fibrosis and many atretic follicles were found in the untreated ovaries. These findings suggested that the paracrine effect of hAECs in animal models of POF may play a key role in the recovery of ovarian injury (Zhang et al. 2017).

In the study by Zhang and his team, they examined the mechanisms on the ovarian reserve capacity of human placental MSCs (hPMSC) in an autoimmune drug-induced POF model. The effect of hPMSCs on granulosa cell apoptosis and expressions of anti-Müllerian hormone (AMH), follicle stimulating hormone receptor (FSHR) was determined. After hPMSCs injection, and serum levels of anti-zona pellucida antibody (AzpAb), FSH, LH, E2, AMH were measured. As a result, after HPMSC transplantation, serum FSH, LH and AzpAb levels decreased significantly, but E2 and AMH levels increased significantly. It was also shown that granulosa cell apoptosis decreased. Thus, it has been reported that hPMSC transplantation can increase folliculogenesis, prevent follicular atresia and apoptosis of granulosa cell, and promote ovarian reserve capacity (Zhang et al. 2018).

Human amnion-derived MSCs (hAD-MSCs) hold promise for regenerative medicine, as there is currently no effective treatment for POF. Therefore, to determine the effects of hAD-MSCs and conditioned medium (hAD-MSC-CM) injected into both ovaries of POF rats. After hAD-MSC transplantation, ovarian injury and ovarian dysfunction were reduced in POF rats. hAD-MSC-CM injection decreased Bax expression, and increased Bcl-2 and endogenous VEGF expression. In addition, granulosa cell apoptosis was inhibited, which is increased due to chemotherapy (Ling et al. 2019).

CONCLUSION

Female infertility is a serious problem and different ways of treatment are being investigated. Today, ART is widely used for couples who cannot have children. However, in some cases such as ovarian damage, ART may be insufficient. Research has focused on regenerative medicine, and the development of stem cell technology seems to be a hope for the treatment of female infertility. MSCs from many sources have attracted the attention of researchers because of their potential for both proliferation and differentiation. It shows that MSCs may have a role in restoring damaged ovarian function and may be useful for regenerative medicine. Some studies have shown that MSCs are transplanted into experimental animals and alleviate ovarian damage and that MSCs can differentiate into granulosa cells in the ovary. In addition to the proliferation of MSCs in the injured area, the paracrine properties of MSCs can also heal damaged tissue. MSCs secrete chemokines, cytokines, growth factors and these factors increase the number of follicles by affecting the ovarian tissue. In conclusion, MSCs and conditioned stem cell medium have brought a new perspective to the treatment of female infertility.

REFERENCES

Albright, F., Smith, P., & Fraser, R. (1942). A syndrome characterized by primary ovarian insufficiency and decreased stature: report of 11 cases with a digression on hormonal control of axillary and pubic hair. *The American Journal of the Medical Sciences*, *204*(5), 625-648.

Alonso, L., & Fuchs, E. (2003). Stem cells of the skin epithelium. *Proceedings of the National Academy of Sciences*, *100*(suppl 1), 11830-11835.

Amsterdam, A., Dantes, A., Selvaraj, N., & Aharoni, D. (1997). Apoptosis in steroidogenic cells: structure-function analysis. *Steroids*, *62*(1), 207-211.

Baglio, S. R., Pegtel, D. M., & Baldini, N. (2012). Mesenchymal stem cell secreted vesicles provide novel opportunities in (stem) cell-free therapy. *Frontiers in physiology*, *3*, 359.

Barry, F. P., & Murphy, J. M. (2004). Mesenchymal stem cells: clinical applications and biological characterization. *The international journal of biochemistry & cell biology*, *36*(4), 568-584.

Bhang, S. H., Lee, S., Shin, J. Y., Lee, T. J., Jang, H. K., & Kim, B. S. (2014). Efficacious and clinically relevant conditioned medium of human adipose-derived stem cells for therapeutic angiogenesis. *Molecular Therapy*, *22*(4), 862-872.

Bianco, P., Robey, P. G., & Simmons, P. J. (2008). Mesenchymal stem cells: revisiting history, concepts, and assays. *Cell stem cell*, *2*(4), 313-319.

Billig, H., Chun, S. Y., Eisenhauer, K., & Hsueh, A. J. (1996). Gonadal cell apoptosis: hormone-regulated cell demise. *Human reproduction update*, *2*(2), 103-117.

Bradshaw, K. D., & Carr, B. R. (1993). Modern diagnostic evaluation of the infertile couple. *Textbook of Reproductive Medicine. East Norwalk, CT: Appleton & Lange*, 443-452.

Caplan, A. I. (1991). Mesenchymal stem cells. *Journal of orthopaedic research*, *9*(5), 641-650.

Cobo, A., Meseguer, M., Remohí, J., & Pellicer, A. (2010). Use of cryo-banked oocytes in an ovum donation programme: a prospective, randomized, controlled, clinical trial. *Human reproduction*, *25*(9), 2239-2246.

Committee on Gynecologic Practice. (2015). Committee opinion no. 618: Ovarian reserve testing. *Obstetrics and gynecology*, *125*(1), 268-273.

Cooper, A. R., Baker, V. L., Sterling, E. W., Ryan, M. E., Woodruff, T. K., & Nelson, L. M. (2011). The time is now for a new approach to primary ovarian insufficiency. *Fertility and sterility*, *95*(6), 1890-1897.

Dominici, M. L. B. K., Le Blanc, K., Mueller, I., Slaper-Cortenbach, I., Marini, F. C., Krause, D. S., ... & Horwitz, E. M. (2006). Minimal criteria for defining multipotent mesenchymal stromal cells. The International Society for Cellular Therapy position statement. *Cytotherapy*, *8*(4), 315-317.

Friedenstein, A. J., Chailakhjan, R. K., & Lalykina, K. (1970). The development of fibroblast colonies in monolayer cultures of guinea-pig bone marrow and spleen cells. *Cell Proliferation*, *3*(4), 393-403.

Friedenstein, A. J., Piatetzky-Shapiro, I. I., & Petrakova, K. V. (1966). Osteogenesis in transplants of bone marrow cells.

Fu, X. F., He, Y. L., Xie, C. H., & Liu, W. (2008). Bone marrow mesenchymal stem cell transplantation improves ovarian function and structure in rats with chemotherapy-induced ovarian damage. *Cytotherapy*, *10*(4), 353-363.

Gnoth, C., Godehardt, E., Frank-Herrmann, P., Friol, K., Tigges, J., & Freundl, G. (2005). Definition and prevalence of subfertility and infertility. *Human reproduction*, *20*(5), 1144-1147.

Hall, J. E., & Hall, M. E. (2015). *Guyton and Hall textbook of medical physiology e-Book*. Elsevier Health Sciences.

Harada, S. I., & Rodan, G. A. (2003). Control of osteoblast function and regulation of bone mass. *Nature*, *423*(6937), 349-355.

Hendershot, G. E., Mosher, W. D., & Pratt, W. F. (1982). Infertility and age: An unresolved issue. *Family planning perspectives*, *14*(5), 287-289.

Hoffman, B. L., Schorge, J. O., Bradshaw, K. D., Halvorson, L. M., Schaffer, J. I., & Corton, M. M. (2016). *Williams gynecology*. cGraw-Hill Education.

Johnson, J. A., Tough, S., Wilson, R. D., Audibert, F., Blight, C., BrockS, J. A., ... & Okun, N. (2012). Delayed child-bearing. *Journal of obstetrics and gynaecology Canada*, *34*(1), 80-93.

Khanmohammadi, N., Sameni, H. R., Mohammadi, M., Pakdel, A., Mirmohammadkhani, M., Parsaie, H., & Zarbakhsh, S. (2018). Effect of transplantation of bone marrow stromal cell-conditioned medium on ovarian function, morphology and cell death in cyclophosphamide-treated rats. *Cell Journal (Yakhteh)*, *20*(1), 10.

Kierszenbaum, A. L., & Tres, L. (2015). *Histology and cell biology: an introduction to pathology E-book*. Elsevier Health Sciences.

Lai, D., Wang, F., Chen, Y., Wang, L., Wang, Y., & Cheng, W. (2013). Human amniotic fluid stem cells have a potential to recover ovarian function in mice with chemotherapy-induced sterility. *BMC developmental biology*, *13*(1), 1-13.

Lai, D., Wang, F., Dong, Z., & Zhang, Q. (2014). Skin-derived mesenchymal stem cells help restore function to ovaries in a premature ovarian failure mouse model. *PLoS one*, *9*(5), e98749.

Laml, T., Schulz-Lobmeyr, I., Obruca, A., Huber, J. C., & Hartmann, B. W. (2000). Premature ovarian failure: etiology and prospects. *Gynecological endocrinology*, *14*(4), 292-302.

Ling, L., Feng, X., Wei, T., Wang, Y., Wang, Y., Wang, Z., ... & Xiong, Z. (2019). Human amnion-derived mesenchymal stem cell (hAD-MSC) transplantation improves ovarian function in rats with premature ovarian insufficiency (POI) at least partly through a paracrine mechanism. *Stem cell research & therapy*, *10*(1), 1-18.

Liu, Z. J., Zhuge, Y., & Velazquez, O. C. (2009). Trafficking and differentiation of mesenchymal stem cells. *Journal of cellular biochemistry*, *106*(6), 984-991.

Majumdar, M. K., Thiede, M. A., Mosca, J. D., Moorman, M., & Gerson, S. L. (1998). Phenotypic and functional comparison of cultures of marrow-derived mesenchymal stem cells (MSCs) and stromal cells. *Journal of cellular physiology*, *176*(1), 57-66.

Makridakis, M., Roubelakis, M. G., & Vlahou, A. (2013). Stem cells: insights into the secretome. *Biochimica et Biophysica Acta (BBA)-Proteins and Proteomics*, *1834*(11), 2380-2384.

Menken, J., Trussell, J., & Larsen, U. (1986). Age and infertility. *Science*, *233*(4771), 1389-1394.

Minguell, J. J., Erices, A., & Conget, P. (2001). Mesenchymal stem cells. *Experimental biology and medicine*, *226*(6), 507-520.

Nelson, L. M. (2009). Primary ovarian insufficiency. *New England Journal of Medicine*, *360*(6), 606-614.

Odorico, J. S., Kaufman, D. S., & Thomson, J. A. (2001). Multilineage differentiation from human embryonic stem cell lines. *Stem cells*, *19*(3), 193-204.

Oktay, K., & Oktem, O. (2010). Ovarian cryopreservation and transplantation for fertility preservation for medical indications: report of an ongoing experience. *Fertility and sterility*, *93*(3), 762-768.

Pawitan, J. A. (2014). Prospect of stem cell conditioned medium in regenerative medicine. *BioMed research international*, *2014*.

Pittenger, M. F., Mackay, A. M., Beck, S. C., Jaiswal, R. K., Douglas, R., Mosca, J. D., ... & Marshak, D. R. (1999). Multilineage potential of adult human mesenchymal stem cells. *science*, *284*(5411), 143-147.

Prockop, D. J. (1997). Marrow stromal cells as stem cells for nonhematopoietic tissues. *Science*, *276*(5309), 71-74.

Radtke, F., & Clevers, H. (2005). Self-renewal and cancer of the gut: two sides of a coin. *Science*, *307*(5717), 1904-1909.

Ray, A., Shah, A., Gudi, A., & Homburg, R. (2012). Unexplained infertility: an update and review of practice. *Reproductive biomedicine online*, *24*(6), 591-602.

Rebar, R. W. (2009). Premature ovarian failure. *Obstetrics & Gynecology*, *113*(6), 1355-1363.

Ross, M. H., & Pawlina, W. (2016). Histologya text and atlas: with correlated cell and molecular biology.

Rowe, P. J., Comhaire, F., Hargreave, T., & Mellows, H. (1993). WHO manual for the standardized investigation and diagnosis of the infertile couple. *Press Syndicate of the University of Cambridge, Cambridge, 1993*.

Sheikhansari, G., Aghebati-Maleki, L., Nouri, M., Jadidi-Niaragh, F., & Yousefi, M. (2018). Current approaches for the treatment of premature ovarian failure with stem cell therapy. *Biomedicine & Pharmacotherapy*, *102*, 254-262.

Stocum, D. L. (2001). Stem cells in regenerative biology and medicine. *Wound repair and regeneration*, *9*(6), 429-442.

Stocum, D. L. (2012). *Regenerative biology and medicine*. Academic Press.

Takehara, Y., Yabuuchi, A., Ezoe, K., Kuroda, T., Yamadera, R., Sano, C., ... & Kato, O. (2013). The restorative effects of adipose-derived mesenchymal stem cells on damaged ovarian function. *Laboratory Investigation*, *93*(2), 181-193.

van Kasteren, Y. M., & Schoemaker, J. (1999). Premature ovarian failure: a systematic review on therapeutic interventions to restore ovarian function and achieve pregnancy. *Human reproduction update*, *5*(5), 483-492.

Wang, L., Ying, Y. F., Ouyang, Y. L., Wang, J. F., & Xu, J. (2013). VEGF and bFGF increase survival of xenografted human ovarian tissue in an experimental rabbit model. *Journal of assisted reproduction and genetics*, *30*(10), 1301-1311.

Wang, S., Yu, L., Sun, M., Mu, S., Wang, C., Wang, D., & Yao, Y. (2013). The therapeutic potential of umbilical cord mesenchymal stem cells in mice premature ovarian failure. *Biomed research international*, *2013*.

Wang, X., Chen, C., Wang, L., Chen, D., Guang, W., French, J., & Reproductive Health Study Group. (2003). Conception, early pregnancy loss, and time to clinical pregnancy: a population-based prospective study. *Fertility and sterility*, *79*(3), 577-584.

Wang, Z., Wang, Y., Yang, T., Li, J., & Yang, X. (2017). Study of the reparative effects of menstrual-derived stem cells on premature ovarian failure in mice. *Stem cell research & therapy*, *8*(1), 1-14.

Yang, D., Wang, W., Li, L., Peng, Y., Chen, P., Huang, H., ... & Zeng, C. (2013). The relative contribution of paracine effect versus direct differentiation on adipose-derived stem cell transplantation mediated cardiac repair. *PloS one*, *8*(3), e59020.

Zhang, C. (2020). The roles of different stem cells in premature ovarian failure. *Current stem cell research & therapy*, *15*(6), 473-481.

Zhang, H., Luo, Q., Lu, X., Yin, N., Zhou, D., Zhang, L., ... & Yuan, W. (2018). Effects of hPMSCs on granulosa cell apoptosis and AMH expression and their role in the restoration of ovary function in premature ovarian failure mice. *Stem cell research & therapy*, *9*(1), 1-12.

Zhang, Q., Bu, S., Sun, J., Xu, M., Yao, X., He, K., & Lai, D. (2017). Paracrine effects of human amniotic epithelial cells protect against chemotherapy-induced ovarian damage. *Stem cell research & therapy*, *8*(1), 1-13.

Zhang, Q., Xu, M., Yao, X., Li, T., Wang, Q., & Lai, D. (2015). Human amniotic epithelial cells inhibit granulosa cell apoptosis induced by chemotherapy and restore the fertility. *Stem cell research & therapy*, *6*(1), 1-10.

Zinaman, M. J., Clegg, E. D., Brown, C. C., O'Connor, J., & Selevan, S. G. (1996). Estimates of human fertility and pregnancy loss. *Fertility and sterility*, *65*(3), 503-509.

Zuk, P. A., Zhu, M., Ashjian, P., De Ugarte, D. A., Huang, J. I., Mizuno, H., ... & Hedrick, M. H. (2002). Human adipose tissue is a source of multipotent stem cells. *Molecular biology of the cell*, *13*(12), 4279-4295.

CHAPTER 6

THE VAGINAL MICROENVIRONMENT: THE DOMINANT SPECIES IN THE VAGINAL TRACT

Tuba UNVER[1] , Ayse Sebnem ERENLER[2]

[1] Res. Ast. Dr. Inonu University, Faculty of Pharmacy, Department of Pharmaceutical Microbiology, Malatya, Turkey, tuba.unver@inonu.edu.tr ORCID: 0000-0002-8655-2716
[2] Assoc. Prof. Malatya Turgut Ozal University, Faculty of Medicine, Department of Medical Biology, Malatya, Turkey, serenler44@gmail.com ORCID: 0000-0002-1786-5022

INTRODUCTION

Vaginal microenvironment changes depending on the glycogen content of vaginal epithelial cells, body hormone levels, age, vaginal pH, sexual intercourse, birth control methods, giving birth, and antibiotic therapy. In recent years, using new generation DNA sequencing methods, it has been reported that the vaginal microflora is a complex habitat in which microorganisms from more than 250 different species besides the dominant *Lactobacillus* species. Among the *Lactobacillus* species found in the vaginal microenvironment, especially *Lactobacillus cripatus*, *Lactobacillus gasseri*, *Lactobacillus iners* and *Lactobacillus jensenii* are found in ~75 % of women. In the remaining ~25 %, there are species mainly composed of anaerobic bacteria, and no dominant species is observed (Ravel et al., 2011).

Microorganisms such as *Aerococcus, Actinomyces, Allisonella, Anaerococcus, Alloscardovia, Atopobium, Arcanobacterium, Balneimonas, Bacteroides, Blastococcus, Bifidobacterium, Blautia, Bulleidia, Campylobacter, Coriobacteriacea, Corynebacterium, Citrobacter, Escherichia, Enterobacter, Faecalibacterium, Facklamia, Finegoldia, Gemella, Gardnerella, Haemophilus, Lachnospiracea, Megasphera, Massilia, Mollicutes, Moryella, Mobiluncus, Olsinella, Parvimonas, Prevotella, Peptinophilus, Peptostreptococcus, Proteobacteria, Porphyromonas, Providencia, Ruminococcaceae, Rhizobialis, Shigella, Salmonella, Sneathia, Solobacterium, Shuttleworthia, Streptococcus, Staphylococcus, Ureaplasma, Veillonella* were also detected in the vaginal microflora (Figure 1) (Shipitsyna et al., 2013; Gajer et al., 2012).

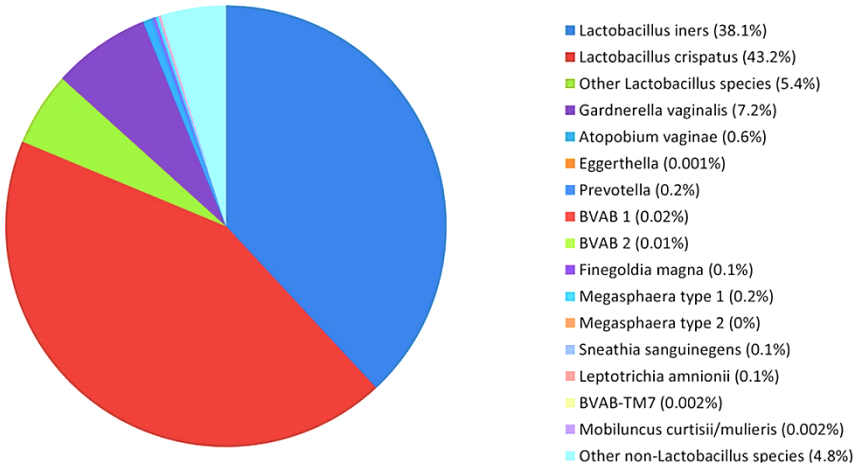

Figure 1. Distribution of the Normal Vaginal Microflora in Healthy Women (Shipitsyna et al., 2013)

1. *LACTOBACILLUS* AS THE DOMINANT GENUS OF VAGINAL MICROFLORA

Lactobacillus species are the most dominant bacteria of the vaginal flora and also play a key role in maintaining a healthy urogenital system (Eryilmaz et al., 2018). The importance of lactic acid bacteria in the vagina was first discovered by Albert Döderlein. (Döderlein, 1892). Krönig, a friend of Döderlein, described *Lactobacilli* as anaerobic curved rods; Curtis carried out the culturing of these microorganisms; Spiegel and Roberts named them *Mobiluncus curtisii* (Krönig, 1895; Curtis, 1913; Spiegel and Roberts, 1984). Later, Stanley Thomas used the term *Lactobacillus acidophilus* for the first time (Thomas, 1928). Lauer, Johnson et al. have identified several *Lactobacillus* species using the DNA-DNA hybridization method (Lauer and Kandler, 1980; Johnson et al., 1980).

In another study, among the microorganisms that make up the vaginal flora, *Lactobacillus* species were found to constitute at least 70 % (10^7 – 10^8 cfu (colony forming unit)/g vaginal fluid) of the bacteria found in the healthy vaginal microbiota (Ravel et al., 2011, Zhou 2004). *Lactobacillus* species that can be found in the vaginal flora of a healthy woman are composed of *L. cripatus, L. acidophilus, L. jensenii, L. gasseri, L. fermentum, L. plantarum,*

L. iners, L. minutus, L. brevis, L. catenaforme, L. leichmannii, L. salyarius, L. vaginalis, L. casei, L. delbrueckii, L. rhamnosus, and *L. reuteri* in varying proportions. (Figure 2) (Beamer et al., 2017; Ventolini, 2015; Cribby et al., 2008).

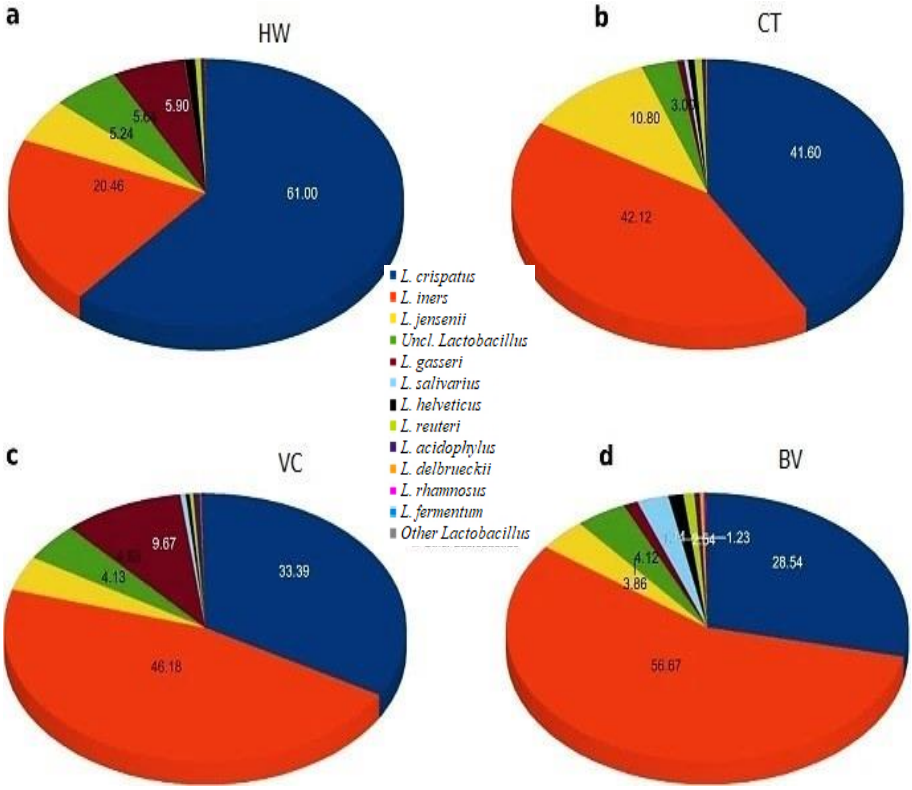

Figure 2. Species Distribution of *Lactobacillus* Microorganisms in Vaginal Flora. A) Healthy Woman (HW), B) *C. Trachomatis* C) Vaginal Candidiasis (VC), D) Bacterial Vaginosis (BV) (Ceccarani et al., 2019).

Before menarche, vaginal flora elements consist of some *Lactocillus* genus microorganisms and skin and intestinal microorganisms (Vicariotto et al., 2012). Estrogens and progesterone hormones regulate environmental conditions for microorganisms of the genus *Lactobacillus* from the beginning of the female reproductive phase. Lactobacilli and other bacteria metabolize glycogen into glucose, maltose, and lactic acid. This metabolism creates a vaginal pH of 3.8-4.4, which is described as usual (Mendling, 2016). To date, more than 120 *Lactobacillus* bacterial species have been identified. More than

ten different *Lactobacillus* species can be found in the vaginal flora of women after their regular menstrual cycles begin. However, flora dominated by one or two species is usually encountered (Beamer et al., 2017; Ventolini, 2015; Cribby et al., 2008; Larsen and Monif, 2001).

Lactobacillus species constitute an essential part of lactic acid bacteria. They are microaerophilic or anaerobic, non-spore-forming, acid-tolerant, bacillus, or cocci-shaped Gram-positive bacteria. They are usually of varying lengths and sizes (0.5-1.2 x 1-10 µm), but they exist in pairs or chains. At the same time, although some of them are catalase-negative, some of them can produce pseudo-catalase (Liu et al., 2014). Its optimum growth temperatures are 30-40 °C, and its pH is in the range of 5.5-6.2. The primary metabolism of Lactobacilli is primarily the breakdown of carbohydrates and related compounds by producing lactic acid and energy (Gülel, 2014). They are divided into two groups as heterofermentative and homofermentative according to their glucose fermentation. While homofermentative produce lactic acid as the outcome from carbohydrates, heterofermentative can also produce products such as ethanol, carbon dioxide, and acetic acid besides lactic acid (Florou-Paneri et al., 2013). Organic acids, hydrogen peroxide, reuterin, antifungal peptides, and bacteriocins from metabolites produced by *Lactobacillus* species are compounds with antimicrobial activity (Aldunate et al., 2015; Dobson et al., 2012; Holzapfel et al., 1995).

The microflora in the female urogenital system is of serious importance for the health and functioning of this system (Larsen and Monif, 2001). The normal flora of the human vagina plays a crucial role in the prevention of many urogenital diseases such as bacterial vaginosis, urinary tract infections, yeast infections (Wiesenfeld et al., 2003; Cherpes et al., 2003; Pybus and Onderdonk, 1999; Martin et al., 1999; Gupta et al., 1998). This protection is mainly attributed to *Lactobacillus* species which are dominant in the vaginal flora of healthy women. *Lactobacillus* species play essential protective roles through various mechanisms (Ravel et al., 2011). These include the production of various antimicrobial compounds such as lactic acid, bacteriocins and biosurfactants, hydrogen peroxide, co-aggregation, competitive exclusion, immunomodulation, and signaling between bacteria (Reid et al., 2011; Kaewsrichan et al., 2006). In a study, it was shown that *Lactobacillus* species adhered to the vaginal epithelial cells by covering their

entire surface, physically inhibiting the adsorption of pathogenic microorganisms, and a high number of *Lactobacillus* species adhered to the Hela cells and thus inhibited the attachment of *Chlamydia trachomatis* by binding to cell surface receptors. In another in vitro study, it was proven that there is an inhibitory effect on *C. trachomatis*, depending on the concentrations of *Lactobacillus* species in the vaginal flora (Nardini et al., 2016). The degree of adhesion of *Lactobacillus* species to Hela cells varies between species (Figure 3) (Mastromarino et al., 2014).

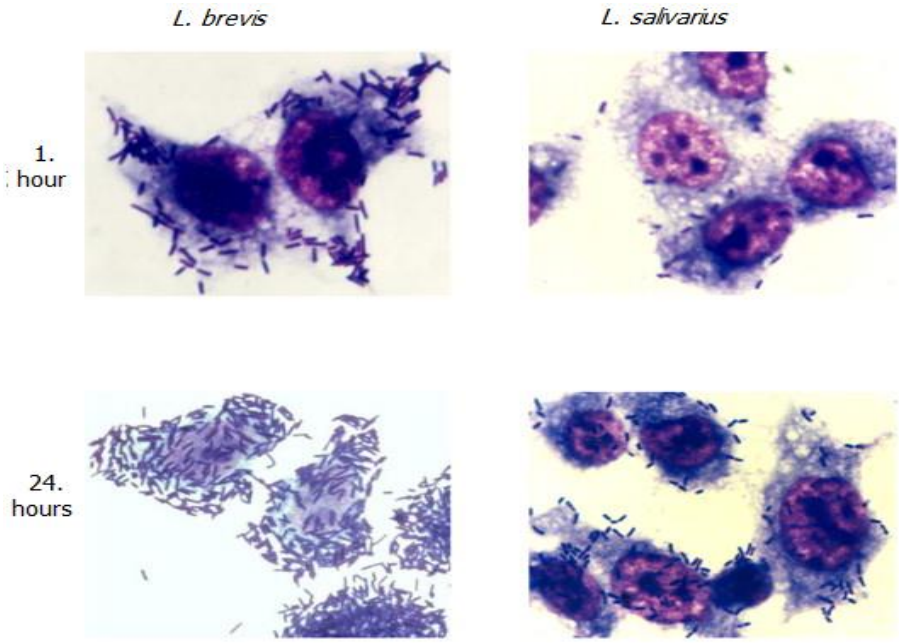

Figure 3. Gram Stain Sample Showing Adhesion of *Lactobacillus* Species to the Surface of Hela Cells at 1st and 24th Hours (Mastromarino et al., 2014)

1.1. *Lactobacillus acidophilus*

L. acidophilus is the most widely known and used probiotic bacteria (Ouwehand et al., 2014; Homayouni et al., 2014; Vicariotto et al., 2012). This species lives in the vagina and intestines, protecting against pathogenic microorganisms that cause disease. *L. acidophilus* is a rod-shaped microorganism, 0.6-0.9 x 1.5-6 µm in size, in pairs and short chains. The G+C ratio of *L. acidophilus* DNA is 32-37%, and this strain is obligate homofermentative. Since it is microaerophilic, it can also reproduce in an

aerobic environment, but it reproduces better in anaerobic conditions containing 10% water (H_2O), 5% carbon dioxide (CO_2), and 85% nitrogen (N) (Robinson and Itsaranuwat, 2005). *L. acidophilus* produces bacteriocins such as lactosine B, lactacin F, acidosine A and acidosine B. Many strains of the *Lactobacillus* genus have been shown to provide prophylactic and therapeutic benefits in humans (Gopal, 2011).

In 1980, microorganisms previously identified as *L. acidophilus* were reported to be heterogeneous (Johnson et al., 1980; Lauer et al., 1980). It has been discovered that the physiological properties of *L. acidophilus* strains differ in terms of the sugar pattern of the cell wall, the type of lactic acid produced, the G+C content of DNAs, and DNA homology values. Therefore, they renamed the *Lactobacillus* genus microorganisms as *L. acidophilus*, *L. cripatus*, *Lactobacillus amilovorus*, *Lactobacillus gasseri*, *Lactobacillus gallinarum*, and *Lactobacillus johnsonii* (Johnson et al., 1980; Lauer et al., 1980).

Since *L. acidophilus* species are very similar, it is impossible to distinguish them by simple biochemical and physiological tests, and *L. acidophilus* species are misidentified because they are closely related. Genotypic identification methods are needed to define these species definitively. Precise identification was achieved by applying more than one molecular characterization method and combining the results. Cell proteins of *L. acidophilus* strains were differentiated using SDS-PAGE, RAPD-PCR methods (Klein et al., 1998; Pot et al., 1993). Additionally, identification studies were carried out using PCR and DNA sequencing methods. (Nour, 1998; Tilsala-Timisjarvi and Alatossava 1997; Schleifer and Ludwig, 1995; Hertel et al, 1993; Hensiek et al, 1992).

1.2. *Lactobacillus. crispatus*

L. crispatus is a straight to slightly curved rod-shaped microorganism measuring 0.8-1.6 x 2.3-11 µm and forms short chains. They are obligate homofermentative, and the DNA G+C ratio is 35-38%. In addition to being found in the vaginal flora, they can be isolated from human feces and buccal cavities.

L. crispatus is seen as one of the most dominant species among Lactobacilli in the vaginal flora in studies (Beamer et al., 2017; Ventolini, 2015; Cribby et al., 2008; Larsen and Monif, 2001). The main reasons for this dominance of *L. crispatus* were listed by van der Veer et al. in 4 items as stated below (van der Veer et al., 2019).

- Ability to form an extracellular matrix (biofilm) on the vaginal mucosa surface
- Production of antimicrobials such as lactic acid, bacteriocins and their ability to produce H2O2, which inhibits the growth and adhesion of urogenital pathogens.
- Efficient use of available nutrients such as glycogen, which is the primary carbon source in the vaginal lumen
- Modulation of the host -immunogenic responses

L. crispatus supports the stability of the normal vaginal microbiota and the re-dominance of this microbiota in the vagina following antibiotic treatment and thus plays a role in protecting the vagina from bacterial vaginosis (Petrova et al., 2015; Verstraelen et al., 2009; Cruciani et al., 2015). It has been reported that *L. crispatus* strains inhibit the growth and adhesion of uropathogens to vaginal epithelial cells in vitro (Figure 4) (Kwok et al., 2006; Osset et al., 2001). *L. crispatus* has also been shown to reduce the adhesion of *Neisseria gonorrhoeae* and *C. trachomatis* to HeLa cells (Mastromarino et al., 2014; Vielfort et al., 2008).

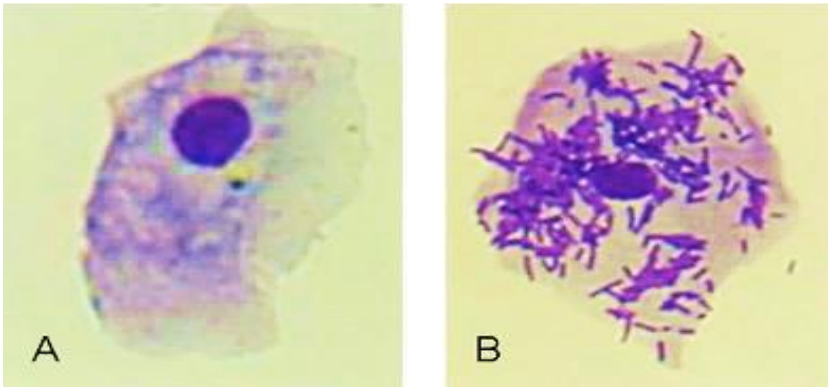

Figure 4. Gram Stain Sample Showing Adhesion of *L. crispatus* to the Surface of Vaginal Epithelial Cells at 1st (A) and 24th (B) Hours (Kwok et al., 2006).

1.3. *Lactobacillus jensenii*

L. jensenii is one of the most commonly found *Lactobacillus* species that dominate the normal vaginal microflora (Beamer et al., 2017; Cribby et al., 2008). In addition to the vaginal microflora, it is also found in the bladder microflora (Thomas-White et al., 2018). *L. jensenii* was found to have a bactericidal effect, preventing the colonization of pathogenic bacteria, including the uropathogenic *E. coli*, in the vagina and female bladder (Kalyoussef et al., 2012). While only two strains of *L. jensenii* from the bladder were characterized, Putonti et al. identified 11 new *L. jensenii* strains from urine samples taken from women (Thomas-White et al., 2018; Putonti et al., 2019).

L. jensenii metabolizes glycogen anaerobically. The increased estrogen level during pregnancy causes an increase in glycogen by affecting the metabolism of *L. jensenii* and thus contributes to the acidic vaginal environment. This acidic environment is a natural mechanism to prevent infections that can cause premature birth and suppress bacteria growth that causes bacterial vaginosis (O'Hanlon et al., 2011). *L. jensenii* is thought to produce enzymes from the liver that cause the release of hydrolase, which aids in the digestion of food in the gastrointestinal tract. Moreover, *L. jensenii* produces Lactacin F, reducing the population of other *Enterococcus* and *Lactobacillus* bacteria. Furthermore, *L. jensenii* is also used in the production of fermented foods. *L. jensenii* can be used in the supportive treatment of newborns to facilitate the digestion of breast milk. (Prince et al., 2014).

1.4. *Lactobacillus gasseri*

L. gasseri is one of the most common *Lactobacillus* species that make up the vaginal microbiome. *L. gasseri* is a rod-shaped microorganism in short chains, 0.6-0.8 x 3.0-5.0 µm in size, and they are obligate heterofermentative. Furthermore, *L. gasseri* does not hydrolyze arginine, and their DNA has a G+C ratio of 33-35% and is found in the vaginal and oral flora (Gülel, 2014). *L. gasseri*, one of the most dominant *Lactobacillus* species thought to be present in approximately 75% of women, is thought to be the most stable community over time and rarely transitions to other species (Gajer et al., 2012; Boris and Barbés, 2000). Therefore, it is thought that it is important to

elucidate the mechanism of protecting the host against pathogens due to its stability.

Glycogen is the main carbohydrate released when epithelial cells die and stored in the intermediate and superficial layers of vaginal epithelial cells. By secreting α-amylase from the host, *L. gasseri* is probably able to use glycogen as a carbon source (Spear et al., 2014; Anderson et al., 2014). Studies have shown that *L. gasseri* significantly inhibits the adhesion of *Trichomonas vaginalis* to vaginal cells (Phukan et al., 2018). *L. gasseri* was also found to significantly inhibit the colonization of *Candida albicans* by reducing the expression of genes involved in biofilm formation (Matsuda et al., 2018).

1.5. *Lactobacillus fermentum*

L. fermentum is best known for its probiotic properties. *L. fermentum* is a dominant microflora element in the vagina and intestine. Therefore, it can be used as a probiotic in the intestine and vagina. *L. fermentum*, like most *Lactobacillus* species, can prevent pathogenic infections in the intestine and vagina by producing inhibitory compounds such as lactic acid, short-chain fatty acids, bacteriocin, biosurfactants, and hydrogen peroxide (H_2O_2). (Kaur et al, 2013; Anukam and Reid, 2007; Boris and Barbés, 2000). *L. fermentum* shows antimicrobial activity by competing with pathogenic microorganisms for nutrients, adhering to intestinal and vaginal epithelial cell surfaces, preventing the adhesion of pathogens to these surfaces, and stimulating the immune system (Stöber et al., 2010; Lebeer et al., 2008; Reid and Burton, 2002). In a clinical study, *L. fermentum* decreased intestinal pathogens and increased the number of probiotic microorganisms in healthy people (Shieh et al., 2011). Oral use of probiotic microorganisms has normalized the vaginal microbiota (Vitali et al., 2012). In another study, as a result of keeping *L. fermentum* strain in the same environment with *E. coli* and *Gardnerella vaginalis*, an inhibitory effect of *L. fermentum* on these strains was observed (Figure 5) (Kaewnopparat et al., 2013).



Figure 5. Scanning Electron Microscopy (SEM) Images of (A) *E. coli* and (C) *G. vaginalis*, And Damaged (B) *E. Coli* and (D*) G. Vaginalis* (In the Arrows) After Treatment with *L. fermentum* (Kaewnopparat et al., 2013).

L. fermentum is thought to increase humans' immunological response and prevent community-acquired gastrointestinal and upper respiratory tract infections. *L. fermentum* can be used as a food preservative and produces various and potent antimicrobial peptides that can be applied as an alternative to antibiotics. In addition, this microorganism can reduce bloodstream cholesterol levels and help prevent liver disease and colorectal cancer (Naghmouchi et al., 2020). Finally, *L. fermentum* is an essential microorganism in dough technology that contributes to flavor, texture, or health-promoting dough ingredients. All this food technology-related availability has been used to develop new foodstuffs and limit the use of antibiotics in feed and food (Naghmouchi et al., 2020).

1.6. *Lactobacillus iners*

L. iners, like the other *Lactobacillus* mentioned above, is an essential part of the normal vaginal flora (Jakobsson and Forsum, 2007). Intensive studies have been carried out in the last few years, especially on identifying *L. iners* and their biological activation in the vaginal flora. Since *L. iners* has been found to be present in vaginal dysbiosis such as bacterial vaginosis, its role in vaginal health is not clear. *L. iners* has a small genome of about 1 Mbp, which indicates a symbiotic or parasitic lifestyle (Petrova et al., 2017). There is much debate about whether *L. iners* is beneficial or harmful to the host microbiota. A study reported that the vaginal microbiota dominated by *L. crispatus* was dominated by *L. iners* during menstruation (Gajer et al., 2012). Therefore, it has been reported that *L. iners* is a species that contributes to the improvement of the vaginal microbiota (Srinivasan et al., 2010). In addition, it has been reported that most pregnant women with an *L. iners*-dominant vaginal microbiota delivered on time without adverse pregnancy outcomes (Kindinger et al., 2017, Petricevic et al., 2014).

REFERENCES

Aldunate, M., Srbinovski, D., Hearps, A. C., Latham, C. F., Ramsland, P. A., Gugasyan, R., Cone, R. A., & Tachedjian, G. (2015). Antimicrobial and immune modulatory effects of lactic acid and short chain fatty acids produced by vaginal microbiota associated with eubiosis and bacterial vaginosis, *Frontiers in physiology*, 6, 164.

Beamer, M. A., Austin, M. N., Avolia, H. A., Meyn, L. A., Bunge, K. E., & Hillier, S. L. (2017). Bacterial species colonizing the vagina of healthy women are not associated with race, *Anaerobe*, *45*, 40–43.

Ceccarani, C., Foschi, C., Parolin, C., D'Antuono, A., Gaspari, V., Consolandi, C., Laghi, L., Camboni, T., Vitali, B., Severgnini, M., & Marangoni, A. (2019). Diversity of vaginal microbiome and metabolome during genital infections, *Scientific reports*, *9*(1), 14095.

Cherpes, T. L., Meyn, L. A., Krohn, M. A., Lurie, J. G., & Hillier, S. L. (2003). Association between acquisition of herpes simplex virus type 2 in women and bacterial vaginosis, *Clinical infectious diseases: an official publication of the Infectious Diseases Society of America*, *37*(3), 319–325.

Cribby, S., Taylor, M., & Reid, G. (2008). Vaginal microbiota and the use of probiotics, *Interdisciplinary perspectives on infectious diseases*, *2008*, 256490.

Curtis, A. H. (1913). A motile curved anaerobic bacillus in uterine discharges, *The Journal of Infectious Diseases*, 165-169.

Dobson, A., Cotter, P. D., Ross, R. P., & Hill, C. (2012). Bacteriocin production: a probiotic trait?, *Applied and environmental microbiology*, *78*(1), 1–6.

Döderlein, A. (1892). Das Scheidensekret und seine Bedeutung für das Puerperalfieber, *Besold*, Leipzig.

Eryilmaz, M., Gurpinar, S. S., Palabiyik, I. M., Guriz, H., & Gerceker, D. (2018). Molecular Identification and Antimicrobial Activity of Vaginal Lactobacillus sp, *Current pharmaceutical biotechnology*, *19*(15), 1241–1247.

Florou-Paneri, P., Christaki, E. & Bonos, E. (2013). Lactic acid bacteria as source of functional ingredients. In J. M. Kongo (Eds.), *Lactic Acid Bacteria-R & D for Food, Health and Livestock Purposes* (25, pp.589-614). InTech.

Gajer, P., Brotman, R. M., Bai, G., Sakamoto, J., Schütte, U. M., Zhong, X., Koenig, S. S., Fu, L., Ma, Z. S., Zhou, X., Abdo, Z., Forney, L. J., & Ravel, J. (2012). Temporal dynamics of the human vaginal microbiota, *Science translational medicine*, *4*(132), 132ra52.

Gopal, P.K. (2011). Lactic Acid Bacteria | Lactobacillus spp.: Lactobacillus acidophilus, In. J.W. Fuquay (Eds.), *Encyclopedia of Dairy Sciences* (2nd ed., pp. 91-95). Mississippi: Academic Press.

Gupta, K., Stapleton, A. E., Hooton, T. M., Roberts, P. L., Fennell, C. L., & Stamm, W. E. (1998). Inverse association of H2O2-producing lactobacilli and vaginal Escherichia coli colonization in women with recurrent urinary tract infections, *The Journal of infectious diseases*, *178*(2), 446–450.

Gülel, Ş. (2014). *Molecular identification and probiotic properties of 'lactobacillus acidophilus group' isolates from turkish kefir* (Master's thesis). Retrieved from https://tez.yok.gov.tr/UlusalTezMerkezi/tezSorguSonucYeni.jsp

Holzapfel, W. H., Geisen, R., & Schillinger, U. (1995). Biological preservation of foods with reference to protective cultures, bacteriocins and food-grade enzymes, *International journal of food microbiology*, *24*(3), 343–362.

Homayouni, A., Bastani, P., Ziyadi, S., Mohammad-Alizadeh-Charandabi, S., Ghalibaf, M., Mortazavian, A. M., & Mehrabany, E. V. (2014). Effects of probiotics on the recurrence of bacterial vaginosis: a review, *Journal of lower genital tract disease*, *18*(1), 79–86.

Johnson, J. L., Phelps, C. F., Cummins, C. S., London, J., & Gasser, F. (1980). Taxonomy of the Lactobacillus acidophilus group, *International Journal of Systematic Bacteriology*, 30(1), 53-68.

Kaewsrichan, J., Peeyananjarassri, K. & Kongprasertkit, J. (2006). Selection and identification of anaerobic lactobacilli producing inhibitory compounds against vaginal pathogens, *FEMS Immunol Med Microbiol*, *48*(1):75–83.

Klein, G., Pack, A., Bonaparte, C., & Reuter, G. (1998). Taxonomy and physiology of probiotic lactic acid bacteria, *International Journal of Food Microbiology*, *41*(2), 103-125.

Krönig, B. (1895). Über die Natur der Scheidenkeime, speciell über das Vorkommen anaerober Streptokokken im scheidensekret Schwangerer, *Centrbl Gynäkol, 16*, 409–412.

Larsen, B., & Monif, G. R. (2001). Understanding the bacterial flora of the female genital tract, *Clinical infectious diseases: an official publication of the Infectious Diseases Society of America*, *32*(4), e69–e77.

Lauer, E., & Kandler, O. (1980). Lactobacillus gasseri sp. nov., a new species of the subgenus Thermobacterium. Zentralblatt für Bakteriologie: I. Abt. Originale *C: Allgemeine, angewandte und ökologische Mikrobiologie*, *1*(1), 75-78.

Liu, W., Pang, H., Zhang, H. & Cai, Y. (2014). Biodiversity of lactic acid bacteria. In H. Zhang, Y. Cai, (Eds.), *Lactic Acid Bacteria.* (pp. 103-203). Dordrecht: Springer.

Martin, H. L., Richardson, B. A., Nyange, P. M., Lavreys, L., Hillier, S. L., Chohan, B., Mandaliya, K., Ndinya-Achola, J. O., Bwayo, J., & Kreiss, J. (1999). Vaginal lactobacilli, microbial flora, and risk of human immunodeficiency virus type 1 and sexually transmitted disease acquisition, *The Journal of infectious diseases*, *180*(6), 1863–1868.

Mastromarino, P., Di Pietro, M., Schiavoni, G., Nardis, C., Gentile, M., & Sessa, R. (2014). Effects of vaginal lactobacilli in Chlamydia trachomatis infection, *International journal of medical microbiology: IJMM*, *304*(5-6), 654–661.

Mendling, W. (2016). Vaginal Microbiota. In A. Schwiertz (Eds.), *Microbiota of the Human Body. Advances in Experimental Medicine and Biology* (Vol. 902, pp.83-93). Springer, Cham.

Nardini, P., Ñahui Palomino, R. A., Parolin, C., Laghi, L., Foschi, C., Cevenini, R., Vitali, B., & Marangoni, A. (2016). Lactobacillus crispatus inhibits the infectivity of Chlamydia trachomatis elementary bodies, in vitro study, *Scientific reports*, *6*, 29024.

Ouwehand, A. C., ten Bruggencate, S. J., Schonewille, A. J., Alhoniemi, E., Forssten, S. D., & Bovee-Oudenhoven, I. M. (2014). Lactobacillus acidophilus supplementation in human subjects and their resistance to enterotoxigenic Escherichia coli infection, *The British journal of nutrition*, *111*(3), 465–473.

Pot, B., Hertel, C., Ludwig, W., Descheemaeker, P., Kersters, K., & Schleifer, K. H. (1993). Identification and classification of Lactobacillus acidophilus, L. gasseri and L. johnsonii strains by SDS-PAGE and rRNA-targeted oligonucleotide probe hybridization, *Journal of General Microbiology*, 139(3), 513-517.

Pybus, V., & Onderdonk, A. B. (1999). Microbial interactions in the vaginal ecosystem, with emphasis on the pathogenesis of bacterial vaginosis, *Microbes and infection*, *1*(4), 285–292.

Ravel, J., Gajer, P., Abdo, Z., Schneider, G. M., Koenig, S. S., McCulle, S. L., Karlebach, S., Gorle, R., Russell, J., Tacket, C. O., Brotman, R. M., Davis, C. C., Ault, K., Peralta, L., & Forney, L. J. (2011). Vaginal microbiome of reproductive-age women, *Proceedings of the National Academy of Sciences of the United States of America*, *108*(Suppl 1), 4680–4687.

Reid, G., Younes, J. A., Van der Mei, H. C., Gloor, G. B., Knight, R., & Busscher, H. J. (2011). Microbiota restoration: natural and supplemented recovery of human microbial communities, *Nature reviews. Microbiology*, *9*(1), 27–38.

Robinson, R. & Itsaranuwat, P. (2005). In R.K. Robinson (Eds.), *Dairy Microbiology Handbook: The Microbiology of Milk and Milk Products* (3rd. ed.). New York: John Wiley & Sons.

Shipitsyna, E., Roos, A., Datcu, R., Hallén, A., Fredlund, H., Jensen, J. S., Engstrand, L., & Unemo, M. (2013). Composition of the vaginal microbiota in women of reproductive age--sensitive and specific molecular diagnosis of bacterial vaginosis is possible?, *PloS one*, *8*(4), e60670.

Spiegel, C. A., & Roberts, M. (1984). Mobiluncus gen. nov., Mobiluncus curtisii subsp. curtisii sp. nov., Mobiluncus curtisii subsp. holmesii subsp. nov., and Mobiluncus mulieris sp. nov., curved rods from the human vagina, *International Journal of Systematic and Evolutionary Microbiology*, *34*(2), 177-184.

Thomas, S. (1928). Döderlein's Bacillus: Lactobacillus Acidophilus, *The Journal of Infectious Diseases*, *43*(3), 218–227.

Ventolini, G. (2015). Vaginal Lactobacillus: biofilm formation in vivo - clinical implications, *International journal of women's health*, *7*, 243–247.

Vicariotto, F., Del Piano, M., Mogna, L., & Mogna, G. (2012). Effectiveness of the association of 2 probiotic strains formulated in a slow release vaginal product, in women affected by vulvovaginal candidiasis: a pilot study, *Journal of clinical gastroenterology*, *46 Suppl*, S73–S80.

Wiesenfeld, H. C., Hillier, S. L., Krohn, M. A., Landers, D. V., & Sweet, R. L. (2003). Bacterial vaginosis is a strong predictor of Neisseria gonorrhoeae and Chlamydia trachomatis infection, *Clinical infectious diseases : an official publication of the Infectious Diseases Society of America*, *36*(5), 663–668.

Zhou, X., Bent, S. J., Schneider, M. G., Davis, C. C., Islam, M. R., & Forney, L. J. (2004). Characterization of vaginal microbial communities in adult healthy women using cultivation-independent methods, *Microbiology (Reading, England)*, *150*(Pt 8), 2565–2573.

Nour, M. (1998). 16S-23S and 23S-5S intergenic spacer regions of lactobacilli: nucleotide sequence, secondary structure and comparative analysis, *Research in microbiology*, *149*(6), 433–448.

Tilsala-Timisjärvi, A., & Alatossava, T. (1997). Development of oligonucleotide primers from the 16S-23S rRNA intergenic sequences for identifying different dairy and probiotic lactic acid bacteria by PCR, *International journal of food microbiology*, *35*(1), 49–56.

Schleifer, K. H., & Ludwig, W. (1995). Phylogeny of the genus Lactobacillus and related genera, *Systematic and Applied Microbiology*,*18*(4), 461-467.

Hertel, C., Ludwig, W., Pot, B., Kersters, K., & Schleifer, K. H. (1993). Differentiation of lactobacilli occurring in fermented milk products by using oligonucleotide probes and electrophoretic protein profiles, *Systematic and Applied Microbiology*, *16*(3), 463-467.

Hensiek, R., Krupp, G., & Stackebrandt, E. (1992). Development of diagnostic oligonucleotide probes for four Lactobacillus species occurring in the intestinal tract, *Systematic and Applied Microbiology*, *15*(1), 123-128.

van der Veer, C., Hertzberger, R. Y., Bruisten, S. M., Tytgat, H., Swanenburg, J., de Kat Angelino-Bart, A., Schuren, F., Molenaar, D., Reid, G., de Vries, H., & Kort, R. (2019). Comparative genomics of human Lactobacillus crispatus isolates reveals genes for glycosylation and glycogen degradation: implications for in vivo dominance of the vaginal microbiota, *Microbiome*, *7*(1), 49.

Petrova, M. I., Lievens, E., Malik, S., Imholz, N., & Lebeer, S. (2015). Lactobacillus species as biomarkers and agents that can promote various aspects of vaginal health, *Frontiers in physiology*, *6*, 81.

Petrova, M. I., Reid, G., Vaneechoutte, M., & Lebeer, S. (2017). Lactobacillus iners: Friend or Foe?, *Trends in microbiology*, *25*(3), 182–191.

Verstraelen, H., Verhelst, R., Claeys, G., De Backer, E., Temmerman, M., & Vaneechoutte, M. (2009). Longitudinal analysis of the vaginal microflora in pregnancy suggests that L. crispatus promotes the stability of the normal vaginal microflora and that L. gasseri and/or L. iners are more conducive to the occurrence of abnormal vaginal microflora, *BMC microbiology*, *9*, 116.

Cruciani, F., Biagi, E., Severgnini, M., Consolandi, C., Calanni, F., Donders, G., Brigidi, P., & Vitali, B. (2015). Development of a microarray-based tool to characterize vaginal bacterial fluctuations and application to a novel antibiotic treatment for bacterial vaginosis, *Antimicrobial agents and chemotherapy*, *59*(5), 2825–2834.

Kwok, L., Stapleton, A. E., Stamm, W. E., Hillier, S. L., Wobbe, C. L., & Gupta, K. (2006). Adherence of Lactobacillus crispatus to vaginal epithelial cells from women with or without a history of recurrent urinary tract infection, *The Journal of urology*, *176*(5), 2050–2054.

Osset, J., Bartolomé, R. M., García, E., & Andreu, A. (2001). Assessment of the capacity of Lactobacillus to inhibit the growth of uropathogens and block their adhesion to vaginal epithelial cells, *The Journal of infectious diseases*, *183*(3), 485–491.

Vielfort, K., Sjölinder, H., Roos, S., Jonsson, H., & Aro, H. (2008). Adherence of clinically isolated lactobacilli to human cervical cells in competition with Neisseria gonorrhoeae, *Microbes and infection*, *10*(12-13), 1325–1334.

Thomas-White, K., Forster, S. C., Kumar, N., Van Kuiken, M., Putonti, C., Stares, M. D., Hilt, E. E., Price, T. K., Wolfe, A. J., & Lawley, T. D. (2018). Culturing of female bladder bacteria reveals an interconnected urogenital microbiota, *Nature communications*, *9*(1), 1557.

Kalyoussef, S., Nieves, E., Dinerman, E., Carpenter, C., Shankar, V., Oh, J., Burd, B., Angeletti, R. H., Buckheit, K. W., Fredricks, D. N., Madan, R. P., Keller, M. J., & Herold, B. C. (2012). Lactobacillus proteins are associated with the bactericidal activity against E. coli of female genital tract secretions, *PloS one*, *7*(11), e49506.

Putonti, C., Ahmad, A., Baddoo, G., Diaz, J., Do, M., Gallian, N., Lorentzen, C., Mohammed, H., Murphy, J., Olu-Ajeigbe, A., Yang, T., Miller-Ensminger, T., Stark, N., Maskeri, L., Van Dusen, J., & Wolfe, A. J. (2019). Draft Genome Sequences of 11 Lactobacillus jensenii Strains Isolated from the Female Bladder, *Microbiology resource announcements*, *8*(35), e00970-19.

O'Hanlon, D. E., Moench, T. R., & Cone, R. A. (2011). In vaginal fluid, bacteria associated with bacterial vaginosis can be suppressed with lactic acid but not hydrogen peroxide, *BMC infectious diseases*, *11*, 200.

Prince, A. L., Antony, K. M., Chu, D. M., & Aagaard, K. M. (2014). The microbiome, parturition, and timing of birth: more questions than answers, *Journal of reproductive immunology*, *104-105*, 12–19.

Boris, S., & Barbés, C. (2000). Role played by lactobacilli in controlling the population of vaginal pathogens, *Microbes and infection*, *2*(5), 543–546.

Anderson, D. J., Marathe, J., & Pudney, J. (2014). The structure of the human vaginal stratum corneum and its role in immune defense, *American journal of reproductive immunology*, *71*(6), 618–623.

Spear, G. T., French, A. L., Gilbert, D., Zariffard, M. R., Mirmonsef, P., Sullivan, T. H., Spear, W. W., Landay, A., Micci, S., Lee, B. H., & Hamaker, B. R. (2014). Human α-amylase present in lower-genital-tract mucosal fluid processes glycogen to support vaginal colonization by Lactobacillus, *The Journal of infectious diseases*, *210*(7), 1019–1028.

Phukan, N., Brooks, A., & Simoes-Barbosa, A. (2018). A Cell Surface Aggregation-Promoting Factor from Lactobacillus gasseri Contributes to Inhibition of Trichomonas vaginalis Adhesion to Human Vaginal Ectocervical Cells, *Infection and immunity*, *86*(8), e00907-917.

Matsuda, Y., Cho, O., Sugita, T., Ogishima, D., & Takeda, S. (2018). Culture Supernatants of Lactobacillus gasseri and L. crispatus Inhibit Candida albicans Biofilm Formation and Adhesion to HeLa Cells, *Mycopathologia*, *183*(4), 691–700.

Kaur, B., Balgir, P., Mittu, B., Chauhan, A., Kumar B., (2013). Purification and physicochemical characterization of anti-gardnerella vaginalis bacteriocin hv6b produced by Lactobacillus fermentum isolate from human vaginal ecosystem, *American Journal of Biochemistry and Molecular Biology*, *3*(1), 91-100.

Anukam, K. C. & Reid G. (2007). Lactobacillus plantarum and Lactobacillus fermentum with probiotic potentials isolated from the vagina of healthy Nigerian women, *Research Journal of Microbiology*, *2*, 81-87

Stöber, H., Maier, E., & Schmidt, H. (2010). Protective effects of Lactobacilli, Bifidobacteria and Staphylococci on the infection of cultured HT29 cells with different enterohemorrhagic Escherichia coli serotypes are strain-specific, *International journal of food microbiology*, *144*(1), 133–140.

Lebeer, S., Vanderleyden, J., & De Keersmaecker, S. C. (2008). Genes and molecules of lactobacilli supporting probiotic action, *Microbiology and molecular biology reviews : MMBR*, *72*(4), 728–764.

Reid, G., & Burton, J. (2002). Use of Lactobacillus to prevent infection by pathogenic bacteria, *Microbes and infection*, *4*(3), 319–324.

Shieh, M.-J., Shang, H.-f., Liao, F.-H., Zhu, J.-S. & Chien Y.-W. (2011). Lactobacillus fermentum improved intestinal bacteria flora by reducing Clostridium perfringens, *E-Spen the European e-Journal of Clinical Nutrition and Metabolism*, *6*, e59-e63

Vitali, B., Cruciani, F., Baldassarre, M. E., Capursi, T., Spisni, E., Valerii, M. C., Candela, M., Turroni, S., & Brigidi, P. (2012). Dietary supplementation with probiotics during late pregnancy: outcome on vaginal microbiota and cytokine secretion, *BMC microbiology*, *12*, 236.

Kaewnopparat, S., Dangmanee, N., Kaewnopparat, N., Srichana, T., Chulasiri, M., & Settharaksa, S. (2013). In vitro probiotic properties of Lactobacillus fermentum SK5 isolated from vagina of a healthy woman, *Anaerobe*, *22*, 6–13.

Naghmouchi, K., Belguesmia, Y., Bendali, F., Spano, G., Seal, B. S., & Drider, D. (2020). *Lactobacillus fermentum*: a bacterial species with potential for food preservation and biomedical applications, *Critical reviews in food science and nutrition*, *60*(20), 3387–3399.

Jakobsson, T., & Forsum, U. (2007). Lactobacillus iners: a marker of changes in the vaginal flora?, *Journal of clinical microbiology*, *45*(9), 3145.

Srinivasan, S., Liu, C., Mitchell, C. M., Fiedler, T. L., Thomas, K. K., Agnew, K. J., Marrazzo, J. M., & Fredricks, D. N. (2010). Temporal variability of human vaginal bacteria and relationship with bacterial vaginosis, *PloS one*, *5*(4), e10197.

Kindinger, L. M., Bennett, P. R., Lee, Y. S., Marchesi, J. R., Smith, A., Cacciatore, S., Holmes, E., Nicholson, J. K., Teoh, T. G., & MacIntyre, D. A. (2017). The interaction between vaginal microbiota, cervical length, and vaginal progesterone treatment for preterm birth risk, *Microbiome*, *5*(1), 6.

Petricevic, L., Domig, K. J., Nierscher, F. J., Sandhofer, M. J., Fidesser, M., Krondorfer, I., Husslein, P., Kneifel, W., & Kiss, H. (2014). Characterisation of the vaginal Lactobacillus microbiota associated with preterm delivery, *Scientific reports*, *4*, 5136.

CHAPTER 7

COMPLEMENTARY AND ALTERNATIVE MEDICINE IN THE TREATMENT OF INFERTILITY

Çiğdem KARAKAYALI AY[1] , Nurten ÖZÇALKAP[2]

[1] Res. Asistant ,Inonu University, Faculty of Health Sciences, Midwifery Department, Malatya,Turkey.cigdem.karakayali@inonu.edu.tr, ORCID ID: 0000-0002-5282-973X.
[2] Expert Midwifery, Inonu University, Institute of Health Sciences, Department of Midwifery, PhD Student, Malatya, Turkey. E-posta: nur_dan044@hotmail.com ORCID ID: 0000-0003-2440-968X

INTRODUCTION

According to the World Health Organization (WHO), infertility; It is defined as not being able to get pregnant, not being able to continue the pregnancy or not giving birth to a living baby as a result of pregnancy. Infertility is also defined as the inability to conceive for one year despite regular sexual intercourse, but WHO extends this period up to two years (İpekoğlu & Oral, 2019).

NICE (National Institute for Health and Clinical Excellence) defined infertility as the inability to conceive after 2 years of unprotected and regular sexual intercourse as a result of the absence of any known reproductive pathology. The American Society for Reproductive Medicine defines infertility as the inability to achieve a successful pregnancy after 12 months or more of regular and unprotected sexual intercourse (Szamatowicz & Szamatowicz, 2020). More than 186 million people worldwide suffer from infertility, mostly in developing countries (Inhorn & Patrizio, 2015).

It is estimated that infertility affects %8 to %12 of couples of reproductive age worldwide (Vander Borght & Wyns, 2018). In our country (Turkey), there are 1.5-2 million infertile couples, % 55-%75 of whom suffer from primary infertility and %25-% 40 from secondary infertility. These numbers are increasing gradually due to the career expectations of women and the increasing age of having children (Özturk et al., 2021).

When infertility cases are examined in the world, it is known that many communities use traditional treatment approaches. In some cases, it is determined that these methods and applications are used for support purposes in addition to modern medicine, and in some cases, only traditional methods are preferred (İpekoğlu & Oral, 2019).

Most of the treatments other than modern and scientific treatments are generally expressed as Complementary and Alternative Medicine (CAM). Although the terms alternative therapy and complementary therapy are often used interchangeably, the two terms have different meanings. While alternative therapy, is a type of treatment used instead of modern medicine, complementary medicine is a form of treatment used in addition to modern medicine (Emul et al.,2020)..

Currently, CAM for infertility continues to be effective by bringing up traditional treatments again. CAM is stated to be able to harmonize the

condition of the woman with a holistic approach in order to achieve a more effective therapeutic effect, and is increasingly used by infertile women. However, in some randomized controlled studies, it was stated that CAM did not have a significant effect on infertility and more studies were needed (Feng et al.,2021).

According to a meta-analysis study on the prevalence of infertility, potential needs and demands for treatment and care, with a sample of 172 413 women covering 25 countries at the international level, the incidence of infertility is %3.5-%16.7 in developed countries and %6.9-%9.3 in underdeveloped countries. In underdeveloped countries, the frequency has been reported as %5-%25. The lifetime infertility frequency was reported as %6.6 - %26.4. (Boivin et al.,2007).

It is reported that approximately %30-%60 of couples undergoing infertility treatment resort to CAM methods (Avcıbay & Kızılkaya Beji, 2003).

Although studies on the approaches of people with infertility problems towards complementary/alternative medicine practices are limited, according to the results of the study in which 157 (120 women, 37 men) from private clinics in England and 181 (124 women, 57 men) from national health centers were sampled, %63 of women, %25 of men stated that they were not indifferent to complementary/alternative medicine practices. %10 of these women stated that the complementary/alternative medicine method they used in the treatment of infertility was beneficial, %13 stated that they got the opinion that everything is possible by relaxing psychologically, and %22 helped them relax (Boivin et al.,2007).

In this section, it is aimed to explain the CAM approaches used in infertile women and to provide information by systematically reviewing the literature on the effectiveness and safety of these approaches.

1.COMPLEMENTARY AND ALTERNATIVE APPROACHES

1.1. Acupuncture

Acupuncture, a Latin word; It consists of a combination of the words acus (needle) and puncture (penetration). Acupuncture, which has been used since 4000 years ago, is a complementary and alternative treatment approach that aims to get results by stimulating certain points on the body with needles. The philosophy of acupuncture argues that there are two energy systems in the body called "Yin" and "Yang", which are opposite to each other but in a constant state of balance. It is reported that diseases occur when the balance between these energies is disturbed.

Acupuncture channels are located where these energies circulate freely. Each acupuncture channel has points localized on the body where it opens to the skin. By pinning these points, it is possible to balance the energies and help the treatment of diseases with acupuncture. Among the diseases in which the therapeutic properties of acupuncture are shown, female infertility is also included (Çayır & Gürsoy, 2018).

Acupuncture has been one of the most studied CAM approaches for improving fertility outcomes (Miner et al., 2018). Acupuncture has a long history of treating gynecological problems. With an increasing number of studies, it has been reported that acupuncture can regulate menstruation and help women conceive without the risk of multiple pregnancy (Miner et al., 2018; Zhou & Qu, 2019, Cochrane et al., 2014).

In a scoping study, it was reported that acupuncture used in the treatment of infertility had an effect on the fertility outcomes of men and women. While the evidence in this scoping study to show that acupuncture improves male and female fertility outcomes is high, there is no conclusive evidence that it is effective in the treatment of infertility, as other studies taken have not shown improvement (Miner et al., 2018).

1.2. Homeopathy

Founded by Samuel Hahnemann, a German physician and pharmacist, homeopathy is a CAM system that naturally heals the body non-toxic. “Homoios” as the word meaning; similar and “pathos”; to suffer from the

disease. This method aims to treat like with like by stimulating a self-healing mechanism (Yıllar Erkek ve Pasinlioğlu, 2016; SHGM, 2021; Bhatt, 2021).

The basic principle in homeopathy is the minimum number of doses. Hahnemann states that the human body has natural healing powers that only need a little stimulus to initiate and maintain the healing process. After the healing process has begun, it has been argued that it is not necessary to repeat the drug doses (Steinberg & Beal, 2003).

Homeopathy, which is accepted as one of the first applications of CAN approaches, is used in many countries around the world, especially in high-income countries. It is reported that homeopathic medicines are also effective on some gynecological diseases such as bleeding, cysts, vaginal discharge and infertility (Alizadeh Charandabi et al., 2016).

In a case series examining the effect of individualized homeopathic medicine use in the treatment of infertility, it was determined that the use of homeopathic medicines had positive effects on infertile couples and contributed significantly to positive pregnancy results (RajachandraSekar et al., 2021).

1.3. Ayurveda

The history of Ayurveda, which is similar to traditional Chinese medicine and is based on a traditional medicine system and used in the management of diseases, dates back to 3000 years (Kumar, 2017; Sodhi, 2020). In the Sanskrit word Ayurveda, the term “Ayu” can be translated as life and “Veda” as knowledge (Ramaswamy, 2010).

Ayurveda is a TAT defined in harmony with the laws of nature and the art of daily living. At the heart of this approach is the concept of the five elements. These elements are ether, air, fire, water and earth. In Ayurvedic science, these five elements are accepted as the building blocks of all creation and material existence, both organic and inorganic, both physically and symbolically (Ramaswamy, 2010). It states that human, a microcosm of nature, also exists from these five elements and the health of man and the universe depends on the balance and harmony of these elements (Ramaswamy, 2010; Posmontier & Teitelbaum, 2009).

The Ayurvedic approach, which perceives the disease as an imbalance, provides a holistic health service and a balance in a lifestyle with both its preventive and curative features (Ramaswamy, 2010; Sodhi, 2020).

In gynecological diseases, it is preferred to use ayurvedic drugs instead of the existing hormonal treatment. WHO confirms that the ayurvedic medicines used are safe and effective (WHO, 1993; Atul N. Jadhav & Bhutani, 2005).

Women are frequently exposed to stress factors this stress increases the formation of reactive oxygen species (ROS). Therefore, this situation impairs reproductive health by inducing oxidative stress (OS). Increased OS may cause infertility by affecting ovarian physiology and oocyte quality. It has been reported that ayurvedic drugs should be used frequently in order to overcome female reproductive health complications such as stress-mediated hormonal imbalance, polycystic ovary syndrome (PMS), failure in follicular growth and development, low oocyte quality and infertility. Because it is stated that these drugs can reduce the OS level and increase the antioxidant level in the body and improve reproductive health disorders (Pandey et al., 2018).

1.4. Hypnosis

"Hypnos", derived from the word Hypnosis means sleep in Greek. However, hypnosis is not a state of sleep, but rather a state of wakefulness (Ceyhan & Tasa Yiğit, 2016). In hypnosis, although the person is not unconscious, the person does not react to external stimuli (Taştan et al., 2015). At the same time, hypnosis is a special state of consciousness that provides physical relaxation by focusing attention on a certain point, and its use for treatment is defined as hypnotherapy (Peksoy et al., 2018).

There are not many evidence-based studies on the effects of hypnosis on reproductive health. In a study of women with hypothalamic amenorrhea, it was reported that with a single session of hypnosis, % 85experienced menstruation after 12 weeks. The mechanism of hypnosis on reproductive health is that it will help to relax and reduce the negative effect of anxiety on fertility (Avcıbay & Kızılkaya Beji, 2003).

In a scoping study examining the effect of CAM approaches on infertility treatment, it was reported that there are limited studies evaluating the use of hypnosis and fertility treatment, and that hypnosis has positive effects on infertility treatment, however, the level of evidence is low to moderate and needs to be supported by more studies (Miner et al., 2018).

1.5. Reflexology

Reflexology is the CAM approach based on the application of pressure to specific areas of the feet or hands (reflex points) resulting in stimulation of nerve points that mediate electrochemical messages (Levy et al., 2020).

In reflexology, it is aimed to provide the body with a state of balance and increase comfort by applying pressure to the reflex points of the soles of the feet and palms (Moghimi-Hanjani et al., 2015). It is reported that reflexology applied to the soles of the feet affects the psychological responses of people and causes healing in different organs of the body (Ferrer de Dios, 2005).

Reflexology is a complementary treatment method that improves women's quality of life and provides positive results without any side effects in premenstrual syndrome (PMS), dysmenorrhea, reproductive health and menopause problems (Bolsoy, 2016).

In the study evaluating the effectiveness of foot reflexology to induce ovulation, it was reported that reflexology did not provide a significant result on the induction rate compared to the placebo application and more studies are needed (Holt et al., 2009).

2. CONCLUSION

There are many CAM techniques used in infertility. We have explained some of them. However, the mechanisms of action of most of them are largely unknown today. In this direction, couples who receive adequate support for CAM for infertility management can adapt as long as they have psychological and physiological symptoms. As a result, complementary and alternative medicine approaches, the use of which is increasing day by day in the treatment of infertility, should be included in health services with scientifically valid studies with high level of evidence.

REFERENCES

Alizadeh Charandabi, S. M., Biglu, M. H., & Yousefi Rad, K. (2016). Effect of Homeopathy on Pain Intensity and Quality Of Life of Students With Primary Dysmenorrhea: A Randomized Controlled Trial. Iranian Red Crescent medical journal, 18(9), e30902. https://doi.org/10.5812/ircmj.30902

Avcıbay, B., & Kızılkaya Beji, N. (2003). İnfertilite tedavisinde tamamlayıcı/alternatif tıp uygulamaları. *Androloji Bülteni*, *15*(52), 71-74

Bhatt, V. K. (2021). Mother and child health care with homeopathy management of postpartum depression with homeopathy.Clınıcal and experimental homeopathy.*A peer-rewieved International Online e-Journal, 7, 1-19.* SNN: 0974-9799.

Boivin, J., Bunting, L., Collins, J. A., & Nygren, K. G. (2007). International estimates of infertility prevalence and treatment-seeking: potential need and demand for infertility medical care. *Human reproduction (Oxford, England), 22*(6), 1506–1512. https://doi.org/10.1093/humrep/dem046

Bolsoy, N. (2016). The Use of Reflexology in Women's Health Reflexology. In: Çamlı,A.A., Ak, B., Arabacı, R., Efe, R., editors.editors.Research Advancements In Health Scıences. *St. Kliment Ohridski University Press;* 2016.p. 373-385

Ceyhan, D., & Tasa Yiğit, T. (2016). Güncel tamamlayıcı ve alternatif tıbbi tedavilerin sağlık uygulamalarındaki yeri. *Düzce Ünversitesi Sağlık Bilimleri Enstitüsü Dergisi, 6*(3), 178-189.

Cochrane, S., Smith, C. A., Possamai-Inesedy, A., & Bensoussan, A. (2014). Acupuncture and women's health: an overview of the role of acupuncture and its clinical management in women's reproductive health. *International journal of women's health, 6,* 313–325. https://doi.org/10.2147/IJWH.S38969

Çayır, Y., & Gürsoy,P.G. (2018). İn vitro fertilizasyon ve akupunktur. *Konuralp Medical Journal*, *10*(3), 420-423. https://doi.org/10.18521/ktd.442446

Emul, T. G., Yilmaz, D. V., & Buldum, A. (2020). İnfertilite tedavisinde kullandiklari tamamlayici alternatif tedavi uygulamalarinin belirlenmesi. *Journal of Education and Research in Nursing*, *17*(4), 317-322.

Feng, J., Wang, J., Zhang, Y., Zhang, Y., Jia, L., Zhang, D., Zhang, J., Han, Y., & Luo, S. (2021). The Efficacy of Complementary and Alternative Medicine in the Treatment of Female Infertility. *Evidence-based complementary and alternative medicine : eCAM, 2021,* 6634309. https://doi.org/10.1155/2021/6634309

Ferrer de Dios R. (2005). Reflexología [Reflexology]. *Revista de enfermeria (Barcelona, Spain)*, *28*(3), 42–46.

Holt, J., Lord, J., Acharya, U., White, A., O'Neill, N., Shaw, S., & Barton, A. (2009). The effectiveness of foot reflexology in inducing ovulation: a sham-controlled randomized trial. *Fertility and sterility*, *91*(6), 2514–2519. https://doi.org/10.1016/j.fertnstert.2008.04.016

Inhorn, M. C., & Patrizio, P. (2015). Infertility around the globe: new thinking on gender, reproductive technologies and global movements in the 21st century. *Human reproduction update*, *21*(4), 411–426. https://doi.org/10.1093/humupd/dmv016

İpekoğlu, H. Y., & Oral, H. B.(2019). İnfertilitede Kullanılan Geleneksel Tedavi Yöntemleri ve Çeşitli Uygulamalar: Isparta Bölgesi. *Motif Akademi Halkbilimi Dergisi*, *12*(25), 105-119. https://doi.org/10.12981/mahder.523760.

Jadhav, A. N., & Bhutani, K. K. (2005). Ayurveda and gynecological disorders. Journal of ethnopharmacology, 97(1), 151–159. https://doi.org/10.1016/j.jep.2004.10.020

Kumar, S., Dobos, G.J., Rampp, T. (2017) The significance of Ayurvedic medicinal plants. *Journal of evidence-based complementary & alternative medicine*, *22*(3), 494-501. https://doi.org/10.1177/2156587216671392.

Levy, I., Attias, S., Stern Lavee, T., Avneri, O., Cohen, G., Balachsan, S., Sagi, S., & Schiff, E. (2020). The effectiveness of foot reflexology in reducing anxiety and duration of labor in primiparas: An open-label randomized controlled trial. *Complementary therapies in clinical practice*, *38*, 101085. https://doi.org/10.1016/j.ctcp.2019.101085

Miner, S. A., Robins, S., Zhu, Y. J., Keeren, K., Gu, V., Read, S. C., & Zelkowitz, P. (2018). Evidence for the use of complementary and alternative medicines during fertility treatment: a scoping review. *BMC complementary and alternative medicine*, *18*(1), 158. https://doi.org/10.1186/s12906-018-2224-7

Moghimi-Hanjani, S., Mehdizadeh-Tourzani, Z., & Shoghi, M. (2015). The Effect of Foot Reflexology on Anxiety, Pain, and Outcomes of the Labor in Primigravida Women. *Acta medica Iranica*, *53*(8), 507–511.

Ozturk, A., Aba, Y. A., & Sik, B. A. (2021). The relationship between stigma, perceived social support and depression in infertile Turkish women undergoing in vitro fertilization-embryo transfer. Archives of psychiatric nursing, 35(5), 434-440.

Pandey, A. K., Gupta, A., Tiwari, M., Prasad, S., Pandey, A. N., Yadav, P. K., Sharma, A., Sahu, K., Asrafuzzaman, S., Vengayil, D. T., Shrivastav, T. G.,

& Chaube, S. K. (2018). Impact of stress on female reproductive health disorders: Possible beneficial effects of shatavari (Asparagus racemosus). *Biomedicine & pharmacotherapy = Biomedecine & pharmacotherapie*, *103*, 46–49. https://doi.org/10.1016/j.biopha.2018.04.003

Peksoy, S., Demirhan, İ., Kaplan, S., Şahin, S. ve Arıöz-Düzgün, A. (2018). Tamamlayıcı ve alternatif tedavinin jinekolojik kanserlerde kullanımı. *Türkiye Sağlık Bilimleri ve Araştırmaları Dergisi, 1*(1), 36-47.

Posmontier, B., & Teitelbaum, M. (2009). An Ayurvedic approach to postpartum depression. Holistic nursing practice, 23(4), 201–216. https://doi.org/10.1097/HNP.0b013e3181aece5a

RajachandraSekar, B., Nair, J., Sunny, A., & Manoharan, A. (2021). Individualised Homeopathic Medicine in the Treatment of Infertility: A Case Series. *Homeopathy : the journal of the Faculty of Homeopathy*, 10.1055/s-0041-1725040. Advance online publication. https://doi.org/10.1055/s-0041-1725040

Ramaswamy S. Ayurveda-An ancient healing system's gifts to the modern woman. https://www.ayurvedacollege.com/wp content/uploads/2017/06/AyurvedaSandhiyaRamaswamy.pdf.2010;p:3-4. Retrieved on from, 10 January 2022.

Sağlık Hizmetleri Genel Müdürlüğü (SHGM). Geleneksel, Tamamlayıcı ve Fonksiyonel Tıp Uygulamaları Dairesi Başkanlığı. Homeopati Uygulaması Hakkında Bilgilendirme https://shgmgetatdb.saglik.gov.tr/TR,24680/ homeopati-uygulamasi-hakkinda-bilgilendirme.html Erişim Tarihi: 10.01.2022.

Sodhi, V. (2020).Ayurveda: the science of life and mother of the healing arts. Joseph E Pizzorno, Michael T Murray (Fifth Edition), *Textbook of Natural Medicine* (p:257-263.e1) https://doi.org/10.1016/B978-0-323-43044-9.00033-9

Steinberg, D., & Beal, M. W. (2003). Homeopathy and women's health care. Journal of obstetric, gynecologic, and neonatal nursing: JOGNN, 32(2), 207–214. https://doi.org/10.1177/0884217503252125.

Szamatowicz, M., & Szamatowicz, J. (2020). Proven and unproven methods for diagnosis and treatment of infertility. *Advances in medical sciences*, *65*(1), 93–96. https://doi.org/10.1016/j.advms.2019.12.008

Taştan, K., Çayır, Y., Makas, Y. N., Set, T., Hülakü, A., & Tekşan, T. (2015). Atatürk Üniversitesi Tıp Fakültesi"nde çalışan doktorların hipnoterapi ile ilgili görüşleri, eğitim durumları ve bilgi edinme kaynakları. *Smyrna Tıp Dergisi, (2)*, 1-6.

Vander Borght, M., & Wyns, C. (2018). Fertility and infertility: Definition and epidemiology. *Clinical biochemistry*, *62*, 2–10. https://doi.org/10.1016/ .clinbiochem.2018.03.012

WHO. Research guidelines for evaluating the safety and efficacy of herbal medicines. Regional office for the Western Pacific, Manila.1993. World Health Organisation.

Yıllar Erkek, Z., & Pasinlioğlu, T. (2016). Doğum ağrısında kullanılan tamamlayıcı tedavi yöntemleri. *Anadolu Hemşirelik ve Sağlık Bilimleri* Dergisi, 19(1), 71-77.

Zhou, J., & Qu, F. (2009). Treating gynaecological disorders with traditional Chinese medicine: a review. *African journal of traditional, complementary, and alternative medicines: AJTCAM*, *6*(4), 494–517. https://doi.org/10.4314 /ajtcam.v6i4.57181

CHAPTER 8

BREAST NEOPLASMS

Nurten ÖZÇALKAP[1] , Çiğdem KARAKAYALI AY[2]

[1]Expert Midwifery,Inonu University, Institute of Health Sciences Department of Midwifery, Malatya/Turkey. E-posta: nur_dan044@hotmail.com, ORCID ID: 0000-0003-2440-968X
[2] Res.Asistant.,Inonu University, Faculty of Health Sciences, Midwifery Department,Malatya/Turkey. E-posta: cigdem.karakayali@inonu.edu.tr, ORCID ID: 0000-0002-5282-973X.

INTRODUCTION

Breast neoplasms are divided into two groups as benign (benign) and maning (malignant). Breast cancer is among the most important causes of morbidity and mortality in women. Most clinical breast changes in women are benign; only 3% to 6% of cases are due to breast cancer. However, there are no current, evidence-based treatment recommendations for various benign differential diagnoses (Taşkın, 2020). The statistics on breast cancer are frightening. Breast cancer is the most common type of cancer among women in the world and in Turkey (SB, 2018). The incidence of breast cancer is high in Caucasian women aged 40 years and over. In recent years, the incidence of new cases of breast cancer has been found to be similar, especially in white and African American women aged 50-59 years (Jemal, et al.2011). It has been determined that 44.5% of women with new case breast cancer in Turkey are in the age range of 50-69, and 40.4% are in the age range of 25-49 (SB, 2018). Breast cancer accounts for 28% of cancers and 18% of causes of death in women (American cancer society,2019 & Al-Shamsi et al.2021 & Jemalet al., 2011).

Due to early diagnosis and more effective treatment combinations, breast cancer mortality rates have been decreasing since 1991. It is estimated that the decrease in mortality rates is due to early diagnosis and increased awareness, as well as better treatment methods. Health professionals should raise awareness about breast cancer neoplasms, and should undertake the roles of educator, counselor, therapeutic and care in helping women gain healthy life behaviors in awareness, prevention and screening programs (Taşkın 2020 & Najjar, et al. 2010 & Jemalet al., 2011).

1. BENIGN BREAST DISEASE

Benign breast changes can be definitively distinguished from malignant lesions through the selective use of available diagnostic research and interdisciplinary collaboration. Prospective studies are desired for early detection of breast cancer in lesions with malignancy risk (Taşkın, 2020 & American cancer society, 2019).

1.1.Fibrocystic Diseases

Fibrocystic disease of the breast is multiple cysts formed in the breast tissue. Multiple cysts are seen in approximately 1/3 of premenopausal women. It is rare for new cysts to form after menopause. In the premenopausal period, when progesterone is not secreted, excessive stimulation of estrogen accelerates the formation of multiple cysts (Paepke et al., 2018).

Clinically, they are usually found as bilateral multiple pillar cysts and sometimes as unilateral multiple pillar cysts. These cysts, which increase in the premenstrual period, show signs of pain, fullness and tenderness in the breasts. However, these cysts can be found without these symptoms. Cysts are located especially in the upper outer quadrant of the breast. They are palpable as soft and irregular thickenings on palpation (Stachs et al., 2019).

Preliminary diagnosis with history and physical examination, x-ray control of breast tissue with mammography, and differentiation of cysts from solid tumors with ultrasound. A definitive diagnosis is made by biopsy (Amin et al., 2013).

Many applications are recommended for the symptomatic treatment of fibrocystic disease. The most common is avoidance of caffeine and nicotine and supplementing the diet with vitamins. Other treatment options are hormone therapy and surgery (Taşkın, 2020).

1.2. Fibroadenoma

Fibroadenoma is the most common benign neopalzyme. It is more common in young women. They are painless, mobile and hard masses. These lesions are mostly located in the upper quadrant of the breast. These lesions are usually discovered incidentally. The changes in fibroadenomas during the menstrual phase are unlike fibrocystic changes. In contrast, they can grow rapidly during pregnancy and exogenous estrogen therapy (Amin et al., 2013).

Although the incidence of malignant change in these lesions is very low, the tumor is simply removed in the treatment. Because no lesion is benign. In addition, their growth over time causes constant anxiety in women (Paepke et al., 2018).

1.3. Ectasia in the Breast Canal

It is the inflammation of the canal in the nipple. Symptoms; There is pain in the nipple, itching, a sticky, dark, colored discharge and redness around the nipple. If there is an abscess, it is drained. Antibiotics are used for treatment (Taşkın, 2020).

1.4. Duct Papilloma

It is a rare disease. It develops in the last part of the nipple canals. The first symptom is a bloody or serous discharge from the nipple. Since the mass is very small, it may not be palpable. Care should be taken in terms of its malingnea. In the treatment, the papilloma and its duct system are excised (Amin et al., 2013).

2. BREAST CANCER (MALIGN NEOPLASIS)

Breast cancer is a complex and systemic disease in which genetic and/or epigenetic malignant changes play an important role. On the basis of breast cancer; genetic mutations cause loss or reduction of function. As a result of activation of oncogenes and inactivation of tumor suppressor genes, malignant cells begin to invade and proliferate. Genomic instability may develop with tumor suppressor gene and prorooncogene mutations. Tumor suppressor genes that are effective in the development of breast cancer; p53, BRCA1, BRCA2, PTEN and ATM. Oncogenes are formed by mutation and transformation of protooncogenes, causing the malignant phenotype to occur. Proto-oncogenes effective in the development of breast cancer; HER28neu, EGFR, Ras, Myc and β-catenin (Liedtke et al., 2017 & Arkoob et al. 2010).

2.1. Breast Cancer Risk factors

The cause of breast cancer is unknown. There are many risk factors with the increase in its incidence. These; Being over 40 years old, family history of breast cancer (mother and sister), nulliparity, primiparous over 30 years of age, not breastfeeding, alcohol and smoking, long time between menarche and first pregnancy, early menarche, late menopause, estrogen and progestin and menopausal hormone treatment, previous breast, colon, ovarian, thyroid, and endometrial cancer, a history of atypical hyperplasia, dense breasts on mammography, certain ethnicities, known harmful gene mutation, excessive exposure of breasts to radiation, prior breast biopsy with specific

pathology, high-fat diet after menopause, past benign breast neoplasia and excessive alcohol consumption. These factors can identify only 25% of women who may develop breast cancer. The presence of a long latent phase of 15-20 years before the clinical development of carcinoma precludes the identification of many risk factors (ACOG, 2017 & Miaskowski et al. 2014).

2.2. Breast Cancer Physiopathology

Breast cancer is divided into 3 large groups according to histopathology. Ductal-ductal, lobular, and nipple-nipple (Paget's disease) carcinomas. Cancer can be both invasive and non-invasive (in-situ). It is common opinion that micrometastases will occur as soon as breast cancer is palpable (1 cm in diameter) (Taşkın, 2020).

2.2.1. Ductal (duct) carcinoma

It takes its origin in the lactiferous ducts. Breast cancers are most commonly ductal carcinoma. The tumor staff is immobile, unilateral, and has limited pain (Paepke et al. 2018).

2.2.2. lobular carcinoma

It originates from the mammary lobes. It is rarely palpable in the in-situ stage. It is most common in the premenstrual period. They are found bilaterally. Invasive lesions have a high incidence of hormone receptors (Stachs et al. 2018-9).

2.2.3. Nipple carcinoma (paget's defect)

It takes origin from the nipple. It usually occurs in association with ductal carcinoma. The most common symptom is nipple discharge and bleeding. Erosion of the nipple can also be seen (Zhu et al., 2021).

2.3. Breast Cancer Symptoms

The most common symptom of breast cancer is the presence of a lump or mass in the breast. A painless, firm and irregularly sided mass is likely to be malignant. The majority (49%) of cancer-related masses are located in the upper-outer region, 17% in the central region, 16% in the upper-inner region, 12% in the lower outer region, and 6% in the lower-inner region (Taşkın, 2020 & Miaskowski et al., 2014). The structure of the mass is usually

hard and immobile; It moves with the surrounding breast tissue and can be easily differentiated from fibroadenoma in this respect. Tumor infiltrating Cooper ligaments may cause skin retraction (Kalli et al., 2018). With the slowing of the lymph flow, the breast skin may have the appearance of an orange peel (Peau D'orange). Erythema and ulceration of the breast skin may be observed due to lymphatic obstruction. If the tumor is located in the central quadrant, the nipple can be retracted towards the central quadrant where the tumor is located (Miaskowski et al., 2014). The presence of discharge from the nipple, unilateral discharge, spontaneous, serous and/or bloody discharge are important in terms of malignancy. Pain and asymmetry in the breast, swelling in the armpit, and enlarged lymph nodes are other symptoms of breast cancer (Arkoob et al., 2010 & Amin et al. 2013).

2.4. Diagnosis in Breast Cancer

While some women are diagnosed with symptoms, breast cancer often does not show any symptoms. Therefore, it is important for women to have regular screenings. Treatment success is higher in breast cancers diagnosed in the early stages. Early diagnosis methods; breast self-exam (BSE), clinical breast examination (CBE), and mammography (Najjar et al., 2010).

2.5. Breast Cancer Stages

The stage of breast cancer, tumor size after cancer diagnosis, lymph node metastasis and whether there is a disease in a region other than the breast are determined. Determining the cancer stage is an important indicator for cancer recurrence or metastasis to other organs. The TNM system is used in the staging of Breast Cancer (Table 1). Accordingly, T represents the primary tumor, N represents the axillary lymph nodes, and M represents distant metastases (Akyol, 2018 & Ljuslinder, 2009).

Tablo.1 Staging İn Breast Cancer (Ljuslinder, 2009)

		Stage	Primary tumour (T)*	Regional lymph node status (L)	Distant metastasis (M)
T- Tumour		0	Tis	N0	M0
T1	Tumour ≤ 2 cm	I	T1	N0	M0
T2	Tumour ≥ 2 cm but ≥ 5 cm		T0	N1	M0
T3	Tumour ≥ 5 cm	**IIA**	T1	N1	M0
T4	Tumour of any size with direct extension to chest wall or skin		T2	N0	M0
N- Lymph node		**IIB**	T2	N1	M0
N0	No cancer in regional node		T3	N0	M0
N1	Reggional movable metastasis	**III A**	T0	N2	M0
N2	Non-movable regional metastases		T1	N2	M0
N3	Cancer in the internal mammary lymph nodes		T2	N2	M0
M- Metastasis			T3	N1/N2	M0
M0	No distant metastases	**III B**	T4	Any N	M0
M1	Distant metastases	**III C**	Any T	N3	M0
		IV	Any T	Any N	M1

Criteria for staging breast tumours according to the UICC ICD-10 TNM classification.
*Size measurements are for the tumour's greatest dimension.

2.6. Treatment in Breast Cancer

Different treatment modalities are used in the treatment of breast cancer. These; surgical treatment, chemotherapy, radiotherapy, hormonal therapy and targeted therapies. In the selection of treatment modality; Strategies for disease and symptom management, prolonging life expectancy and increasing quality of life are important. The primary purpose of surgical treatment; is to remove the tumor from the breast and determine the stage of the disease (Paepke et al., 2018). These surgical approaches; It can be examined in two main groups as breast-conserving surgery and non-breast-sparing surgery (mastectomy) (Miaskowski et al. 2014). Chemotherapy can be given adjuvant, neoadjuvant or palliative depending on the clinical condition of the patient. In chemotherapy, docetaxel, paclitaxel, platinagens (cisplatin, carboplatin), Vinorelbine (Navelbin), Capecitabine (Xeloda), Liposomal doxorubicin (Doxil), Cyclophosphamide (Cytoxan), Carboplatin (Paraplatin) etc. drugs are used. Radiotherapy is one of the cornerstones of cancer treatments. It can be applied in patients with breast cancer, usually after the recovery period of 6-8 weeks after surgical treatment. However, patients with large tumor size can also be given radiotherapy before surgical treatment to reduce the tumor size and make it operable. Hormone therapy drugs used in

breast cancer; tamoxifen, raloxifene, aromatase inhibitors and fulvestrant (Akyol, 2018 & Greenwalt et al. 2019).

Hormonal and physical changes in women due to breast cancer treatments can cause vaginal dryness. Vaginal dryness can cause problems such as decreased sexual desire due to pain during sexual intercourse. In improving vaginal dryness; smoking cessation, use of vaginal lubricant and moisturizer, kegel exercises and patient education may be recommended (Greenwalt et al. 2019).

Targeted therapies aim to inhibit the growth and spread of cancer cells and are designed to directly destroy the tumor. In one in 5 women diagnosed with breast cancer, cancer cells overproduce the HER-2 protein, which promotes growth on their surface. Known as HER2-positive breast cancer, these cancers tend to grow and spread more aggressively. Trastuzumab (Herceptin), Pertuzumab (Perjeta), Ado-trastuzumab emtansine (Kadcyla, TDM-1), Lapatinib (Tykerb) and Neratinib (Nerlynx) are drugs used in targeted therapies. Drugs that are monoclonal antibodies (Trastuzumab, Pertuzumab, Ado-trastuzumab) are given parenterally in the treatment of both early and late stage breast cancer. Kinase inhibitors (Lapatinib, Neratinib) drugs can be used in combination treatments (Kalli et al., 2018 & Ljuslinder, 2009).

2.7. Breast Cancer Prognosis

The natural course of breast cancer after diagnosis shows clinical and biological differences between patients depending on prognostic factors such as tumor size, lymph node involvement, histological features of the tumor, hormone receptors, patient's age, weight and pregnancy status. Especially in early stage breast cancer patients, determining prognostic factors, survival, whether adjuvant chemotherapy can be given and the type of chemotherapy can be determined (Zhu et al. 2021).

Inflammatory breast cancers are seen at a rate of 1-2% among other breast cancers and have a poor prognosis. Invasive ductal carcinomas account for 75% of all breast cancers. It is the most common type of breast cancer. It has a worse prognosis than other types of cancer by metastasizing to axillary lymph nodes (Paepke et al., 2018 & Al-Shamsi et al., 2021).

2.8. Care in Breast Cancer

Breast cancer patients face many physical, emotional and social problems. At the same time, the intense and long-term continuation of cancer treatments and the side effects caused by these treatments negatively affect the daily life activities of the patients. In this process, health professionals should provide holistic and supportive care to improve the quality of life of patients and their relatives (Akyol, 2018). It has been determined that the education and counseling provided by health professionals provide support, coordination and effective communication, and reduce the symptoms of patients diagnosed with cancer. The effects and side effects of chemotherapy drugs should be known, patients should be questioned, evaluated and appropriate interventions should be made according to chemotherapy agents. In the management of the surgical treatment process, patients should provide quality physical care, education and psychosocial support in the perioperative period. In the postoperative period, body image changes, pain and sensation changes, infection or seroma in the operation area, lymphedema, home care and discharge planning should be done. Health professionals should provide adequate information and support to patients about what surgical treatments will lead to, the aesthetic result of the surgery, its effect on sexual harmony and body image, and its functional results (Taşkın, 2020 & Najjar et al.2010).

3. CONCLUSION

As a result the name is no longer acceptable as cancer. With early diagnosis and life, life increases and life expectancy is extended. those who can lead normal lives of their students, be productive and happy.

REFERENCES

Akyol, k. (2018). Meme kanseri tanısı için özniteliklerin öneminin değerlendirilmesi üzerine bir çalışma. *Academic Platform Journal of Engineering and Science,* 6(2), 109-115.

Al-Shamsi, H. O. Abu-Gheida, I. Abdulsamad, A. S. Awadhi, A. A. Alrawi, A. Musallam K. M. Arun, B. & Nuhad K. Ibrahimcorresponding, N. K. (2021). Molecular spectra and frequency patterns of somatic mutations in arab women with breast cancer. *Oncologist,* 26(11), 2086–e2089

American cancer society. Non-cancerous Breast Conditions. Last Revised: September 10, 2019.

American College Of Obstetricians And Gynaecologists (2021). Breast cancer risk Assessment and Screening in Average-Risk Women July 2017.

Amin, A. L. Purdy, A. C. Mattingly, J.D. & Kong,A. L. (2013). Benign Breast Disease. *Surg Clin N Am*, 93, 299–308.

Arkoob, K. Nsour, M. Al Nemry, O. & Al Hajawi, B. (2010). Epidemiology of breast cancer in women in Jordan: patient characteristics and survival analysis. *Eastern Mediterranean Health Journal,* 16(10), 1032-1038, 2010.

Greenwalt, L. Zaza, N. Das, S. & Li, B. D. (2019). Precision medicine and targeted therapies in breast cancer, *surg Oncol Clin N Am*, 29(1), 51-62.

Jemal, A. F. Bray, M. M. Center, Ferlay, J. E. & Ward, D. (2011). Forman, "Global cancer statistics", *CA Cancer J. Clin.* 61(2), 69–90.

Kalli, S. Semine, A. Cohen, S. Naber, S. P. Makim, S.S. & Bahl, M. (2018). American Joint Committee on Cancer's Staging System for Breast Cancer, Eighth Edition: What the Radiologist Needs to Know. Radio Graphics, 38, 1921–1933.

Liedtke, C. & Kolberg, H. C.,(2017). Breast cancer and genomic testing. *British Journal of Surgery,* 104(7), 799–801.

Ljuslinder, I.(2009). Studies of LRIG1 and the ERBB receptor family in breast and colorectal cancer. : https://www.researchgate.net/publication/41034402

Miaskowski, C., Paul, S.M., Cooper, B., West, C., Jon, D., Levine, J. D., Elboim, C., Hamolsky, D., Abrams, D., Luce, J., Dhruva, A., Langford, D. J., Merriman, J. D., Kober, K., Baggott, C., Leutwyler, H., & Aouizerat, B. E. (2014). Identification of patient subgroups and risk factors for persistent arm/shoulder pain following breast cancer surgery. *Eur J Oncol Nurs,* 2014 Jun;18(3):242-53.

Najjar, H. & Easson, A. (2010). Age at diagnosis of breast cancer in Arab nations, *International Journal of Surgery,* 8(6), 448-452.

Paepke, S. Metz, S. Salvago, A. B. & Ohlinger, R. (2018). Benign Breast Tumours - Diagnosis and Management. *Breast Care*, 13, 403-412.

Stachs, A. Stubert, J. Reimer, T. & Hartmann, S. (2019). Benign breast disease in women. Dtsch Arztebl Int, 116(33-34), 565–574.

Taşkın, L. (2020). Doğum ve kadın sağlığı hemşireliği, Ankara: Akademisyen kitapevi.

T.C. Sağlık Bakanlığı. (2018). Sağlık İstatistikleri Yıllığı, Ankara 2019.

Zhu, H. & Doğan B. E. (2021). American Joint Committee on Cancer's Staging System for Breast Cancer, Eighth Edition: Summary for Clinicians. Eur J Breast Health, 17(3), 234–238.

CHAPTER 9

TUMOR MICROENVIRONMENT IN TRIPLE NEGATIVE BREAST CANCER

Pınar CELEPLİ[1] , Baki TÜRKOĞLU[2]

[1] Dr.,Ankara Training and Research Hospital, Department of Pathology, Ankara, Turkey, pcelepli@yahoo.com, ORCID: 0000-0001-7643-6263
[2] Dr.,Gülhane Training and Research Hospital, Department of General Surgery, Ankara, Turkey, drturkoglubaki@gmail.com, ORCID: 0000-0002-5777-7545

INTRODUCTION

Breast cancer is the most common malignancy in women. Since it is a heterogeneous disease with different histological and molecular features, clinical treatment and prognosis vary among patients. The identification of molecular subtypes is important for clinical prognosis and patient survival, and thus the implementation of effective treatment modalities. There are four basic molecular subtypes according to the hormone receptor and human epidermal growth factor receptor-2 (HER2) expression status: Luminal A, Luminal B, HER2-positive, and triple-negative (Goldhirsch et al., 2013). Triple-negative breast cancer (TNBC) is defined as a breast cancer subtype presenting with the lack of estrogen receptor (ER), progesterone receptor (PR) and HER2 expression (Wolff et al., 2014). According to gene expression profile analysis, TNBC and basal-like breast cancer profiles show a high overlap of 60-90%. According to its expression features, TNBC is divided into the following subtypes: basal-like, immunomodulatory, mesenchymal, mesenchymal stem-like, luminal androgen receptor, and unstable (Abramson et al., 2015). While a tumor being triple-negative is based on the absence of hormone receptors (ER/PR) and HER-2, basal-like breast cancer is associated with cytokeratins with a basal epithelial cell gene expression pattern (CK5, CK6, CK14, and CK17) and epidermal growth factor receptor (EGFR). The gold standard in the diagnosis of basal-like breast cancer is the determination of gene expression profile using complementary DNA microarrays (Kuo et al., 2012).

TNBC accounts for approximately 15-20% of all breast cancer cases and usually occurs in premenopausal women under 40 years (Morris et al., 2007). TNBC is the most aggressive subtype of breast cancer due to its drug resistance, high probability of metastasis, and lack of specific targets and targeted therapies (Anders & Carey, 2008). The incidence of TNBC has increased in recent years, and it also has higher morbidity and mortality compared to the other subtypes of breast cancer (Hwang et al., 2019). TNBC has attracted the attention of clinicians and researchers due to its large tumor size, lymph node involvement at the time of diagnosis, progression to high grade, lung/bone/brain metastases, and most importantly the lack of a suitable target for treatment. Recent studies have shown that tumors in TNBC include not only neoplastic cells but also a significantly altered surrounding stroma.

The tumor microenvironment plays a critical role in tumor development and progression, and is also considered a measurable parameter of response to therapy. Understanding the tumor microenvironment (TME) and its regulators in TNBC will be useful for designing immune-based targeted therapies.

1. TUMOR MICROENVIRONMENT

Unlike other breast tumor subtypes, TNBC is characterized by a highly complex and heterogeneous TME. The rapid proliferation of cancer cells and reprogramming in TME induces hypoxia. As a result, tumor cells and those surrounding TME constantly adapt to new conditions and promote tumor growth. TME creates a niche in touch with tumor consists of endothelial and immune cells, as well as fibroblasts interacting each other; thus, it can be used as a potential therapeutic target for TNBC (Deepak et al., 2020). It induces the transformation of TME epithelial cells into TNBC stem cells. Interactions between these cells in TME facilitate a variety of biological events that promote cancer growth, invasion, angiogenesis, and metastasis (Liu et al., 2014). TME consists of cancer cells, cancer-associated fibroblasts (CAFs), immune cells, cancer stem cells (CSCs), extracellular matrix (ECM) components, blood vessels, adipocytes, and differentiated cells (Otranto et al., 2012).

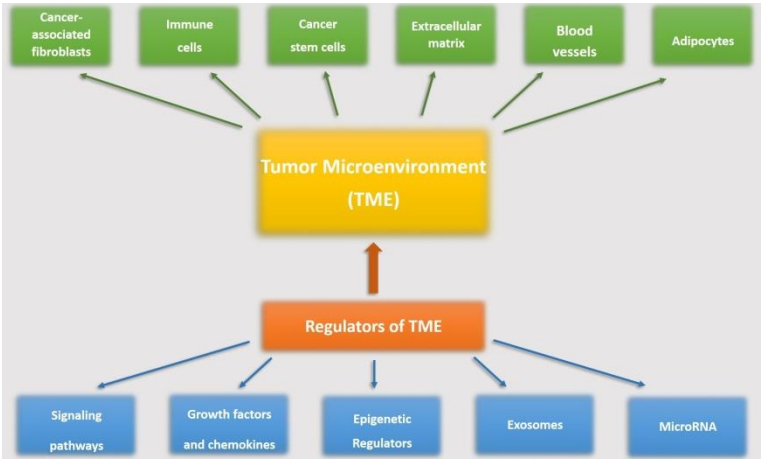

Figure 1: Tumor Microenvironment

1.1. Cancer-Associated Fibroblasts

CAFs are the most abundant stromal cells in TME and play a critical role in cancer progression and drug resistance. They produce growth factors and chemokines, and also facilitate the entry of immune cells into TME to ensure the growth and survival of tumor cells (Martin et al., 1997). They produce matrix metalloproteinases (MMP), which reconstruct the ECM and create a hypoxic environment, thus facilitating the remodeling and movement of cancer cells, and stimulating invasion and metastasis (Vadde et al., 2017). Hypoxia or increased inflammation in the tumoral tissue induces changes in ECM. Hypoxia stimulates hypoxia-inducible factor-1a (HIF-1a), which transactivates genes that regulate tumor growth, macrophage polarization, and metastasis (Klein, 2018). It also causes the secretion of angiogenic factors by tumor cells and contributes to tumor development by neovascularization (Hui & Chen, 2015).

1.2. Immune Cells

The presence of immune cells in TME is one of the recently defined issues in the prediction of treatment response and prognosis. These cells can inhibit or promote tumor proliferation depending on signals in TME (Tsai et al., 2014). Tumor-associated macrophages (TAMs) constitute an important cell population in breast cancer since they exhibit a characteristic phenotype to promote tumor growth, angiogenesis and tissue remodeling, and suppress adaptive immunity. TAMs have been shown to modulate PD-1/PD-L1 expression in the TME both directly and indirectly. In the presence of granulocyte-macrophage colony-stimulating factor and macrophage colony-stimulating factor, macrophages direct bone marrow hematopoietic stem/progenitor cells for monocytic differentiation through changes in cell surface antigens and gene and cell signaling pathways. This induction happens in the direction of M1 or M2. M1 macrophages are characterized by the expression of high amounts of inducible nitric oxide synthase and tumor necrosis factor-α. They are known to exert pro-inflammatory effects and anti-tumor activity by stimulating immune responses. M2 macrophages typically express arginase 1 and high levels of cytokines, growth factors, and protease, which support their pro-oncogenic function. They are involved in stimulating tumor angiogenesis, matrix remodeling, tumor cell migration, invasion, and

immunosuppression (Solinas et al., 2009). CD163+ M2 macrophages, which are highly expressed in breast cancers, have been shown to be correlated with greater proliferation, poor differentiation, hormone receptor negativity, and ductal-type histology (Helfen et al., 2018).

Tumor-infiltrating lymphocytes (TILs) are one of the main components of TEM. Most TILs are T cells that can divide into CD4+ helper cells, CD4+, CD25+, FOXP3+ phenotype cells, and natural killer and CD8+ T cells. (Allen & Louise Jones, 2011). If the environment surrounding tumor cells is rich in inflammatory cells, the immune system cannot recognize and eliminate cancer cells. On the other hand, lymphoid lineage B cells and regulatory T cells that regularly infiltrate TME cause immunosuppression by releasing cytokines and support tumor progression (Helfen et al., 2018; Liu et al., 2014). TIL evaluation in breast cancer is gaining importance as a prognostic marker. Higher TIL levels in TNBC and HER2+ breast cancer are associated with better outcomes and response to neoadjuvant therapy. TILs have a strong prognostic value in predicting recurrence-free/disease-free survival and overall survival in early stage TNBC treated with standard adjuvant or neoadjuvant chemotherapy (Tan et al., 2020). Immune cells can be adapted for use in immunotherapies with the combination of other targeted therapies.

1.3. Cancer Stem Cells

CSCs have the ability to self-renew and differentiate. They are responsible for radiation and drug resistance, as well as playing a role in cancer onset and metastasis processes (Liu et al., 2017). As a result of the asymmetric division of CSCs, a stem cell and a progenitor cell are formed. At the end of this asymmetric division, both CSCs renew themselves and precursor cancer cells that will acquire phenotypically different characteristics are formed. Progenitor tumor cells also have the ability to proliferate rapidly. Progenitor tumor cells, on the other hand, have the ability to proliferate rapidly (Yoo & Kwon, 2015).

According to one of the hypotheses on the origin of CSCs, these cells originate from normal stem cells (Hartwig et al., 2014). With the deregulation of the self-renewal and differentiation pathways of normal stem cells, cancer cells with self-renewal and differentiation capacity are formed (Bozorgi et al.,

2015). This hypothesis is supported by the similarities between normal stem cells and CSCs, their susceptibility to mutation and oncogenic transformation due to their long lifespan, and the similarity of surface marker properties of breast cancer stem cells and basal mammary stem cells/progenitor cells (Tomita et al., 2016). In addition, it has been suggested that CSCs develop through the epithelial-mesenchymal transition of normal cells. Cells undergoing this transition are prone to transformation, and also they have similar characteristics to normal and neoplastic stem cells (Martelotto et al., 2014). In breast cancer, CSCs have the features of self-renewal, differentiation, resistance to treatment, and metastasis and mammosphere formation. Signaling pathways, such as Notch, Hedgehog, and Wnt play a role in the self-renewal of CSCs in this cancer (Borah et al., 2015).

CSCs remodel their TMEs by promoting immune cells and interactions with other cells; thus, they provide a supporting niche. They are known to express three main stem cell markers in breast cancer, namely CD44, CD24, and ALDH1. TNBCs have abundant CD44+/CD24- stem cells compared to other breast cancer subtypes. It has been reported that CSCs contribute to chemotherapy resistance and tumor metastasis in TNBC (O'Conor et al., 2018). TNBC stem cells are more resistant to conventional treatments than differentiated cells; therefore, recent studies aim to identify strategies that target CSCs in TNBC (Jamdade et al., 2015).

1.4. Extracellular Matrix

ECM is a complex protein network that surrounds and stabilizes cells. It consists of three major extracellular proteins: structural proteins (e.g., collagen and elastin), glycoproteins (e.g., fibronectin), and proteoglycans (e.g., chondroitin sulfate). Maintaining tissue homeostasis plays a critical role in cell proliferation and differentiation (Rigoglio et al., 2020). While initially considered a stable structure that only provides support, studies have shown that ECM is surprisingly dynamic and versatile, and it also has a key role in cellular processes, such as cell growth, proliferation, and migration. The main protein component of ECM is collagen, and the degradation of collagen IV by proteases leads to cancer cell invasion through the basement membrane; therefore, its integrity is important in cancer development. ECM also

facilitates intercellular communication by guiding the passage of cytokines and growth factors between cells (Lu et al., 2012).

ECM is at the forefront of all stages of in tumor development from initiation, growth and progression to metastasis. Many cellular components of TME (especially CAFs) contribute to metastatic cell proliferation through different mechanisms that force ECM to remodel. CAFs facilitates this via the accumulation of ECM proteins. TAMs produce various matrix metalloproteinases (MMP-2, MMP-9) and cause the formation of tumoral ECM. Cancer cells also produce and release reactive oxygen species that initiate the activation of these enzymes. In addition, MMPs stimulate the formation of new blood vessels and contribute to angiogenesis by causing the release of factors embedded in ECM, such as vascular endothelial growth factor (VEGF) (Najafi et al., 2019).

1.5. Blood Vessels

Tumor-associated blood and lymphatic vessels are the primary pathways of innate and adaptive immune cells that play both pro and anti-tumoral roles during tumor development and response to therapy (Fridman et al., 2012). Angiogenesis is a critical process required for tumor progression. Newly formed blood vessels supply nutrients and oxygen that contribute to the growth and development of the tumor. In addition, the endothelium plays a role in the entry of cancer cells into the blood vessel (intravasation), which is an important stage in cancer metastasis.

Endothelial cells are one of the main sources of CAFs. The heterogeneous CAF group is the main inducer of the migration and invasion abilities of cancer cells; therefore, it is indirectly responsible for endothelial metastasis (Sobierajska et al., 2020). A denser tumor vasculature is associated with increased tumor growth and hematogenous metastasis. This is due to increased oxygen supply, nutrients, and metastatic spread pathways (Nico et al., 2008). Important markers of blood and lymphatic vascular network include lymphatic vessel endothelial hyaluronan receptor (LYVE-1), VEGFR3, CD31, and CD34. Lymphatic vessels predominantly secrete LYVE-1 (Wang et al., 2017). The application of anti-angiogenic gene therapy targeting angiogenesis may hold more ground in the prevention and treatment of early-stage cancer in future.

1.6. Adipocytes

Adipocytes are the largest components of breast tissue; therefore, they are involved in breast cancer development and treatment. Obesity is now considered to be a complex physiological condition associated with multiple molecular changes that can modulate the behavior of breast tumor cells, as well as the surrounding microenvironment. Abnormal adipocytes, such as cancer-associated adipocytes (CAAs) adjacent to the tumor are predominantly found in the invasive portions of breast cancer. In addition, there are many studies showing that CAAs exhibit different molecular and cellular properties and can increase the proliferation and invasion capacity of cancer cells by providing metabolic advantages. In breast cancer, invasive cancer cells dramatically affect surrounding adipocytes and cause phenotypic changes both in vitro and in vivo (Muller, 2013). CAAs play an important role in breast cancer proliferation, angiogenesis, invasion, dissemination, and metastasis by secreting multiple adipokines, such as leptin, adiponectin, interleukin 6, chemokine ligand 2, and chemokine ligand 5 (Wu et al., 2019).

2. TUMOR MICROENVIRONMENT REGULATORS

In TNBC, TME is regulated by signaling pathways, growth factors, chemokines, exosomes, epigenetic regulators, and microRNAs (Deepak et al., 2020), which are discussed under separate headings in this section.

2.1. Signaling Pathways

In TNBC, there are various signaling pathways, such as Notch, Hedgehog (SHH), Wnt/ β-catenin, JAK-STAT3, Sphingosine 1-phosphate (S1P), stimulator of interferon genes (STING), chemokine-like interleukin-1β (IL-1β), and TGF-β (Irey et al., 2019; Nallanthighal et al., 2019; Rostami et al., 2019). Notch is a highly conserved signaling pathway that regulates cellular processes important for cell-to-cell communication. Notch signal modulates and improves the immune system by communicating between immune cells and cancer cells in TME (Al-Hussaini et al., 2011). Speiser et al. reported that TNBC overexpressed Notch 1 and Notch 4 receptors in vascular endothelial cells and tumors with a subcellular location distinct from hormone-positive breast cancers (Speiser et al., 2012). SHH signaling is a regulator of angiogenesis in TNBC. Canonical SHH signaling enhances tumor

angiogenesis via metalloproteases, CYR61 and VEGF receptor 2 (VEGFR2), resulting in TNBC outgrowth and metastasis. In addition, SHH produced by CAFs regulates cancer progression and TME (Di Mauro et al., 2017). The activation of Wnt/β-catenin signaling in TME is associated with immunomodulation and suppression of the antitumor immune response (Goldsberry et al., 2019). JAK-STAT3 signaling potently suppresses the antitumor immune response while stimulating proliferation, survival, invasion and metastasis of tumor cells (Johnson et al., 2018). Cancer-derived factors within TME also activate macrophage-mediated therapeutic resistance via the JAK-STAT3 pathway (Irey et al., 2019). S1P has been found to promote tumor growth, angiogenesis, chemoresistance and metastasis through intracellular and extracellular signaling, and it also modulates anticancer immune response (Schneider, 2020). S1P and its receptor S1PR1 confer immunological tolerance in TME, and the immunosuppressive function of S1PR1 leads to development of premetastatic niches (Rostami et al., 2019). STING is important in TME remodeling associated with an increase in antigen-presenting cells and tumor antigen-specific CD8+ T cells (Zhang et al., 2019). Lastly, TGF-β acts as a potent inhibitor of various signaling pathways in cancer cells. In addition, there are studies showing that TGF-β stimulates angiogenesis, induces extracellular matrix degradation, and suppresses antitumor immune response (Basolo et al., 1994; McEarchern et al., 2001).

2.2. Growth Factors and Chemokines

Excess growth factor receptors and chemokines in TME are associated with an aggressive course of cancer and poor prognosis (Nakai et al., 2016). Therefore, clinical studies are conducted to target TME with EGFR inhibitors in the treatment of TNBC. Recent studies have reported that EGFR mediates the escape of tumor cells from immune cells in TME by upregulating the PD-L1 and TGF-β immunosuppressive pathways (Concha-Benavente & Ferris, 2017).

2.3. Exosomes

Exosomes are 50-100 nm-sized nanovesicles, which have recently been seen as promising mediators in tumor-host interaction. They are recognized as key regulators of TME and tumor progression (Kalluri, 2016). Tumor-derived exosomes accelerate the activation of CAFs during TME remodeling and enhance the migration of cancer cells via Wnt signaling. They increase glycolysis within TME by modulating mitochondrial functions. In addition, they develop resistance to endocrine therapy in breast cancer cells through the mitochondrial DNA-mediated activation of oxidative phosphorylation (Li & Nabet, 2019). Tumor-derived exosomes activate oncogenic signals by stimulating natural killer cells, macrophages, and B and T lymphocytes. They increase immune suppression by inhibiting cytotoxic cells (Moroishi et al., 2016).

2.4. Epigenetic Regulators

Studies have reported that the communication between cancer and non-cancer host cells in TME is driven by epigenetically regulated genes (Garcia-Gomez et al., 2018). With DNA methylation and histone modifications, miRNAs support TME by regulating gene expression and translation (Mathot et al., 2017).

2.5. MicroRNAs

MicroRNAs regulate multiple signaling pathways of TME that promote tumor progression, but their role in this regulation is not yet fully understood. Endogenously processed small oncogenic miRNAs that control angiogenesis in TME with both paracrine and autocrine signaling have been identified in breast cancer (Hunter et al., 2019).

CONCLUSION

TNBC cells reside in a complex TME consisting of blood vessels, fibroblasts, adipocytes, immune cells, stem cells, and genetically aberrant cells surrounded by ECM. The dynamic interaction between these various components ultimately determines the prognosis of breast cancer. TME is increasingly recognized as an important player in tumor progression and a promising therapeutic target in TNBC.

REFERENCES

Abramson, V. G., Lehmann, B. D., Ballinger, T. J., & Pietenpol, J. A. (2015). Subtyping of triple-negative breast cancer: implications for therapy. Cancer, 121(1), 8-16.

Al-Hussaini, H., Subramanyam, D., Reedijk, M., & Sridhar, S. S. (2011). Notch signaling pathway as a therapeutic target in breast cancer. Mol Cancer Ther, 10(1), 9-15.

Allen, M., & Louise Jones, J. (2011). Jekyll and Hyde: the role of the microenvironment on the progression of cancer. The Journal of pathology, 223(2), 163-177.

Anders, C., & Carey, L. A. (2008). Understanding and treating triple-negative breast cancer. Oncology (Williston Park, NY), 22(11), 1233.

Basolo, F., Fiore, L., Ciardiello, F., Calvo, S., Fontanini, G., Conaldi, P. G., & Toniolo, A. (1994). Response of normal and oncogene-transformed human mammary epithelial cells to transforming growth factor beta 1 (TGF-beta 1): lack of growth-inhibitory effect on cells expressing the simian virus 40 large-T antigen. Int J Cancer, 56(5), 736-742.

Borah, A., Raveendran, S., Rochani, A., Maekawa, T., & Kumar, D. (2015). Targeting self-renewal pathways in cancer stem cells: clinical implications for cancer therapy. Oncogenesis, 4(11), e177-e177.

Bozorgi, A., Khazaei, M., & Khazaei, M. R. (2015). New findings on breast cancer stem cells: a review. Journal of breast cancer, 18(4), 303-312.

Concha-Benavente, F., & Ferris, R. L. (2017). Reversing EGFR Mediated Immunoescape by Targeted Monoclonal Antibody Therapy. Front Pharmacol, 8, 332.

Deepak, K., Vempati, R., Nagaraju, G. P., Dasari, V. R., Nagini, S., Rao, D., & Malla, R. R. (2020). Tumor microenvironment: Challenges and opportunities in targeting metastasis of triple negative breast cancer. Pharmacological research, 153, 104683.

Di Mauro, C., Rosa, R., D'Amato, V., Ciciola, P., Servetto, A., Marciano, R., Orsini, R. C., Formisano, L., De Falco, S., Cicatiello, V., Di Bonito, M., Cantile, M., Collina, F., Chambery, A., Veneziani, B. M., De Placido, S., & Bianco, R. (2017). Hedgehog signalling pathway orchestrates angiogenesis in triple-negative breast cancers. Br J Cancer, 116(11), 1425-1435.

Fridman, W. H., Pages, F., Sautes-Fridman, C., & Galon, J. (2012). The immune contexture in human tumours: impact on clinical outcome. Nature Reviews Cancer, 12(4), 298-306.

Garcia-Gomez, A., Rodríguez-Ubreva, J., & Ballestar, E. (2018). Epigenetic interplay between immune, stromal and cancer cells in the tumor microenvironment. Clin Immunol, 196, 64-71.

Goldhirsch, A., Winer, E. P., Coates, A., Gelber, R., Piccart-Gebhart, M., Thürlimann, B., Senn, H.-J., Albain, K. S., André, F., & Bergh, J. (2013). Personalizing the treatment of women with early breast cancer: highlights of the St Gallen International Expert Consensus on the Primary Therapy of Early Breast Cancer 2013. Annals of oncology, 24(9), 2206-2223.

Goldsberry, W. N., Londoño, A., Randall, T. D., Norian, L. A., & Arend, R. C. (2019). A Review of the Role of Wnt in Cancer Immunomodulation. Cancers (Basel), 11(6).

Hartwig, F., Nedel, F., Collares, T., Tarquinio, S., Nör, J., & Demarco, F. (2014). Oncogenic somatic events in tissue-specific stem cells: a role in cancer recurrence? Ageing research reviews, 13, 100-106.

Helfen, A., Roth, J., Ng, T., & Eisenblaetter, M. (2018). In vivo imaging of pro-and antitumoral cellular components of the tumor microenvironment. Journal of Nuclear Medicine, 59(2), 183-188.

Hui, L., & Chen, Y. (2015). Tumor microenvironment: Sanctuary of the devil. Cancer letters, 368(1), 7-13.

Hunter, S., Nault, B., Ugwuagbo, K. C., Maiti, S., & Majumder, M. (2019). Mir526b and Mir655 Promote Tumour Associated Angiogenesis and Lymphangiogenesis in Breast Cancer. Cancers (Basel), 11(7).

Hwang, K.-T., Kim, J., Jung, J., Chang, J. H., Chai, Y. J., Oh, S. W., Oh, S., Kim, Y. A., Park, S. B., & Hwang, K. R. (2019). Impact of breast cancer subtypes on prognosis of women with operable invasive breast cancer: a population-based study using SEER database. Clinical Cancer Research, 25(6), 1970-1979.

Irey, E. A., Lassiter, C. M., Brady, N. J., Chuntova, P., Wang, Y., Knutson, T. P., Henzler, C., Chaffee, T. S., Vogel, R. I., & Nelson, A. C. (2019). JAK/STAT inhibition in macrophages promotes therapeutic resistance by inducing expression of protumorigenic factors. Proceedings of the National Academy of Sciences, 116(25), 12442-12451.

Jamdade, V. S., Sethi, N., Mundhe, N. A., Kumar, P., Lahkar, M., & Sinha, N. (2015). Therapeutic targets of triple-negative breast cancer: a review. British journal of pharmacology, 172(17), 4228-4237.

Johnson, D. E., O'Keefe, R. A., & Grandis, J. R. (2018). Targeting the IL-6/JAK/STAT3 signalling axis in cancer. Nat Rev Clin Oncol, 15(4), 234-248.

Kalluri, R. (2016). The biology and function of exosomes in cancer. J Clin Invest, 126(4), 1208-1215.

Klein, D. (2018). The tumor vascular endothelium as decision maker in cancer therapy. Frontiers in oncology, 8, 367.

Kuo, W.-H., Chang, Y.-Y., Lai, L.-C., Tsai, M.-H., Hsiao, C. K., Chang, K.-J., & Chuang, E. Y. (2012). Molecular characteristics and metastasis predictor genes of triple-negative breast cancer: a clinical study of triple-negative breast carcinomas.

Li, I., & Nabet, B. Y. (2019). Exosomes in the tumor microenvironment as mediators of cancer therapy resistance. Mol Cancer, 18(1), 32.

Liu, S., Cong, Y., Wang, D., Sun, Y., Deng, L., Liu, Y., Martin-Trevino, R., Shang, L., McDermott, S. P., & Landis, M. D. (2014). Breast cancer stem cells transition between epithelial and mesenchymal states reflective of their normal counterparts. Stem cell reports, 2(1), 78-91.

Liu, Y., Burness, M. L., Martin-Trevino, R., Guy, J., Bai, S., Harouaka, R., Brooks, M. D., Shang, L., Fox, A., & Luther, T. K. (2017). RAD51 mediates resistance of cancer stem cells to PARP inhibition in triple-negative breast cancer. Clinical Cancer Research, 23(2), 514-522.

Lu, P., Weaver, V. M., & Werb, Z. (2012). The extracellular matrix: a dynamic niche in cancer progression. Journal of cell biology, 196(4), 395-406.

Martelotto, L. G., Ng, C. K., Piscuoglio, S., Weigelt, B., & Reis-Filho, J. S. (2014). Breast cancer intra-tumor heterogeneity. Breast Cancer Research, 16(3), 1-11.

Martin, L. J., Brambrink, A. M., Lehmann, C., Portera-Cailliau, C., Koehler, R., Rothstein, J., & Traystman, R. J. (1997). Hypoxia—ischemia causes abnormalities in glutamate transporters and death of astroglia and neurons in newborn striatum. Annals of Neurology: Official Journal of the American Neurological Association and the Child Neurology Society, 42(3), 335-348.

Mathot, P., Grandin, M., Devailly, G., Souaze, F., Cahais, V., Moran, S., Campone, M., Herceg, Z., Esteller, M., Juin, P., Mehlen, P., & Dante, R. (2017). DNA methylation signal has a major role in the response of human breast cancer cells to the microenvironment. Oncogenesis, 6(10), e390.

McEarchern, J. A., Kobie, J. J., Mack, V., Wu, R. S., Meade-Tollin, L., Arteaga, C. L., Dumont, N., Besselsen, D., Seftor, E., Hendrix, M. J., Katsanis, E., & Akporiaye, E. T. (2001). Invasion and metastasis of a mammary tumor involves TGF-beta signaling. Int J Cancer, 91(1), 76-82.

Moroishi, T., Hayashi, T., Pan, W. W., Fujita, Y., Holt, M. V., Qin, J., Carson, D. A., & Guan, K. L. (2016). The Hippo Pathway Kinases LATS1/2 Suppress Cancer Immunity. Cell, 167(6), 1525-1539.e1517.

Morris, G. J., Naidu, S., Topham, A. K., Guiles, F., Xu, Y., McCue, P., Schwartz, G. F., Park, P. K., Rosenberg, A. L., & Brill, K. (2007). Differences in breast carcinoma characteristics in newly diagnosed African–American and Caucasian patients: A single-institution compilation compared with the National Cancer Institute's Surveillance, Epidemiology, and end results database. Cancer: Interdisciplinary International Journal of the American Cancer Society, 110(4), 876-884.

Muller, C. (2013). Tumour-surrounding adipocytes are active players in breast cancer progression. Annales d'endocrinologie,

Najafi, M., Farhood, B., & Mortezaee, K. (2019). Extracellular matrix (ECM) stiffness and degradation as cancer drivers. Journal of cellular biochemistry, 120(3), 2782-2790.

Nakai, K., Hung, M. C., & Yamaguchi, H. (2016). A perspective on anti-EGFR therapies targeting triple-negative breast cancer. Am J Cancer Res, 6(8), 1609-1623.

Nallanthighal, S., Heiserman, J. P., & Cheon, D.-J. (2019). The Role of the Extracellular Matrix in Cancer Stemness [Mini Review]. Frontiers in Cell and Developmental Biology, 7(86).

Nico, B., Benagiano, V., Mangieri, D., Maruotti, N., Vacca, A., & Ribatti, D. (2008). Evaluation of microvascular density in tumors, pro and contra. Histology and histopathology.

O'Conor, C. J., Chen, T., González, I., Cao, D., & Peng, Y. (2018). Cancer stem cells in triple-negative breast cancer: a potential target and prognostic marker. Biomarkers in medicine, 12(7), 813-820.

Otranto, M., Sarrazy, V., Bonté, F., Hinz, B., Gabbiani, G., & Desmouliere, A. (2012). The role of the myofibroblast in tumor stroma remodeling. Cell adhesion & migration, 6(3), 203-219.

Rigoglio, N. N., Rabelo, A. C. S., Borghesi, J., Sá Schiavo Matias, G. d., Fratini, P., Prazeres, P. H. D. M., Pimentel, C. M. M. M., Birbrair, A., & Miglino, M. A. (2020). The tumor microenvironment: focus on extracellular matrix. Tumor Microenvironment, 1-38.

Rostami, N., Nikkhoo, A., Ajjoolabady, A., Azizi, G., Hojjat-Farsangi, M., Ghalamfarsa, G., Yousefi, B., Yousefi, M., & Jadidi-Niaragh, F. (2019). S1PR1 as a Novel Promising Therapeutic Target in Cancer Therapy. Mol Diagn Ther, 23(4), 467-487.

Schneider, G. (2020). S1P Signaling in the Tumor Microenvironment. Adv Exp Med Biol, 1223, 129-153.

Sobierajska, K., Ciszewski, W. M., Sacewicz-Hofman, I., & Niewiarowska, J. (2020). Endothelial cells in the tumor microenvironment. Tumor Microenvironment, 71-86.

Solinas, G., Germano, G., Mantovani, A., & Allavena, P. (2009). Tumor-associated macrophages (TAM) as major players of the cancer-related inflammation. Journal of leukocyte biology, 86(5), 1065-1073.

Speiser, J., Foreman, K., Drinka, E., Godellas, C., Perez, C., Salhadar, A., Erşahin, Ç., & Rajan, P. (2012). Notch-1 and Notch-4 biomarker expression in triple-negative breast cancer. Int J Surg Pathol, 20(2), 139-145.

Tan, P. H., Ellis, I., Allison, K., Brogi, E., Fox, S. B., Lakhani, S., Lazar, A. J., Morris, E. A., Sahin, A., Salgado, R., Sapino, A., Sasano, H., Schnitt, S., Sotiriou, C., van Diest, P., White, V. A., Lokuhetty, D., Cree, I. A., & Board, f. t. W. C. o. T. E. (2020). The 2019 World Health Organization classification of tumours of the breast. Histopathology, 77(2), 181-185.

Tomita, H., Tanaka, K., Tanaka, T., & Hara, A. (2016). Aldehyde dehydrogenase 1A1 in stem cells and cancer. Oncotarget, 7(10), 11018.

Tsai, M.-J., Chang, W.-A., Huang, M.-S., & Kuo, P.-L. (2014). Tumor microenvironment: a new treatment target for cancer. International Scholarly Research Notices, 2014.

Vadde, R., Vemula, S., Jinka, R., Merchant, N., Bramhachari, P. V., & Nagaraju, G. P. (2017). Role of hypoxia-inducible factors (HIF) in the maintenance of stemness and malignancy of colorectal cancer. Critical reviews in oncology/hematology, 113, 22-27.

Wang, M., Zhao, J., Zhang, L., Wei, F., Lian, Y., Wu, Y., Gong, Z., Zhang, S., Zhou, J., & Cao, K. (2017). Role of tumor microenvironment in tumorigenesis. Journal of Cancer, 8(5), 761.

Wolff, A. C., Hammond, M. E. H., Hicks, D. G., Dowsett, M., McShane, L. M., Allison, K. H., Allred, D. C., Bartlett, J. M., Bilous, M., & Fitzgibbons, P. (2014). Recommendations for human epidermal growth factor receptor 2 testing in breast cancer: American Society of Clinical Oncology/College of American Pathologists clinical practice guideline update. Archives of Pathology and Laboratory Medicine, 138(2), 241-256.

Wu, Q., Li, B., Li, Z., Li, J., Sun, S., & Sun, S. (2019). Cancer-associated adipocytes: key players in breast cancer progression. Journal of hematology & oncology, 12(1), 1-15.

Yoo, Y. D., & Kwon, Y. T. (2015). Molecular mechanisms controlling asymmetric and symmetric self-renewal of cancer stem cells. Journal of analytical science and technology, 6(1), 1-6.

Zhang, C. X., Ye, S. B., Ni, J. J., Cai, T. T., Liu, Y. N., Huang, D. J., Mai, H. Q., Chen, Q. Y., He, J., Zhang, X. S., Zeng, Y. X., Li, J., & Cui, J. (2019). STING signaling remodels the tumor microenvironment by antagonizing myeloid-derived suppressor cell expansion. Cell Death Differ, 26(11), 2314-2328.

CHAPTER 10

USE OF RADIOTHERAPY IN ONCOLOGICAL EMERGENCIES

Zümrüt BAHAT[1]

[1] Dr.Lecturer, Zümrüt BAHAT. KTU Faculty of Medicine, Department of Radiation Oncology, Trabzon, Turkey. zbahat@hotmail.com ORCID ID: 0000-0002-1636-9393

INTRODUCTION

Although the aim of cancer treatment is to provide cure, about 60% of patients cannot be cured. Palliative treatments can be applied to these patients, who are expected die due to cancer. Thereby, the patient's quality of life is aimed to be improved, symptom control can be provided, and even life expectancy can be extended.

Palliative treatment modalities used in oncological practice include chemotherapy, radiotherapy and surgical interventions (Aydoğan ve Uygun, 2006). In general, radiotherapy (RT) is applied in about 60% of cancer patients. 50-30% of the radiotherapy applications are applied for palliative purposes. The main indications for palliative radiotherapy are pain, bone metastasis, brain metastasis, spinal cord compression, bronchial, esophageal and ureteral obstructions, bleeding gynecological cancers and treatment of superficial wounds that are due to cancer metastasis. In some cases, palliative RT should be applied urgently (Kapoor et all., 2001). The oncological emergencies that should prompt palliative RT application are as follows:

- Vena Cava Superior Syndrome
- Brain metastases
- Spinal cord compression
- Bone metastases

1.VENA CAVA SUPERIOR SYNDROME (VCSS)

The vena cava superior (VCS) has a thin vessel wall and is surrounded by many lymph nodes, sternum, right main bronchus, aorta, pulmonary artery, perihilar and paratracheal lymph nodes, from which the lymphatics of the right lung and partly the lower part of the left thorax are poured. Any pathology that reduces VCS blood circulation can cause VCSS. On the other hand, in about 70-90% of VCSS cases, the obstruction occurs due to mass compression originated from a malignancy. In 90% of cases, lung cancer, esp. those located in the right upper lobe/ right hilar region is the reason of cancer-related VCSS cases. The most common cases are small cell lung carcinoma and squamous cell lung carcinoma subtypes

histopathologically. Other malignant causes are non-Hodgkin lymphomas and metastatic diseases to the mediastinum (e.g., breast cancer, testicular cancer, gastrointestinal cancer, thyroid cancer, malignant melanoma, sarcoma, …etc.). Non-tumor causes can be listed as VCS thrombosis (-can develop after central venous catheter or pacemaker implantation), benign masses (e.g., aortic aneurysm, goiter, …etc.) and granulation or fibrosis (-can be due to infections such as histoplasmosis, tuberculosis, syphilis, …etc.).

On physical examination, dyspnea is the most common sign. This is due to both the primary compression by the mass itself and the pleural effusion caused by the venous block due to the compression of the mass. Venous engorgement in the neck, edema in the face, orbit and arms, and even tracheal edema can be seen. Plethora and cyanosis may be observed on the face due to blood pooling. Cough, chest pain, difficulty in swallowing can be seen due to the compression. The superficial veins in the upper part of the body may become more prominent on inspection, which occurs due to use of these veins to compensate and restore reduced venous blood return to the heart. The severity of the symptoms related to VCSS depends on the underlying pathology and the rate at which the obstruction of the VCS occurred. If the obstruction develops slowly, collateral formation could take place and the symptoms will be less.

If there is a known malignant disease, especially lung cancer, and symptoms specific to VCSS are present in the diagnosis, anamnesis and physical examination findings easily guide the clinicians. Postero-enterior and lateral chest X-rays serve as simple and quick imaging modalities to exclude other causes. In the chest X-ray; enlargement of the upper mediastinum, pleural effusion and hilar mass can be seen. Further examinations can be performed with CT and MRI. MRI is the most sensitive method for diagnosis. The diagnosis can be made with PET/CT as well and this modality will also provide whole body scan for metastasis.

In treatment, airway safety should be ensured first. Depending on the severity of the symptoms, supplemental oxygen can be required. By raising the head of the bed, pooling of blood in the upper part of the body can be reduced. High dose diuretics can be administered to reduce edema. In benign cases, treatment for the etiology is required. In malignant cases, RT should be started immediately. In tumors sensitive to chemoradiotherapy (CRT), such as

small cell lung cancer (SCLC), lymphoma and germ cell tumors, it is recommended to start chemotherapy first. In these tumors, the chemotherapy response is sometimes so rapid and pronounced that in some cases, radiotherapy may not be needed (Straka et all., 2016).

2. BRAIN METASTASES

Brain metastases are observed in 25-35% of the cases during the treatment/follow-up of malignant diseases. However, this rate rises to 80-90% in autopsy series. Brain metastases constitute the majority of adult brain tumors. They are seen 8 times more frequently than the primary brain tumors. The most common cancers that metastasize to the brain are lung, breast, kidney, and malignant melanoma. Metastasis is often seen in the gray and white matter junction. It is most common in the cerebral hemispheres (70-90%). Metastases to the cerebellum is observed in 10-15% and to the brain stem is 5%, but it is rare in the meninges. It is usually multiple, especially in lung cancer metastases. However, when cancers with single metastasis are examined, colon, kidney and breast cancers dominate as the origin of metastases.

Symptoms related to brain metastases vary according to the location of the metastases. The most common symptoms are headache due to increased intracranial pressure (50-70%), nausea-vomiting, and visual disturbances. However, hemiplegia – hemiparesis, mental changes, speech disorder, papilla edema, convulsions, syncope and dizziness can be observed according to the lesion location.

Anamnesis, physical examination and imaging methods guide diagnosis. CT and MRI are recommended as imaging modalities. MRI is more sensitive than CT. On the other hand, brain metastases can be missed with PET-CT due to the high physiological FDG uptake of the brain tissue.

High-dose steroids (i.e., dexamethasone) should be administered in the treatment. Depending on the severity of the patients' symptoms, after starting 16-24 mg, it can be reduced to 2x8 mg for maintenance. If the symptoms are severe and the response to steroid therapy is inadequate, a diuretic therapy can be added. However, in some patients, the symptoms are mild and the steroid dose can be reduced more. Anti-edema treatment can be modified according to the patient's symptoms and response to treatment. If

there is an epileptic attack, lorazepam 0.1 mg/kg iv, 2mg/min; Phenytoin 20 mg/kg iv, 50 mg/min are recommended. The must-be treatment is radiotherapy. Palliation of symptoms are accomplished in 60-70% of the cases.

Survival is prolonged by 3-5 months in average with radiotherapy. If the brain metastasis is solitary, surgery is also an option to be considered. However, radiotherapy must be applied after surgery. In these cases, survival is higher than in cases treated with radiotherapy alone (Tsao et all., 2012).

3. SPINAL CORD COMPRESSION

Spinal cord compression is observed in 5-10% of cancer patients. It is most commonly (in 75%) observed due to the collapse of the vertebral bone. In 25%, it occurs due to the extension of the epidural tumor. It is most frequently observed in breast, lung, multiple myeloma and prostate cancers. Thoracic vertebrae are involved in about 70%, lumbar vertebrae in 20% and cervical vertebra in 10%.

Pain is present in 80-90% of cases and is the earliest sign. Pain typically increases when patients lies on back. Loss of strength occurs in 1-2 weeks after pain. Loss of sensation begins to occur. In the advanced cases, bladder obstruction, constipation, impotence and myelopathy – paraplegia can be seen.

Anamnesis, physical examination, imaging methods (direct X-rays, myelography, CT, MRI, PET/CT and scintigraphy) can be used for diagnosis. Direct radiographs can lead to the diagnosis in 70-80%. Erosion, pedicle loss and vertebral collapse can be observed. However, MRI is the gold standard.

For the treatment of spinal cord compression, dexamethasone should be started at a loading dose (10-16 mg) and continued with a maintenance dose. The time between symptom onset and initiation of treatment is important in response to treatment. With radiotherapy, 70-80% pain palliation, 50% improvement in motor functions, 10-15% improvement in paraplegia can be achieved. However, prognosis correlates with pre-treatment neurologic deficit. In cases where surgical stabilization is required, decompression and laminectomy and vertebral corpus resection may be considered. In addition, surgical treatment can be considered as a priority if there is no role of radiotherapy, i.e. in RT insensitive tumors, upper cervical cord compressions,

and tumors that have been treated previously with radiotherapy. Chemotherapy is one of the options that should be added to the treatment in chemo-sensitive tumors (Rasool et all., 2016).

4. BONE METASTASES

The most common malignant disease in bone is bone metastases. 15-20% of cancer treatments consist of patients with bone metastases. Its morbidity is high due to its complications. The most common tumors that metastasize to the bone are breast, lung, prostate, kidney, and multiple myeloma.

Metastatic lesions can be osteolytic, osteoblastic or mixed. Osteolytic metastases have the highest risk of fracture. The risk of fracture is highest when the weight-bearing bones are affected, and the metastases involve larger areas of the bone. In addition to anamnesis and physical examination, imaging methods are used for diagnosis. Osteolytic or osteosclerotic areas and pathological fractures can be seen with direct radiographs. Bone scintigraphy may also detect non-symptomatic lesions. Scintigraphy is sensitive to osteoblastic lesions and does not show pure osteolytic lesions. CT or MRI are also used in diagnosis. The most sensitive examination detecting bone metastases is MRI. PET-CT scans the whole body and is sensitive also to osteolytic lesions. Bone biopsy can be performed to distinguish solitary meatastatic lesions from primary bone lesions. Treatment modalities can be used alone or in combination. RT is the most commonly used method and main treatment modality in bone metastases. Among patients referred to palliative RT, less than half has a measurable response to prescribed analgesics. RT is given in symptomatic patients, in asymptomatic patients who has metastases at weight-bearing bones and have a risk of fracture (such as femoral neck, vertebra). Pain palliation is achieved in 80-90% and re-ossification in 65-85%. In patients with high survival expectation (prostate and breast cancer, solitary lesions, etc.), surgical treatment can be applied as internal fixation, either prophylactically or when fracture occurs. Medical treatment includes analgesics and bisphosphonates. Bisphosphonates inhibit osteoclastic activity in the bone. Bisphosphonates achieve re-ossification in 10-20% (Yang et all., 2016).

REFERENCES

Aydoğan, F. ve Uygun, K. (2006). Kanser hastalarında palyatif tedaviler. *Klinik Gelişim,* 4-9. http://www.klinikgelisim.org.tr/kg_243/2.pdf

Kapoor, A., Singhal, M. K., Kumar, N., Kalwar, A., Bagri, P. K., Narayan, S.,… Kumar, H. S. (2015). Analysis of patterns of palliative radiotherapy in north west India: a regional cancer center experience. *Indian J Palliat Care*, May-Aug, 21(2), 168-73. doi: 10.4103/0973-1075.156482

Rasool, M. T., Fatima, K., Manzoor, N.A., Mustafa S.A., Maqbool, L. M., Qamar, W. S.,… Shah, M. (2016). Profile of Malignant Spinal Cord Compression: One Year Study at Regional Cancer Center. *Indian J Palliat Care*, Apr-Jun, 22(2), 125–129. doi: 10.4103/0973-1075.179605

Straka, C., Ying, J., Kong, F. M., Willey, C. D., Kaminski, J., Kim, J. W. N. (2016). Review of evolving etiologies, implications and treatment strategies for the superior vena cava syndrome. *Springerplus*, 5, 229. doi: 10.1186/s40064-016-1900-7

Tsao, M.N., Rades, D., Wirth, A., Lo, S.S., Danielson, B.L., Gaspar, L. E.,… Chang, E. L (2012). Radiotherapeutic and surgical management for newly diagnosed brain metastasis(es): An American Society for Radiation Oncology evidence-based guideline. *Pract Radiat Oncol*, Jul, 2(3), 210–225. doi: 10.1016/j.prro.2011.12.004

Yang, Y., Ma, Y., Sheng, J., Huang, Y., Zhao, Y., Fang W.,… Zhang, L. (2016). A multicenter, retrospective epidemiologic survey of the clinical features and management of bone metastatic disease in China. *Chin J Cancer*, 35-40. doi: 10.1186/s40880-016-0102-6

CHAPTER 11

REGENERATIVE DENTISTRY AND ENDODONTICS APPROACHES

Enes Mustafa AŞAR[1] , Büşra MUSLU DINÇ[2]

[1] Research Assistant , Selçuk University Faculty of Dentistry, Department of Pediatric Dentistry, Konya, Turkey, enesmustafasar@gmail.com .ORCID ID : 0000-0003-3432-8584
[2] Research Assistant , Selçuk University Faculty of Dentistry, Department of Pediatric Dentistry, Konya, Turkey, dt.busramuslu@gmail.com .ORCID ID: 0000-0002-0230-5241

INTRODUCTION

Regeneration is the differentiation of progenitor cells to repair impaired tissue functions and restore damaged cells(Nelson et al., 2008). Thus, regenerative medicine aims to restore the functionality of damaged tissues and organs(Harink et al., 2013).

Some of the first tissue replacement treatments performed thousands of years ago also included teeth(Craig & Marcus, 1996). Loss and failure of tissues are common problems not only in medicine but also in dentistry(Baum & Mooney, 2000). Over the years, various advances have been made in oral and dental health with the contributions of regenerative medicine(Baum, 2002). Replacing pathological tissues with healthy tissues(Kaigler & Mooney, 2001), developing vaccines against viruses(Baum & O'CONNELL, 1995), genetic modification of disease-causing agents in periodontitis and caries(Hillman, 2002), stimulating endodontic regeneration are some of these advances.

Teeth and surrounding tissues are responsible for speech, chewing, aesthetics, respiration, and expressions in the mouth. Oral tissues are prone to various diseases that may be caused by physical, chemical, and microbial factors throughout our lives(Galler & D'Souza, 2011). For this reason, pathologies, malignancies, and autoimmune diseases that may occur in the mouth should not be neglected(Singh et al., 2012). Apart from these, one of the most common diseases in milk and permanent teeth of all age groups is dental caries(Beltrán-Aguilar et al., 2005). Although restorative materials are used effectively for the treatment of caries in traditional dentistry, they have many disadvantages against developing and advancing regenerative medicine(Majumdar, 2002). In the light of regenerative developments in recent years, modern dentistry focuses on the use of stem cells, biomaterials, scaffolds, and growth factors(Amrollahi et al., 2016).

1. TISSUE ENGINEERING

Regenerative medicine is advancing with the contributions of tissue engineering. Tissue engineering aims to create similar tissues that can replace tissues that have lost their health or cannot function(Berthiaume et al., 2011). Tissue engineering is defined as "understanding the principles of tissue growth and applying this to produce functional replacement tissue for clinical

use”(Langer & Vacanti, 1993). This definition may change over time with advances in tissue engineering(Murray et al., 2007). Tissue engineering advances using stem cells, growth factors, and scaffolds(Ahmed et al., 2020).

1.1. Stem Cells

Cells that can differentiate into different cells and tissues are known as stem cells(Rao, 2004). In the studies, many advances have been made about human embryonic and adult stem cells(Fan et al., 2011). Every tissue and organ in the human body is derived from stem cells(Smith, 2001). Stem cells are of two different types, embryonic and postnatal(Fortier, 2005). The differentiation ability of embryonic stem cells is much greater than postnatal stem cells(Menasché, 2005). Despite many unanswered questions, postnatal stem cells hold promise for regenerative medicine(Murray et al., 2007). After the use of bone marrow transplantation in immune therapy in 1968, postnatal stem cells began to be used in various treatments(Kenny & Hitzig, 1979). For many years, postnatal stem cells in the bone marrow have been used as a treatment for genetic disorders, lymphoma, leukemia, and some anemia(Barrett & McCarthy, 1990).

Postnatal stem cells are found in various tissues of the body, including dental pulp(Gimble & Guilak, 2003). Neural crest-derived dental stem cells (DSC) are easily available and safe stem cells(Kerkis et al., 2006). These cells can differentiate into mesodermal, ectodermal, and endodermal cells(Nakamura et al., 2009). DSC can be isolated from pulp tissue, periodontal connective tissue, apical papilla, dental follicle, and even gingiva(Grawish, 2018). DSCs can differentiate into many cells such as odontoblasts, osteoblasts, chondroblasts, vascular cells, glial cells(Yang et al., 2018). Stem cells obtained from the person are called autologous stem cells and these cells are the stem cells that show the best compatibility with the tissue to be treated(Le Blanc & Ringdén, 2005). However, there are some disadvantages such as the difficulty of obtaining autologous stem cells with age and the infection of the donor area(Murray et al., 2007). Autologous postnatal stem cells show promise for endodontic regeneration(Téclès et al., 2005). Dental pulp stem cells (DPSC), which can be obtained even from extracted teeth, have a great potential in regenerative treatments in dentistry

because they have high differentiation potential and can be easily cultured(Tsutsui, 2020).

1.2. Growth Factors

Growth factors are proteinaceous messengers that stimulate cell differentiation and proliferation(Wingard & Weeks, 1999). Dentin tissue is rich in growth factors. Dentin tissue by acid conditioning, restoration materials, caries tissue in teeth can lead to the release of growth factors(Murray & Smith, 2002). Growth factors play an important role in the repair of tertiary dentin of pulp tissue(Tziafas et al., 1995). Transforming growth factor (TGF) stimulated by odontoblasts provides stimulation of the dentin matrix when necessary(Niwa et al., 2018).

1.3. Scaffold

Tissue engineering uses three-dimensional scaffolds that can facilitate tissue regeneration and restoration when needed. These scaffolds can be composed of biodegradable or non-biodegradable polymers and ceramics(Abdollahiyan et al., 2021). The scaffolds should degrade over time and replace them with the new tissue(Puri, 2020). To regenerate the pulp tissue, a scaffold should be used that can support the cell organization seeded with pulp stem cells and the vascular structure(Nakashima, 2005). In addition, if the scaffolds are supported with growth factors, the proliferation and differentiation process can be accelerated(Oringer, 2002). Scaffolds should be able to provide an environment suitable for stem cell proliferation, adhere well to dentin walls, slow degradable, and provide structural support(Chrepa et al., 2017).

2. ADVANCES IN REGENERATIVE ENDODONTICS

Components of tissue engineering such as stem cells, growth factors, scaffolding expand the field of regenerative endodontics(Murray et al., 2007).

2.1. Revascularization

Revascularization, which will ensure the continuity of root development, is the most desired treatment, especially in immature teeth(Iwaya et al., 2001). Revascularization is the formation of a blood clot via overinstrumentation in the root canals after disinfecting the root canals

with antibiotics and various irrigation agents(Banchs & Trope, 2004). Growth factors and mesenchymal stem cells enter the root canals with bleeding(Kim et al., 2018). However, when the periapical tissues are not healthy, bleeding may not be achieved, in which case the treatment can be delayed until the periapical tissues heal(Nosrat et al., 2012). This treatment method is often preferred in young patients and immature teeth. Because the regeneration and healing capacity is higher in young patients(Amler, 1977). In addition, the root opening amount of at least 1.1 mm in apical bleeding increases the success of revascularization of the teeth(Kling et al., 1986).

Root canal disinfection is one of the most important factors affecting the success of revascularization(Iwaya et al., 2001). Since dentin walls are weak in immature teeth, chemical debridement with agents such as sodium hypochlorite, chlorhexidine, ethylenediaminetetraacetic acid (EDTA) is recommended instead of mechanical debridement(Kim et al., 2018). After chemical debridement, antibiotic pastes or calcium hydroxide are placed in the root canals for sterilization for several weeks(Cehreli et al., 2011). Some of the agents used for root canal disinfection in revascularization may also play an important role in regeneration. EDTA used in root canal irrigation reveals dentin-derived growth factors that allow cells to survive, proliferate, and differentiate(de Carvalho Deluca et al., 2021). In addition, antibiotics containing tetracycline increase cell growth by revealing collagen fibers and growth factors embedded in the dentin tissue(Terranova et al., 1989).

It is aimed to regenerate living tissues within the root canals of teeth that have lost their vitality as a result of revascularization(Kim et al., 2018). However, in studies, it has been observed that the tissue in the root canals is not the same as the pulp tissue, but bone, cementum, and periodontal tissue-like connective tissue(Conde et al., 2017). However, studies have shown that as a result of revascularization, the teeth regain their vitality, maintain root development and dentin thickening. (Banchs & Trope, 2004; Iwaya et al., 2001). Because this treatment approach is simple and practical, it is often preferred in regenerative endodontics. In addition, this method reduces the risk of immune reaction and contamination(Vemuri et al., 2013).

2.2. Postnatal Stem Cell Therapy

Postnatal stem cells can be found in various regions of the body such as skin, retina, bone marrow, dental epithelial tissue(Jo et al., 2007). Regeneration is aimed by placing stem cells into disinfected root canals(Rai et al., 2013). Postnatal stem cells can be obtained from various tissues such as dental follicles, pulp tissue, periodontal ligament, gums, alveolar bone in the mouth(Egusa et al., 2012). Especially DPSCs are frequently used in dentistry due to their easy access and high differentiation capacity(Nuti et al., 2016).

The biggest advantage of this method is that these cells can be easily obtained and can support the regeneration of the pulp(Murray et al., 2007). Although easy to obtain, it is difficult to keep cells alive, and they can also migrate to undesirable tissues, forming pathological mineralizations(Brazelton & Blau, 2005). Signaling molecules are very important in the differentiation of postnatal stem cells. Therefore, if they cannot interact with signaling molecules, they cannot show differentiation potential(Schmalz & Smith, 2014). Due to its disadvantages, its use is not recommended by everyone and therefore clinical studies are limited(Bakhtiar et al., 2018; Murray et al., 2007).

2.3. Pulp Implantation

It is the placement of cultured pulp tissue into the pulp cavity after the root canal system has been disinfected. Pulp tissue can be produced from healthy stem cell sources or purified in vitro(Murray et al., 2007). In addition, extracted primary teeth into pulp tissue can also be a source(Huang et al., 2019). Pulp tissue can be grown using resorbable polymer nanofibers after cultured(Venugopal & Ramakrishna, 2005). In addition, extracellular protein layers such as collagen I or fibronectin can be used to grow cultured pulp tissue(Fukuda et al., 2006).

2.4. Scaffold Implantation

Scaffolds, which have been involved in tissue engineering studies for many years, have been successfully used in surgical fields of medicine for wound dressing and resorbable sutures(Athanasiou et al., 1996). These biodegradable scaffolds can be in natural or synthetic structures(Taylor et al., 1994). These structures guide tissue regeneration in regenerative medicine

with stem cells and growth factors that can be found on them. It is then resorbed and replaced by regenerated tissues. Despite the benefits, there are also some disadvantages such as difficulty obtaining high porosity and regular pore size. Such negativities accelerated the efforts to obtain nano-sized scaffolds(Tuzlakoglu et al., 2005). A nano-hydroxyapatite/chitosan composite scaffold was used to repair damaged enamel tissue, and its mineralization was shown to be induced(Zaharia et al., 2017). At the same time, it has been observed that hydroxyapatite-based veneer has an antimicrobial effect on caries-causing microorganisms(Abdollahiyan et al., 2021). In another study, dental pulp regeneration with hydrogel scaffolds showed promising results(Fukushima et al., 2019). Scaffolding systems, which is a large research area, may make many contributions to regenerative endodontics therapeutically in the near future. Therefore, more research and studies are needed(Galler et al., 2011).

2.5. Injectable Scaffolding

In non-rigid tissues such as pulp, rigid tissue scaffolds are not required as in hard tissues. Injectable three-dimensional scaffolds such as polymer hydrogels can be used here(Trojani et al., 2005). Although liquid tissue scaffolds such as platelet-rich plasma are used in pulp regeneration, they have disadvantages such as difficulty in obtaining blood from the child(He et al., 2009). For this reason, injectable polymer or hydrogel scaffolds in synthetic structures can also be preferred(Chrepa et al., 2017). Injectable synthetic scaffolds are as biodegradable and biocompatible as natural ones. However, it is not as effective in cellular behavior as natural scaffolds, as it lacks the chemicals responsible for cell communication(Galler et al., 2011). As another option, hyaluronic acid scaffolds are especially suitable for pulp regeneration due to their effects on dental hard tissue formation(Chen et al., 2016; Inuyama et al., 2010). Studies have found that hyaluronic acid plays a primary role in the development of the enamel-dentin matrix and supports angiogenesis by degrading over time(Inuyama et al., 2010; Pardue et al., 2008). In addition, in another study, restylane based on hyaluronic acid was tested as an injectable scaffold. This scaffold has been shown to promote odontoblast-like tissue growth and stimulate mineralization when cultured with apical papilla stem cells(Chrepa et al., 2017).

2.6. Three-Dimensional Cell Printing

Three-dimensional bioprinting accelerates the progress of regenerative medicine, especially in the field of tissue and organ transplantation(Murphy & Atala, 2014). Today, bioprinting is widely used in regenerative and reconstructive treatments in many tissues such as skin, bone, cartilage, heart, and retina(Li et al., 2016; Murphy & Atala, 2014). In the light of these technological advances, three-dimensional bioprinting can be achieved as a functional tissue complex with living cells and supporting components. Great advances have been made in the reconstruction of teeth and supporting tissues using three-dimensional bioprinting in regenerative dentistry(Ma et al., 2019). In a tissue such as pulp, the creation of blood vessels for the continuation of tissue perfusion is one of the most important points in ensuring regeneration. In a study with mice, it was shown that vascular structures designed in three dimensions with this method maintain their metabolic functions(Miller et al., 2012). Despite its advantages, difficulties may be experienced in the placement of the pulp tissue, which is formed in three dimensions, following the root canal anatomy(Murray et al., 2007).

2.7. Gene Therapy

This treatment is an innovative treatment method that includes the creation of functional proteins by changing the genetic structure and the correction of incorrectly coded genes(Siddique et al., 2016). Genetic studies show that gene therapy can help treat various diseases such as cancers, infectious diseases, and autoimmune disorders(Misra, 2013). In gene therapy, genes can be transferred to various target tissues with viral or non-viral vectors(Li et al., 2004). Viral vectors such as herpes simplex virus, retrovirus, adenovirus have been genetically modified. Although it is used in a modified form, there is a risk of infection in gene transfer with viral vectors(Heller et al., 2005). To avoid this risk, non-viral vectors such as plasmids, peptides, electroporation can be used(Nakashima & Reddi, 2003).

In dentistry, researchers aim to produce natural teeth that can replace missing teeth in the laboratory environment(Prabhakar et al., 2011). In endodontics, tissue regeneration can be achieved by transferring genes that provide mineralization to vital pulp cells in necrotic immature teeth(Lovelace

et al., 2011). The health hazards and risks of studies on all these treatments have not been adequately explored. Most of the information written is only theoretically correct and clinical studies are needed to pave the way for this treatment(Mallishery & Shah, 2020).

CONCLUSION

The horizon of regenerative medicine is expanding day by day. Regenerative approaches have provided and continue to offer innovative treatments for many diseases in the past. Therefore, every research and study in this field is very valuable.

REFERENCES

Abdollahiyan, P., Oroojalian, F., Hejazi, M., de la Guardia, M., & Mokhtarzadeh, A. (2021). Nanotechnology, and scaffold implantation for the effective repair of injured organs: An overview on hard tissue engineering. *Journal of Controlled Release*.

Ahmed, G. M., Abouauf, E. A., AbuBakr, N., Dörfer, C. E., & El-Sayed, K. F. (2020). Tissue engineering approaches for enamel, dentin, and pulp regeneration: an update. *Stem Cells International*, *2020*.

Amler, M. (1977). The age factor in human extraction wound healing. *Journal of Oral Surgery (American Dental Association: 1965)*, *35*(3), 193-197.

Amrollahi, P., Shah, B., Seifi, A., & Tayebi, L. (2016). Recent advancements in regenerative dentistry: A review. *Materials Science and Engineering: C*, *69*, 1383-1390.

Athanasiou, K. A., Niederauer, G. G., & Agrawal, C. M. (1996). Sterilization, toxicity, biocompatibility and clinical applications of polylactic acid/polyglycolic acid copolymers. *Biomaterials*, *17*(2), 93-102.

Bakhtiar, H., Mazidi, A., Asl, S. M., Ellini, M., Moshiri, A., Nekoofar, M., & Dummer, P. (2018). The role of stem cell therapy in regeneration of dentine-pulp complex: a systematic review. *Progress in biomaterials*, *7*(4), 249-268.

Banchs, F., & Trope, M. (2004). Revascularization of immature permanent teeth with apical periodontitis: new treatment protocol? *Journal of endodontics*, *30*(4), 196-200.

Barrett, J., & McCarthy, D. (1990). Bone marrow transplantation for genetic disorders. *Blood reviews*, *4*(2), 116-131.

Baum, B. J. (2002). Biomedical research, oral medicine, and the future. *Oral surgery, oral medicine, oral pathology, oral radiology, and endodontics*, *94*(2), 141-142.

Baum, B. J., & Mooney, D. J. (2000). The impact of tissue engineering on dentistry. *The Journal of the American Dental Association*, *131*(3), 309-318.

Baum, B. J., & O'CONNELL, B. C. (1995). The impact of gene therapy on dentistry. *The Journal of the American Dental Association*, *126*(2), 179-189.

Beltrán-Aguilar, E. D., Barker, L. K., Canto, M. T., Dye, B. A., Gooch, B. F., Griffin, S. O., . . . Nowjack-Raymer, R. (2005). Surveillance for dental caries, dental sealants, tooth retention, edentulism, and enamel fluorosis; United States, 1988-1994 and 1999-2002.

Berthiaume, F., Maguire, T. J., & Yarmush, M. L. (2011). Tissue engineering and regenerative medicine: history, progress, and challenges. *Annual review of chemical and biomolecular engineering*, *2*, 403-430.

Brazelton, T. R., & Blau, H. M. (2005). Optimizing techniques for tracking transplanted stem cells in vivo. *Stem cells*, *23*(9), 1251-1265.

Cehreli, Z. C., Isbitiren, B., Sara, S., & Erbas, G. (2011). Regenerative endodontic treatment (revascularization) of immature necrotic molars medicated with calcium hydroxide: a case series. *Journal of endodontics*, *37*(9), 1327-1330.

Chen, K.-L., Yeh, Y.-Y., Lung, J., Yang, Y.-C., & Yuan, K. (2016). Mineralization effect of hyaluronan on dental pulp cells via CD44. *Journal of endodontics*, *42*(5), 711-716.

Chrepa, V., Austah, O., & Diogenes, A. (2017). Evaluation of a commercially available hyaluronic acid hydrogel (Restylane) as injectable scaffold for dental pulp regeneration: an in vitro evaluation. *Journal of endodontics*, *43*(2), 257-262.

Conde, M., Chisini, L., Sarkis-Onofre, R., Schuch, H., Nör, J., & Demarco, F. (2017). A scoping review of root canal revascularization: relevant aspects for clinical success and tissue formation. *International endodontic journal*, *50*(9), 860-874.

Craig, R., & Marcus, L. (1996). Restorative dental materials. Saint Louis, Mosby year book. In: Inc.

de Carvalho Deluca, M. C., Scarparo, R. K., Aspesi, M., Matte, B. F., Brand, L. M., Grecca, F. S., . . . Kopper, P. M. P. (2021). Cytotoxic, Migration, and Angiogenic Effects of Photodynamic Therapy and Photobiomodulation Associated with a Revascularization Protocol. *Journal of endodontics*, *47*(1), 69-77.

Egusa, H., Sonoyama, W., Nishimura, M., Atsuta, I., & Akiyama, K. (2012). Stem cells in dentistry–part I: stem cell sources. *Journal of prosthodontic research*, *56*(3), 151-165.

Fan, C.-G., Zhang, Q.-j., & Zhou, J.-r. (2011). Therapeutic potentials of mesenchymal stem cells derived from human umbilical cord. *Stem Cell Reviews and Reports*, *7*(1), 195-207.

Fortier, L. A. (2005). Stem cells: classifications, controversies, and clinical applications. *Veterinary Surgery*, *34*(5), 415-423.

Fukuda, J., Khademhosseini, A., Yeh, J., Eng, G., Cheng, J., Farokhzad, O. C., & Langer, R. (2006). Micropatterned cell co-cultures using layer-by-layer deposition of extracellular matrix components. *Biomaterials*, *27*(8), 1479-1486.

Fukushima, K., Marques, M., Tedesco, T., Carvalho, G., Gonçalves, F., Caballero-Flores, H., . . . Moreira, M. (2019). Screening of hydrogel-based scaffolds for

dental pulp regeneration—a systematic review. *Archives of oral biology*, *98*, 182-194.

Galler, K. M., D'souza, R., Hartgerink, J., & Schmalz, G. (2011). Scaffolds for dental pulp tissue engineering. *Advances in Dental Research*, *23*(3), 333-339.

Galler, K. M., & D'Souza, R. N. (2011). Tissue engineering approaches for regenerative dentistry. *Regenerative medicine*, *6*(1), 111-124.

Gimble, J. M., & Guilak, F. (2003). Adipose-derived adult stem cells: isolation, characterization, and differentiation potential. *Cytotherapy*, *5*(5), 362-369.

Grawish, M. E. (2018). Gingival-derived mesenchymal stem cells: an endless resource for regenerative dentistry. *World journal of stem cells*, *10*(9), 116.

Harink, B., Le Gac, S., Truckenmüller, R., van Blitterswijk, C., & Habibovic, P. (2013). Regeneration-on-a-chip? The perspectives on use of microfluidics in regenerative medicine. *Lab on a Chip*, *13*(18), 3512-3528.

He, L., Lin, Y., Hu, X., Zhang, Y., & Wu, H. (2009). A comparative study of platelet-rich fibrin (PRF) and platelet-rich plasma (PRP) on the effect of proliferation and differentiation of rat osteoblasts in vitro. *Oral Surgery, Oral Medicine, Oral Pathology, Oral Radiology, and Endodontology*, *108*(5), 707-713.

Heller, L. C., Ugen, K., & Heller, R. (2005). Electroporation for targeted gene transfer. *Expert opinion on drug delivery*, *2*(2), 255-268.

Hillman, J. D. (2002). Genetically modified Streptococcus mutans for the prevention of dental caries. *Antonie Van Leeuwenhoek*, *82*(1), 361-366.

Huang, Y., Tang, X., Cehreli, Z. C., Dai, X., Xu, J., & Zhu, H. (2019). Autologous transplantation of deciduous tooth pulp into necrotic young permanent teeth for pulp regeneration in a dog model. *Journal of International Medical Research*, *47*(10), 5094-5105.

Inuyama, Y., Kitamura, C., Nishihara, T., Morotomi, T., Nagayoshi, M., Tabata, Y., . . . Terashita, M. (2010). Effects of hyaluronic acid sponge as a scaffold on odontoblastic cell line and amputated dental pulp. *Journal of Biomedical Materials Research Part B: Applied Biomaterials: An Official Journal of The Society for Biomaterials, The Japanese Society for Biomaterials, and The Australian Society for Biomaterials and the Korean Society for Biomaterials*, *92*(1), 120-128.

Iwaya, S. i., Ikawa, M., & Kubota, M. (2001). Revascularization of an immature permanent tooth with apical periodontitis and sinus tract. *Dental Traumatology*, *17*(4), 185-187.

Jo, Y.-Y., Lee, H.-J., Kook, S.-Y., Choung, H.-W., Park, J.-Y., Chung, J.-H., . . . Choung, P.-H. (2007). Isolation and characterization of postnatal stem cells from human dental tissues. *Tissue engineering*, *13*(4), 767-773.

Kaigler, D., & Mooney, D. (2001). Tissue engineering's impact on dentistry. *Journal of dental education*, *65*(5), 456-462.

Kenny, A., & Hitzig, W. (1979). Bone marrow transplantation for severe combined immunodeficiency disease. *European journal of pediatrics*, *131*(3), 155-177.

Kerkis, I., Kerkis, A., Dozortsev, D., Stukart-Parsons, G. C., Massironi, S. M. G., Pereira, L. V., . . . Cerruti, H. F. (2006). Isolation and characterization of a population of immature dental pulp stem cells expressing OCT-4 and other embryonic stem cell markers. *Cells Tissues Organs*, *184*(3-4), 105-116.

Kim, S., Malek, M., Sigurdsson, A., Lin, L., & Kahler, B. (2018). Regenerative endodontics: a comprehensive review. *International endodontic journal*, *51*(12), 1367-1388.

Kling, M., Cvek, M., & Mejare, I. (1986). Rate and predictability of pulp revascularization in therapeutically reimplanted permanent incisors. *Dental Traumatology*, *2*(3), 83-89.

Langer, R., & Vacanti, J. P. (1993). Tissue engineering. *Science*, *260*(5110), 920-926.

Le Blanc, K., & Ringdén, O. (2005). Immunobiology of human mesenchymal stem cells and future use in hematopoietic stem cell transplantation. *Biology of Blood and Marrow Transplantation*, *11*(5), 321-334.

Li, J., Chen, M., Fan, X., & Zhou, H. (2016). Recent advances in bioprinting techniques: approaches, applications and future prospects. *Journal of translational medicine*, *14*(1), 1-15.

Li, J., Zheng, C., Zhang, X., Liu, X., Zhang, C., Goldsmith, C. M., . . . Wang, S. (2004). Developing a convenient large animal model for gene transfer to salivary glands in vivo. *The Journal of Gene Medicine: A cross‐disciplinary journal for research on the science of gene transfer and its clinical applications*, *6*(1), 55-63.

Lovelace, T. W., Henry, M. A., Hargreaves, K. M., & Diogenes, A. (2011). Evaluation of the delivery of mesenchymal stem cells into the root canal space of necrotic immature teeth after clinical regenerative endodontic procedure. *Journal of endodontics*, *37*(2), 133-138.

Ma, Y., Xie, L., Yang, B., & Tian, W. (2019). Three-dimensional printing biotechnology for the regeneration of the tooth and tooth-supporting tissues. *Biotechnology and bioengineering*, *116*(2), 452-468.

Majumdar, S. K. (2002). History of dentistry: an overview. *Bull Indian Inst Hist Med Hyderabad*, *32*(1), 31-42.

Mallishery, S., & Shah, T. (2020). Regenerative Endodontics–Looking Inward. *Journal of Advances in Medicine and Medical Research*, 83-98.

Menasché, P. (2005). The potential of embryonic stem cells to treat heart disease. *Current opinion in molecular therapeutics*, *7*(4), 293-299.

Miller, J. S., Stevens, K. R., Yang, M. T., Baker, B. M., Nguyen, D.-H. T., Cohen, D. M., . . . Yu, X. (2012). Rapid casting of patterned vascular networks for perfusable engineered three-dimensional tissues. *Nature materials*, *11*(9), 768-774.

Misra, S. (2013). Human gene therapy: a brief overview of the genetic revolution. *J Assoc Physicians India*, *61*(2), 127-133.

Murphy, S. V., & Atala, A. (2014). 3D bioprinting of tissues and organs. *Nature biotechnology*, *32*(8), 773-785.

Murray, P. E., Garcia-Godoy, F., & Hargreaves, K. M. (2007). Regenerative endodontics: a review of current status and a call for action. *Journal of endodontics*, *33*(4), 377-390.

Murray, P. E., & Smith, A. J. (2002). Saving pulps—a biological basis. An overview. *Primary Dental Care*(1), 21-26.

Nakamura, S., Yamada, Y., Katagiri, W., Sugito, T., Ito, K., & Ueda, M. (2009). Stem cell proliferation pathways comparison between human exfoliated deciduous teeth and dental pulp stem cells by gene expression profile from promising dental pulp. *Journal of endodontics*, *35*(11), 1536-1542.

Nakashima, M. (2005). Tissue engineering in endodontics. *Australian Endodontic Journal*, *31*(3), 111-113.

Nakashima, M., & Reddi, A. H. (2003). The application of bone morphogenetic proteins to dental tissue engineering. *Nature biotechnology*, *21*(9), 1025-1032.

Nelson, T. J., Behfar, A., & Terzic, A. (2008). Strategies for therapeutic repair: the "R3" regenerative medicine paradigm. *Clinical and translational science*, *1*(2), 168-171.

Niwa, T., Yamakoshi, Y., Yamazaki, H., Karakida, T., Chiba, R., Hu, J. C.-C., . . . Margolis, H. C. (2018). The dynamics of TGF-β in dental pulp, odontoblasts and dentin. *Scientific reports*, *8*(1), 1-14.

Nosrat, A., Homayounfar, N., & Oloomi, K. (2012). Drawbacks and unfavorable outcomes of regenerative endodontic treatments of necrotic immature teeth: a literature review and report of a case. *Journal of endodontics*, *38*(10), 1428-1434.

Nuti, N., Corallo, C., Chan, B., Ferrari, M., & Gerami-Naini, B. (2016). Multipotent differentiation of human dental pulp stem cells: a literature review. *Stem Cell Reviews and Reports*, *12*(5), 511-523.

Oringer, R. J. (2002). Biological mediators for periodontal and bone regeneration. *Compendium of continuing education in dentistry (Jamesburg, NJ: 1995)*, *23*(6), 501-504, 506.

Pardue, E. L., Ibrahim, S., & Ramamurthi, A. (2008). Role of hyaluronan in angiogenesis and its utility to angiogenic tissue engineering. *Organogenesis*, *4*(4), 203-214.

Prabhakar, A., Paul, J. M., & Basappa, N. (2011). Gene therapy and its implications in dentistry. *International journal of clinical pediatric dentistry*, *4*(2), 85.

Puri, P. (2020). *Pediatric Surgery: General Principles and Newborn Surgery*. Springer.

Rai, S., Kaur, M., & Kaur, S. (2013). Applications of stem cells in interdisciplinary dentistry and beyond: an overview. *Annals of medical and health sciences research*, *3*(2), 245.

Rao, M. S. (2004). Stem sense: a proposal for the classification of stem cells. *Stem cells and development*, *13*(5), 452-455.

Schmalz, G., & Smith, A. J. (2014). Pulp development, repair, and regeneration: challenges of the transition from traditional dentistry to biologically based therapies. *Journal of endodontics*, *40*(4), S2-S5.

Siddique, N., Raza, H., Ahmed, S., Khurshid, Z., & Zafar, M. S. (2016). Gene therapy: A paradigm shift in dentistry. *Genes*, *7*(11), 98.

Singh, K., Mishra, N., Kumar, L., Agarwal, K. K., & Agarwal, B. (2012). Role of stem cells in tooth bioengineering. *Journal of oral biology and craniofacial research*, *2*(1), 41-45.

Smith, A. G. (2001). Embryo-derived stem cells: of mice and men. *Annual review of cell and developmental biology*, *17*(1), 435-462.

Taylor, M., Daniels, A., Andriano, K., & Heller, J. (1994). Six bioabsorbable polymers: in vitro acute toxicity of accumulated degradation products. *Journal of applied biomaterials*, *5*(2), 151-157.

Téclès, O., Laurent, P., Zygouritsas, S., Burger, A.-S., Camps, J., Dejou, J., & About, I. (2005). Activation of human dental pulp progenitor/stem cells in response to odontoblast injury. *Archives of oral biology*, *50*(2), 103-108.

Terranova, V. P., Odziemiec, C., Tweden, K. S., & Spadone, D. P. (1989). Repopulation of dentin surfaces by periodontal ligament cells and endothelial cells: effect of basic fibroblast growth factor. *Journal of periodontology*, *60*(6), 293-301.

Trojani, C., Weiss, P., Michiels, J.-F., Vinatier, C., Guicheux, J., Daculsi, G., . . . Rochet, N. (2005). Three-dimensional culture and differentiation of human

osteogenic cells in an injectable hydroxypropylmethylcellulose hydrogel. *Biomaterials*, *26*(27), 5509-5517.

Tsutsui, T. W. (2020). Dental pulp stem cells: advances to applications. *Stem cells and cloning: advances and applications*, *13*, 33.

Tuzlakoglu, K., Bolgen, N., Salgado, A., Gomes, M. E., Piskin, E., & Reis, R. (2005). Nano-and micro-fiber combined scaffolds: a new architecture for bone tissue engineering. *journal of materials science: materials in medicine*, *16*(12), 1099-1104.

Tziafas, D., Alvanou, A., Panagiotakopoulos, N., Smith, A., Lesot, H., Komnenou, A., & Ruch, J. (1995). Induction of odontoblast-like cell differentiation in dog dental pulps after in vivo implantation of dentine matrix components. *Archives of oral biology*, *40*(10), 883-893.

Vemuri, S., Kotha, R. S., Raghunath, R. G., & Kandregula, C. R. (2013). Root canal revascularization via blood clotting in regenerative endodontics: Essentials and expectations. *Journal of Dr. NTR University of Health Sciences*, *2*(4), 235.

Venugopal, J., & Ramakrishna, S. (2005). Applications of polymer nanofibers in biomedicine and biotechnology. *Applied biochemistry and biotechnology*, *125*(3), 147-157.

Wingard, J. R., & Weeks, F. M. (1999). Stem Cell Collection for Hematopoietic Transplantation: Stem Cell Sources, Mobilization Strategies, and Factors that Influence Yield. In *Clinical Applications of Cytokines and Growth Factors* (pp. 341-356). Springer.

Yang, X., Li, L., Xiao, L., & Zhang, D. (2018). Recycle the dental fairy's package: overview of dental pulp stem cells. *Stem cell research & therapy*, *9*(1), 1-8.

Zaharia, A., Muşat, V., Anghel, E. M., Atkinson, I., Mocioiu, O.-C., Buşilă, M., & Pleşcan, V. G. (2017). Biomimetic chitosan-hydroxyapatite hybrid biocoatings for enamel remineralization. *Ceramics International*, *43*(14), 11390-11402.

CHAPTER 12

THE ROLE OF SILVER DIAMINE FLUORIDE IN PEDIATRIC DENTISTRY

Büşra MUSLU DINÇ[1] , Enes Mustafa AŞAR[2]

[1] Research Assistant ,Selçuk University Faculty of Dentistry, Department of Pediatric Dentistry, Konya, Turkey, dt.busramuslu@gmail.com .ORCID ID: 0000-0002-0230-5241
[2]Research Assistant , Selçuk University Faculty of Dentistry, Department of Pediatric Dentistry, Konya, Turkey, enesmustafasar@gmail.com .ORCID ID : 0000-0003-3432-8584

INTRODUCTION

Some barriers to traditional restorative treatment, such as age, limited cooperation, access to care, and financial constraints, have led to the search for alternative treatments for caries management. Preventing the formation of caries and the treatment of existing caries in line with the philosophy of minimal invasive dentistry are becoming increasingly important.

Silver diamine fluoride (SDF); It is a colorless solution that contains silver and fluoride ions, has an alkaline structure and can be applied topically to the teeth. Silver compounds have been used in medicine and dentistry for many years due to their varying levels of antimicrobial effect (Knight et al., 2005). Fluoride, on the other hand, is routinely used in various proportions and forms as a gold standard for the prevention and stopping of caries (Chu et al., 2010). It has been said that silver and fluoride can stop the caries process and prevent the development of caries by creating a synergistic effect (Rosenblatt et al., 2009).

SDF has various application areas in dentistry. Treatment of cases of dentin sensitivity; stopping coronal caries in children and root caries in adults; prevention of secondary caries and pit and fissure caries are among the areas of use. It has also been suggested to be used for strengthening endodontically treated teeth and for irrigation of infected root canals (Mei et al., 2016; Yokoyama et al., 2001).

Clinical studies and laboratory studies show that the effect of SDF is higher than fluorine varnishes, which are considered an effective fluorine preparation. In a review made; it has been reported that SDF can be an effective, efficient and reliable caries control agent, and it is also stated that it is more effective in preventing caries than fluorine varnish application (Rosenblatt et al., 2009).

USAGE AREAS OF SILVER COMPOUNDS IN DENTISTRY

Silver compounds entered dental practice in the 1840s, using them in the form of silver nitrate preparations to prevent caries formation in primary teeth (Stebbins, 1891). Silver nitrate has been used as an anti-caries agent in permanent molars as well as for the treatment of dentin sensitivity and cavity disinfection (Everett et al., 1966; James & Parfitt, 1954). In the 1960s, it was

suggested that the co-administration of silver nitrate with fluorine compounds to prevent dental caries stopped the lateral spread of dental caries (Nishino, 1969). The US Food and Drug Administration (FDA) approved the use of the first SDF product in 2014.

Combination of silver compounds and fluoride in dentistry; It is applied in two different chemical forms as silver fluoride and silver diamine fluoride. A 40% silver fluoride preparation (60,000 ppm) is used in Australia to stop dental caries (Gotjamanos, 1996). SDF contains ammonia and silver fluoride. Ammonia combined with silver ions forms a complex ion and this silver diamine compound shows a more stable structure than silver fluoride (May Lei Mei et al., 2013). SDF is also called diamine silver fluoride. It has been suggested that compared to silver fluoride, SDF is more stable and can remain at constant concentrations over a period of time. SDF is commonly used in the form of a 38% solution for caries control and dentin sensitivity treatment. Some commercial SDF products are shown in Table 1.

Table 1. Some commercial SDF products.

Name of the Product	SDF Concen-tration	Fluoride Concen-tration	Company Name	Country
Advantage Arrest™	%38	44,800 ppm	Elevate Oral Care	ABD
FAgamin	%38	44,800 ppm	Tedequim S, R, L	Argentina
Cariestop	%12	14,000 ppm	Biodinâmica Quimica Farmaceutica Ltda.	Brazil
Cariestop	%30	35,400 ppm	Biodinâmica Quimica Farmaceutica Ltda.	Brazil
Saforide	%38	44,800 ppm	J,Morita; Toyo Seiyaku Kasei Ltd.	Japan
Rivastar	%35-40	44,800 ppm	SDI Dental Ltd.	Australia
Fluoroplat	%38	44,800 ppm	Laboratorios Naf	Argentina

SDF application as a preventive treatment for dental caries has a number of advantages:

1. Silver acts on bacteria in the cariogenic biofilm by showing antimicrobial activity (Chu et al., 2012; May L Mei, Chun H Chu, Edward CM Lo, et al., 2013; May L Mei, Chun H Chu, Kan H Low, et al., 2013). Silver ions are metal cations with bactericidal properties (Wu et al., 2007). Silver ion; It has been shown in some studies that it affects hydrogen bonds by interacting with sulfhydryl groups of DNA and different proteins, and prevents cellular respiration, causing DNA helix to separate, disrupting cell wall synthesis and cell division. Thanks to these interactions, bacterial death is ensured and biofilm formation is prevented (OPPERMANN & JOHANSEN, 1980).
2. Fluoride is effective in remineralization of caries lesion. It is known that fluoride reacts with hydroxyapatite crystals in the tooth structure to form calcium fluoride and this structure works as a fluoride reservoir (Ten Cate et al., 1998). In a study conducted; It has been reported that the microhardness of a caries stopped by applying SDF is close to the microhardness of the intact dentin surface (C. Chu & E. C. Lo, 2008). In another study, a highly remineralized area was observed on the recessed caries surface in a tooth treated with SDF (Mei et al., 2014).
3. It has been reported that SDF inhibits some collagenases in dentin and prevents the destruction of dentin collagens (Zhao et al., 2018).

When bacteria, whose life ends by interacting with silver ions, encounter live bacteria, the silver ion is activated again. Thus, dead bacteria can kill the other live bacteria with the 'zombie effect'. This reservoir effect helps explain the long-term antimicrobial effect of the silver ion (Horst et al., 2016).

SDF MECHANISM OF ACTION

There is not enough information in the literature about the effects of SDF on the dentin-pulp complex (Korwar et al., 2015; Rossi et al., 2017). In a

study, SDF was applied to rat molars after cavity preparation and SDF was applied to human deciduous molar with enamel-dentin caries and these teeth were evaluated histologically (Rossi et al., 2017). It has been reported that the tubule structure has a normal appearance, the SDF has a limited penetration depth, there is no silver precipitate in the pulpal tissue adjacent to the caries, and tertiary dentin formation is observed on the tooth surfaces treated with SDF. Likewise, another published study reported that while tertiary dentin deposition was observed in SDF-treated teeth, no signs of inflammation were observed (Korwar et al., 2015).

The biggest disadvantage of SDF is that the caries lesion is stained black after application. SDF prevents the progression of caries by forming a black, hard structure, caries-resistant and impermeable layer on the tooth surface. The darker this coloration, which is seen as a disadvantage, is thought to have stopped the activity of the caries lesion. Some patients or their parents may not be aesthetically satisfied with this coloration result. The discoloration is caused by residual silver ions, and to prevent this, the use of potassium iodide, which reacts with residual silver ions, has been suggested (Hamama et al., 2015; Knight et al., 2005). However, there are also studies reporting that the black coloration of the stopped caries lesions cannot be prevented by this method (Li et al., 2015). The use of ammonium hexafluoro-silicate has been suggested as an alternative to SDF; however, it was observed that the acid resistance of the teeth after the application was lower than after the SDF treatment (Kawasaki et al., 2005). In another study, nano silver fluoride was used and it was reported that no significant coloration was observed after the treatment (dos Santos Jr et al., 2014; Targino et al., 2014). However, more clinical studies and laboratory studies are needed before nano silver fluoride can enter into clinical application routinely.

The guidelines of the American Pediatric Dental Association reported that the benefits of SDF are greater in the light of the available evidence, besides its negative effects such as black discoloration, and they recommend the use of GDF in the caries management of children and adolescents, including individuals who need special care (Crystal, Marghalani, et al., 2017).

As another disadvantage of SDF, it has been reported that it should be stored in a dark bottle because it is sensitive to light. It has also been said that the high fluoride concentration (44,800 ppm) in SDF is another disadvantage that applying too much in young children can lead to fluorosis. In a study, it was stated that the amount of SDF applied per session was 27.5 µg/mm2 on average. However, it is recommended to take precautions and avoid frequent applications in very young children (C. Chu & E. Lo, 2008).

USE OF SDF IN DENTAL TREATMENTS AND CARIES CONTROL

Although SDF has been approved by the FDI for use in the treatment of tooth sensitivity, it is generally used in caries prevention and non-restorative treatment. SDF solution is applied directly to an intact tooth surface to protect the tooth from caries or over the caries lesion to stop existing caries (Tan et al., 2010; Yee et al., 2009). In addition, SDF does not cause discoloration on solid enamel.

Case selection and procedural protocols, indications and contraindications in SDF application have been published by the American Pediatric Dentists Association as a guide (Crystal, Marghalani, et al., 2017; Horst et al., 2016).

Caries management indications with SDF application:

Patients with high caries risk and decayed teeth that will require multiple sessions.

- Patients with behavioral problems who are indicated to be treated under general anesthesia.
- Patients with limited or no access to dental care.
- Patients where the caries lesion is in a position to be reached with the help of a micro brush for SDF to be applied.
- Patients with treatable carious lesions extending to the dentin for both anterior and posterior teeth.

Caries management contraindications with SDF application:

- Individuals with a silver allergy.
- Deep caries lesions that are clinically and radiographically close to the dental pulp.

- Presence of spontaneous or severe pain due to caries in the tooth to be treated.
- Situations where the patient or parent does not accept the black discoloration of the tooth after the application from an aesthetic point of view.

The gingival damage that may develop after SDF treatment can be seen at a very low rate (<6%) and resolves spontaneously within 2 days (Mei et al., 2016). It is recommended to protect the gingival surface with vaseline or rubber dam before SDF application. Although caries removal seems to be a logical option before SDF application, the results of a clinical study; It has been reported that in the treatment performed using 38% SDF, there is no difference in terms of cessation of caries in the teeth where the caries is removed or not (Chu et al., 2002). Application of SDF without caries removal simplifies the treatment and has advantages such as easy adaptation in young children or the elderly; however, it is predicted that it will take more time for the caries to stop in this way (Wong et al., 2011).

There are different opinions in the literature about how often SDF will be applied. In clinical studies, it is seen that 38% SDF is applied once or twice a year (Duangthip et al., 2016; Yee et al., 2009; Zhi et al., 2012). Some researchers applied 38% SDF solution once a week for 3 weeks in order to accelerate the process of stopping the caries in the treatment of rampant caries and reported that this method was effective (Chu et al., 2014). It has been reported that applying SDF once a year is more effective in stopping dental caries than applying 5.0% sodium fluoride varnish 4 times a year (Lo et al., 2001). It has been reported that the frequency of SDF application increases the rate of caries arrest. Application twice a year was found to be more effective than once a year (Ballikaya et al., 2018; Fung et al., 2016; Llodra et al., 2005). Recommended application frequency; 3 months after the first application of 38% SDF and every 6 months for the following 2 years (Horst et al., 2016).

SDF Application

- Soft tissue attachments and debris may need to be removed from the tooth surface for better penetration of the SDF.
- The contact of SDF with soft tissues should be prevented by providing isolation with cotton rolls, vaseline application or rubber dam.
- No more than one drop of SDF solution should be administered to a patient per appointment. (1 drop of SDF solution is sufficient for approximately 5 teeth.)
- After the related tooth is dried with compressed air, the SDF solution should be applied directly to the caries lesion for 1 minute, if possible, with the help of an applicator.
- At the end of the application, the caries lesion should be wiped with a damp gauze or cotton pellet to remove excess unreacted SDF.
- Following the SDF application, it is recommended to apply a thin layer of 5.0% sodium fluoride varnish to all teeth (Hu et al., 2018).

SDF Application Follow-up

- If the application of SDF is not only used to stop superficial dentin caries, the activity of the lesions should be evaluated by giving a control appointment 2-4 weeks after the start of the treatment.
- In cases where the activity of carious lesions still continues at follow-up appointments, SDF should be applied again.
- Depending on the child's cooperation, the carious lesion can be treated with conventional restorations at future appointments.
- It may need to be repeated every 6 months for the effect of SDF to continue (Hu et al., 2018).

In carious lesions stopped with SDF, conventional restorative treatments can be performed at later appointments. Some studies reported that SDF application did not affect the bonding to dentin and gave aesthetically

acceptable results (Quock et al., 2012; Wu et al., 2016). At this point, Modified Atraumatic Restorative Treatment (SMART) with silver has started to gain popularity again recently (Gotjamanos, 1996). This method is a combination of ART treatment and SDF application (Frencken et al., 1996). However, there are some reservations as long-term data on the effectiveness of this technique are not available. In addition, it was stated in a study that the bond of glass ionomer cement used for restoration to dentin decreased after SDF application (Knight & McIntyre, 2006).

It has been stated that glass ionomer restorations made in the SMART technique can become discolored and lose aesthetics after contact with SDF. However, in addition to this disadvantage, SDF's antibacterial effect destroys most of the bacteria in the caries lesion and thanks to ART restorations that are chemically bonded to the tooth, this drawback is may seem insignificant due to its advantages such as stopping the caries by cutting the relationship between the bacteria and the oral environment, realizing remineralization and thus protecting the tooth tissue and pulp vitality (Alvear Fa et al., 2016).

DENTIN SENSITIVITY TREATMENT

Tooth sensitivity can occur on an exposed dentin surface (Chu et al., 2011). It is characterized by varying degrees of pain; It can start with thermal, chemical, volatile or osmotic stimuli (Castillo et al., 2011). SDF solution can be used in the treatment of tooth sensitivity and its clinical application is the same as in carious lesions (Castillo et al., 2011; Craig et al., 2012). In a study, it was reported that dentin permeability decreased at a higher level when potassium iodide was applied after topical fluoride application after SDF application (Knight et al., 2005).

ROOT CANAL DISINFECTION IN ENDODONTIC TREATMENT

In endodontic treatment, it is essential to destroy the microorganisms in the root canals for a successful treatment. Despite all the existing antibacterial agents and techniques used in root canal disinfection, the resistance of Enterococcus faecalis is still mentioned (Law & Messer, 2004). It has been said that a 3.8% solution of SDF (3.8% in Saforide, Toyo Seiyaku Kasei Co. Ltd.) can be used for root canal treatment (Ballikaya & Çehreli,

2020). Saforide is a 1/10 diluted version of 38% SDF solution and it is recommended to be applied 3 times at 24 hour intervals according to the manufacturer's recommendation. After 60 minutes of contact with 3.8% SDF, 100% reduction in E. faecalis was observed (Law & Messer, 2004). It has been said that SDF can also be used as a root canal irrigant or dressing material (Hiraishi et al., 2010; Mathew et al., 2012). SDF has also been reported to cause discoloration in root canals. More clinical studies are needed to support laboratory findings.

RELIABILITY OF SDF

SDF finds use in many countries to stop dental caries (C. Chu & E. Lo, 2008). It is used as a therapeutic agent in dental treatments, approved by the Ministry of Health in Japan.

Similar to the use of silver-containing amalgam in dentistry, SDF has proven success and no significant complications have been reported in the literature. Gum irritation was reported in two studies examining the response of oral tissues to 38% SDF; however, it was stated that this was temporary and no serious reaction was observed (Nishino, 1969; Okuyama, 1974). In a study conducted; It was determined that gingival irritation resolved spontaneously within 2 days (Llodra et al., 2005). In a study examining the presence of gingival erythema after SDF application, it was reported that no patient had severe erythema (Castillo et al., 2011). In another study, SDF was applied to preschool children; however, no serious tissue reaction was found (Chu et al., 2002). 38% SDF (44,800 ppm) containing high concentrations of fluoride may cause concern for fluorosis in young children. The severity of fluorosis depends on the fluoride concentration in the plasma (DenBesten & Li, 2011). Although there is no study conducted with children on this subject, plasma silver and fluoride concentrations were measured after topical SDF application in adults and the results showed that the exposed fluoride dose was below the concentrations associated with toxicity (Vasquez et al., 2012). One drop (25 µL) of SDF can treat approximately 5 teeth and contains 9.5 mg of silver diamine fluoride. Assuming the lightest child to be treated weighs 10 kg, it appears that the maximum dose of SDF would be 1 drop per 10 kg (0.95 mg/kg) (Horst et al., 2016).

PARENT AND PATIENT SATISFACTION

Among the main advantages of topical SDF application are; It requires minimal patient cooperation, does not require local anesthesia, and is more cost-effective than traditional dental treatment. Simple treatment protocol; It provides the opportunity to treat dental caries in patients who need special care with low cooperation, young children with high dental anxiety and elderly patients who have difficulty in adapting (C. Chu & E. Lo, 2008). It is also known that the level of compliance and satisfaction is generally good when a clear and satisfying explanation is given to the patient about the treatment results and advantages.

A dark black coloration is observed in carious lesions after SDF treatment. Especially in anterior teeth, this black discoloration may be negatively perceived by the patient and their parents for aesthetic reasons. Therefore, before the procedure, patients and their parents should be informed in detail about the results of the treatment. In a survey study, 30% of the families considered the discoloration in the anterior teeth and 68% in the posterior teeth as acceptable. However, if the patient's dental treatment should be performed under general anesthesia, it has been reported that 60% of the families prefer the black discoloration of the anterior teeth to the treatment to be performed under general anesthesia (Crystal, Janal, et al., 2017). The perception of the family about coloration has also been seen to be related to the cultural structure. 61-71% of families from Hong Kong reported the appearance of their children after SDF treatment as acceptable. Before the treatment, a written consent form containing all the details should be obtained (Duangthip et al., 2018).

SDF can stain skin, cornea and clothing. Protective glasses must be used during the application. While it does not cause serious damage or pain, SDF that stains the skin is not easily removed and may take about a week to completely wear off. The stain formed as a result of contact with clothes is permanent (C. Chu & E. C. Lo, 2008).

SDF solution has an unpleasant metallic taste. It can irritate the mucosa or gums. The affected gingival area or mucosa becomes white; however, this situation heals spontaneously within 1-2 days (Chu et al., 2002).

CONCLUSION

Clinical reports and studies published to date show that SDF has a wide application in dentistry. Superficial SDF application is a simple, practical and reliable treatment, and it is effective in preventing new caries formation and stopping existing caries.

REFERENCES

Alvear Fa, B., Jew, J., Wong, A., & Young, D. (2016). Silver Modified Atraumatic Restorative Technique (SMART): an alternative caries prevention tool. *Stoma Edu J, 3*(2), 18-24.

Ballikaya, E., & Çehreli, Z. C. (2020). Gümüş Diamin Florürün Çürük Yönetimindeki Yeri. *Turkiye Klinikleri. Dishekimligi Bilimleri Dergisi, 26*(2).

Ballikaya, E., Dogan, B. G., Onay, O., & Tekcicek, M. U. (2018). Oral health status of children with mouth breathing due to adenotonsillar hypertrophy. *International journal of pediatric otorhinolaryngology, 113*, 11-15.

Castillo, J., Rivera, S., Aparicio, T., Lazo, R., Aw, T.-C., Mancl, L., & Milgrom, P. (2011). The short-term effects of diammine silver fluoride on tooth sensitivity: a randomized controlled trial. *Journal of dental research, 90*(2), 203-208.

Chu, C., Lam, A., & Lo, E. (2011). Dentin hypersensitivity and its management. *General dentistry, 59*(2), 115-122; quiz 123.

Chu, C., & Lo, E. (2008). Promoting caries arrest in children with silver diamine fluoride: a review. *Oral health & preventive dentistry, 6*(4).

Chu, C., Lo, E., & Lin, H. (2002). Effectiveness of silver diamine fluoride and sodium fluoride varnish in arresting dentin caries in Chinese pre-school children. *Journal of dental research, 81*(11), 767-770.

Chu, C., & Lo, E. C. (2008). Microhardness of dentine in primary teeth after topical fluoride applications. *Journal of Dentistry, 36*(6), 387-391.

Chu, C., Mei, M. L., & Lo, E. (2010). Use of fluorides in dental caries management. *General dentistry, 58*(1), 37-43; quiz 44.

Chu, C.-H., Lee, A. H. C., Zheng, L., Mei, M. L., & Chan, G. C.-F. (2014). Arresting rampant dental caries with silver diamine fluoride in a young teenager suffering from chronic oral graft versus host disease post-bone marrow transplantation: a case report. *BMC research notes, 7*(1), 1-14.

Chu, C. H., Mei, L., Seneviratne, C. J., & Lo, E. C. M. (2012). Effects of silver diamine fluoride on dentine carious lesions induced by Streptococcus mutans and Actinomyces naeslundii biofilms. *International journal of paediatric dentistry, 22*(1), 2-10.

Craig, G., Knight, G., & McIntyre, J. (2012). Clinical evaluation of diamine silver fluoride/potassium iodide as a dentine desensitizing agent. A pilot study. *Australian dental journal, 57*(3), 308-311.

Crystal, Y. O., Janal, M. N., Hamilton, D. S., & Niederman, R. (2017). Parental perceptions and acceptance of silver diamine fluoride staining. *The Journal of the American Dental Association, 148*(7), 510-518. e514.

Crystal, Y. O., Marghalani, A. A., Ureles, S. D., Wright, J. T., Sulyanto, R., Divaris, K., Fontana, M., & Graham, L. (2017). Use of silver diamine fluoride for dental caries management in children and adolescents, including those with special health care needs. *Pediatric dentistry, 39*(5), 135E-145E.

DenBesten, P., & Li, W. (2011). Chronic fluoride toxicity: dental fluorosis. *Fluoride and the oral environment, 22*, 81-96.

dos Santos Jr, V. E., Vasconcelos Filho, A., Targino, A. G. R., Flores, M. A. P., Galembeck, A., Caldas Jr, A. F., & Rosenblatt, A. (2014). A new "Silver-Bullet" to treat caries in children–Nano Silver Fluoride: a randomised clinical trial. *Journal of Dentistry, 42*(8), 945-951.

Duangthip, D., Chu, C., & Lo, E. (2016). A randomized clinical trial on arresting dentine caries in preschool children by topical fluorides—18 month results. *Journal of Dentistry, 44*, 57-63.

Duangthip, D., Fung, M., Wong, M., Chu, C., & Lo, E. (2018). Adverse effects of silver diamine fluoride treatment among preschool children. *Journal of dental research, 97*(4), 395-401.

Everett, F. G., Hall, W., & Phatak, N. M. (1966). Treatment of hypersensitive dentin. *Journal of oral therapeutics and pharmacology, 2*(4), 300-310.

Frencken, J. E., Pilot, T., Songpaisan, Y., & Phantumvanit, P. (1996). Atraumatic restorative treatment (ART): rationale, technique, and development. *Journal of public health dentistry, 56*(3), 135-140.

Fung, M., Duangthip, D., Wong, M., Lo, E., & Chu, C. (2016). Arresting dentine caries with different concentration and periodicity of silver diamine fluoride. *JDR Clinical & Translational Research, 1*(2), 143-152.

Gotjamanos, T. (1996). Pulp response in primary teeth with deep residual caries treated with silver fluoride and glass ionomer cement ('atraumatic'technique). *Australian dental journal, 41*(5), 328-334.

Hamama, H., Yiu, C., & Burrow, M. (2015). Effect of silver diamine fluoride and potassium iodide on residual bacteria in dentinal tubules. *Australian dental journal, 60*(1), 80-87.

Hiraishi, N., Yiu, C. K., King, N. M., Tagami, J., & Tay, F. R. (2010). Antimicrobial efficacy of 3.8% silver diamine fluoride and its effect on root dentin. *Journal of endodontics, 36*(6), 1026-1029.

Horst, J. A., Ellenikiotis, H., Milgrom, P. M., & Committee, U. S. C. A. (2016). UCSF protocol for caries arrest using silver diamine fluoride: rationale,

indications, and consent. *Journal of the California Dental Association, 44*(1), 16.

Hu, S., Meyer, B., & Duggal, M. (2018). A silver renaissance in dentistry. *European Archives of Paediatric Dentistry, 19*(4), 221-227.

James, P., & Parfitt, G. (1954). A clinical note on the use of silver nitrate in the prevention of fissure caries in newly erupted first permanant molars. *Br. Dent. J, 96*, 35-36.

Kawasaki, A., Suge, T., Ishikawa, K., Ozaki, K., Matsuo, T., & Ebisu, S. (2005). Ammonium hexafluorosilicate increased acid resistance of bovine enamel and dentine. *Journal of Materials Science: Materials in Medicine, 16*(5), 461-466.

Knight, G., McIntyre, J., Craig, G., Zilm, P., & Gully, N. (2005). An in vitro model to measure the effect of a silver fluoride and potassium iodide treatment on the permeability of demineralized dentine to Streptococcus mutans. *Australian dental journal, 50*(4), 242-245.

Knight, G. M., & McIntyre, J. (2006). The effect of silver fluoride and potassium iodide on the bond strength of auto cure glass ionomer cement to dentine. *Australian dental journal, 51*(1), 42-45.

Korwar, A., Sharma, S., Logani, A., & Shah, N. (2015). Pulp response to high fluoride releasing glass ionomer, silver diamine fluoride, and calcium hydroxide used for indirect pulp treatment: An in-vivo comparative study. *Contemporary clinical dentistry, 6*(3), 288.

Law, A., & Messer, H. (2004). An evidence-based analysis of the antibacterial effectiveness of intracanal medicaments. *Journal of endodontics, 30*(10), 689-694.

Li, R., Lo, E., Chu, C., & Liu, B. (2015). Arresting root caries through fluoride applications: 2-year result. Journal of Dental Research Meeting Abstracts,

Llodra, J., Rodriguez, A., Ferrer, B., Menardia, V., Ramos, T., & Morato, M. (2005). Efficacy of silver diamine fluoride for caries reduction in primary teeth and first permanent molars of schoolchildren: 36-month clinical trial. *Journal of dental research, 84*(8), 721-724.

Lo, E., Chu, C., & Lin, H. (2001). A community-based caries control program for pre-school children using topical fluorides: 18-month results. *Journal of dental research, 80*(12), 2071-2074.

Mathew, V. B., Madhusudhana, K., Sivakumar, N., Venugopal, T., & Reddy, R. K. (2012). Anti-microbial efficiency of silver diamine fluoride as an endodontic medicament–An ex vivo study. *Contemporary clinical dentistry, 3*(3), 262.

Mei, M. L., Chu, C. H., Lo, E. C., & Samaranayake, L. P. (2013). Preventing root caries development under oral biofilm challenge in an artificial mouth. *Medicina oral, patologia oral y cirugia bucal, 18*(4), e557.

Mei, M. L., Chu, C. H., Lo, E. C. M., & Samaranayake, L. P. (2013). Fluoride and silver concentrations of silver diammine fluoride solutions for dental use. *International journal of paediatric dentistry, 23*(4), 279-285.

Mei, M. L., Chu, C. H., Low, K. H., Che, C. M., & Lo, E. C. (2013). Caries arresting effect of silver diamine fluoride on dentine carious lesion with S. mutans and L. acidophilus dual-species cariogenic biofilm. *Medicina oral, patologia oral y cirugia bucal, 18*(6), e824.

Mei, M. L., Ito, L., Cao, Y., Lo, E. C., Li, Q., & Chu, C. (2014). An ex vivo study of arrested primary teeth caries with silver diamine fluoride therapy. *Journal of Dentistry, 42*(4), 395-402.

Mei, M. L., Lo, E., & Chu, C.-H. (2016). Clinical use of silver diamine fluoride in dental treatment. *Compend Contin Educ Dent, 37*(2), 93-98.

Nishino, M. (1969). Studies on the topical application of ammoniacal silver fluoride for the arrestment of dental caries. *J Osaka Univ Dent Sch, 14*, 1-14.

Okuyama, T. (1974). On the penetration of diammine silver fluoride into the carious dentin of deciduous teeth (author's transl). *Shigaku= Odontology; journal of Nihon Dental College, 61*(6), 1048-1071.

OPPERMANN, R. V., & JOHANSEN, J. R. (1980). Effect of fluoride and non-fluoride salts of copper, silver and tin on the acidogenicity of dental plaque in vivo. *European Journal of Oral Sciences, 88*(6), 476-480.

Quock, R., Barros, J., Yang, S., & Patel, S. (2012). Effect of silver diamine fluoride on microtensile bond strength to dentin. *Operative dentistry, 37*(6), 610-616.

Rosenblatt, A., Stamford, T., & Niederman, R. (2009). Silver diamine fluoride: a caries “silver-fluoride bullet”. *Journal of dental research, 88*(2), 116-125.

Rossi, G., Squassi, A., Mandalunis, P., & Kaplan, A. (2017). Effect of silver diamine fluoride (SDF) on the dentin-pulp complex: ex vivo histological analysis on human primary teeth and rat molars. *Acta Odontol Latinoam, 30*(1), 5-12.

Stebbins, E. (1891). What value has argenti nitras as a therapeutic agent in dentistry? *Int Dent J, 12*, 661-670.

Tan, H., Lo, E., Dyson, J., Luo, Y., & Corbet, E. (2010). A randomized trial on root caries prevention in elders. *Journal of dental research, 89*(10), 1086-1090.

Targino, A. G. R., Flores, M. A. P., dos Santos Junior, V. E., Bezerra, F. d. G. B., de Luna Freire, H., Galembeck, A., & Rosenblatt, A. (2014). An innovative approach to treating dental decay in children. A new anti-caries agent. *Journal of Materials Science: Materials in Medicine, 25*(8), 2041-2047.

Ten Cate, J., Damen, J., & Buijs, M. (1998). Inhibition of dentin demineralization by fluoride in vitro. *Caries research*, *32*(2), 141-147.

Vasquez, E., Zegarra, G., Chirinos, E., Castillo, J. L., Taves, D. R., Watson, G. E., Dills, R., Mancl, L. L., & Milgrom, P. (2012). Short term serum pharmacokinetics of diammine silver fluoride after oral application. *BMC Oral Health*, *12*(1), 1-7.

Wong, M. C., Lam, K., & Lo, E. C. (2011). Analysis of multilevel grouped survival data with time-varying regression coefficients. *Statistics in Medicine*, *30*(3), 250-259.

Wu, D. I., Velamakanni, S., Denisson, J., Yaman, P., Boynton, J. R., & Papagerakis, P. (2016). Effect of silver diamine fluoride (SDF) application on microtensile bonding strength of dentin in primary teeth. *Pediatric dentistry*, *38*(2), 148-153.

Wu, M.-Y., Suryanarayanan, K., Van Ooij, W., & Oerther, D. B. (2007). Using microbial genomics to evaluate the effectiveness of silver to prevent biofilm formation. *Water science and technology*, *55*(8-9), 413-419.

Yee, R., Holmgren, C., Mulder, J., Lama, D., Walker, D., & van Palenstein Helderman, W. (2009). Efficacy of silver diamine fluoride for arresting caries treatment. *Journal of dental research*, *88*(7), 644-647.

Yokoyama, K., Kimura, Y., Matsumoto, K., Fujishima, A., & Miyazaki, T. (2001). Preventive effect of tooth fracture by pulsed Nd: YAG laser irradiation with diamine silver fluoride solution. *Journal of clinical laser medicine & surgery*, *19*(6), 315-318.

Zhao, I. S., Gao, S. S., Hiraishi, N., Burrow, M. F., Duangthip, D., Mei, M. L., Lo, E. C.-M., & Chu, C.-H. (2018). Mechanisms of silver diamine fluoride on arresting caries: a literature review. *International dental journal*, *68*(2), 67-76.

Zhi, Q. H., Lo, E. C. M., & Lin, H. C. (2012). Randomized clinical trial on effectiveness of silver diamine fluoride and glass ionomer in arresting dentine caries in preschool children. *Journal of Dentistry*, *40*(11), 962-967.

CHAPTER 13

PSYCHIATRIC DATA ANALYSIS AND INTERPRETATION WITH ARTIFICIAL INTELLIGENCE, MACHINE LEARNING AND DEEP LEARNING

Ali Berkan URAL[1*], Uğur ERAY[2]

[1] PhD, Department of Electrical Electronics Engineering, Circuit and Systems/Biomedical, Kafkas University, Kars, Turkey. berkan.ural@kafkas.edu.tr

[2] PhD, MD, Department of Medical School, Psychiatry, Kafkas University, Kars, Turkey.drugureray@gmail.com

[*]Corresponding author: Ali Berkan URAL.uralberkan@gmail.com

INTRODUCTION

Artificial Intelligence (AI), Machine Learning (ML) and Deep Learning (DL) methods have been soaringly chosen and used in data set to distinguish patients with psychiatric and neurological problems. There have not been any quantitative methods to be applied in psychiatric disorders yet. Deep learning is generally a subbranch of Machine Learning and today's core applications in health care have gained popularity. Since the arrival of computational psychiatry, studies based on functional magnetic resonance imaging (f-MRI), EEG signals, Polysomnography (PSG) signals have achieved with important results, but these tools can sometimes be too expensive for everday clinical usage. Indeed, DL and its models can be expressed as powerful tools for analyzing, classfication and interpretation for large scale data analysis instead of small scale data analysis. Today, psychiatry has to gain an ultimate understanding of the total mechanism for psychiatric disorders to deliver more effective treatments. Modern algorithms and models from AI, ML and DL, especially DL, provide access to investigate these issues given their amazing prediction performance in Medicine and Biomedical Engineering areas. The strength of DL can be expressed that DL models can be very complicated models and this power comes from big training and test samples to analyze. Generally, in psychiatry, big data analysis and obtaining better classification, prediction results (accuracy, eccentricity etc.) are commonly important. For this study, the aim is giving an detailed overview on how such models have been used in psychiatry. Also we review AI, ML and DL methods and applications compare to more traditional statistical approaches and which aspects we can achieve to do optimally use the powerful techniques of AI, ML and DL in psychiatric neuroscience.

Some of the current diagnostic procedures in psychiatry and neuroimaging need improvement. While today's these procedures are optimized for reliability, the underlying cases can be more complex, because the psychiatric disorders have a big diversity because of the different behaviour and the feedback of the brain. It is important that changes in mechanism of neurons may cause different outputs/behaviors depending on the neurological case. These phenomenon often explains why a specific group of individuals respond to the psychiatric drugs and psychotherapeutic treatment for any psychiatric and neurological problems/disorders. According

to this situation, a categorical conventional diagnoses has been required for personalized forms of therapy.

There were novel achievements that Artifical Intelligence (AI) algorithms, in particularly from DL and ML fields, can overcome these challanges. With using DL methods, when gathered with large data set, these models might have an amazing potential for heathcare areas. For example, Deep Neural Network (DNN) based models can give highly successful results rather than expert knowledge in medical and biomedical engineering areas. This ability is came from the automatic feature extraction part and this aspect can gain more popularity to DL models in these areas. Some DL models have already been used and adopted to automatically detect the breast cancer, brain cancer and more areas have been chosen and used. Attempts to collect big data, including for instance data on brain function and imaging, behaviour on cognitive task, have been specifically and publicly given by different consortia and funders (ABIDE, OASIS, ASD, SZ etc.).

In the analyzing part, we can sometimes ask ourselves that how much data do we need for "big data". In medical fields, data set can be small in complex designed experiments. Also, some methods to generate a large data, are generally applied to a limited number of human participants. Can AI, ML and DL models be used efficiently on such comparatively different small data bases?

In the next part, some important reviews of Autism Spectrum Disorder, Schizophrenia, Attention Deficit Hyperactivity Disorder, Other Psychiatric Disorders were given in detail, respectively.

1. REVIEW OF IMPORTANT STUDIES FOR COMMON PSYCHIATRIC DISEASES

1.1. Literature Review Of Autism Spectrum Disorder (ASD)

Autism spectrum disorders (autism) are a group of neurodevelopmental disorders with pervasive impairments in social communication and interaction, and limited and repetitive behavioral patterns.

The worldwide prevalence of autism is nearly 1% and estimates are higher in high-income regions. Although major brain pathology is not characteristic of autism, functional and anatomical changes have been observed in postmortem neuroimaging and electrophysiological studies.

Despite MRI does not provide definitive results in autism, structural and functional MRI can facilitate the understanding of how the brain develops structurally and functionally differently in people with autism.

In the future, MRI could be well suited to categorize subgroups of autism and to differentiate commonalities and distinctions between other developmental disorders.

Early diagnosis and intervention in autism is seen as an important priority. Because many young children with autism struggle to communicate and interact with others, learning opportunities are restricted, and it affects parents who find their child's behavior confusing and difficult to manage.

Analyzing neuroimaging with artificial intelligence techniques will facilitate clinical diagnosis and treatment orientations.

It is now clear that autism is primarily a genetic disorder and the behaviors seen are caused by the complex interaction between common or rare genetic variants.

According to the literature, most of the data set were obtained from Autism Brain Imaging Data Exchange (ABIDE) and the general features of the data set was over 2000 (structural and functional Magnetic Resonance Imaging (MRI) scans of autistic children). Three studies have used s-MRI as input of AI, ML and DL models. Li et al. (2018) used 3D CNNs on structural MRIs (s-MRIs) of the National database of autism research data set with 76.2% accuracy. Pinaya et al. (2019) avhieved a deep autoencoder to obtain the changes in ABIDE set with 64% ROC accuracy. Ismail et al (2017) developed a stacked auto encoder on Cumulative Distribution Function with the highest accuracy as 92.8%.

Indeed, there were three studies that have used both structural and functional MRI as input to the DL model (Sen et al., 2018; Aghdam et al., 2019; Mellema et al., 2019) reported the highest accuracy of 80.4% on a large dataset (n = 915) data set into an MLP. Finally, there were three studies that have applied on 3D input data (Khosla et al., 2019; Li X. et al., 2018; Li G. et al., 2018). Khosla et al. (2019) used the largest and heterogeneous dataset (n = 774, sites = 17) and achieved 73.5% by using an ensemble Convolutional Neural Networks.

1.2. Review Of Schizophrenia (SZ)

Schizophrenia is an often chronic and disabling disease characterized by heterogeneous clusters of positive and negative symptoms. Positive symptoms reflect an excess or disruption of normal function (eg, delusions, hallucinations, disorganized behavior), while negative symptoms indicate a decrease or absence of normal behaviors related to motivation and interest (eg, aversion, anhedonia, asociality)

Schizophrenia is one of the top 20 causes of disability in the world, and the lifetime prevalence of schizophrenia is estimated to be about 0.7%. Comorbidity with other psychiatric or organic disorders, including substance use disorders, is common in patients with schizophrenia, contributing to morbidity and mortality in patients. In addition, approximately 4-10% of patients with schizophrenia die by suicide.

Many neuroimaging studies have tried to relate the symptoms of schizophrenia to the altered structure or function of certain brain regions and circuits. Progress has been made in associating some aspects of the disorder with the specific underlying neurobiology, and several lines of evidence imply the involvement of the prefrontal cortex specifically in certain cognitive deficits (for example, working memory and executive control). However, gray matter reductions and white matter abnormalities have been found in many brain regions and circuits. Decreased gray matter progresses with disease duration, particularly in the temporal lobe, and appears to be related to antipsychotic therapy. However, volume reductions are seen (although not as markedly as in treated patients), particularly in the caudate nucleus and thalamus, even in drug-naïve patients.

Schizophrenia is a complex neuropsychiatric syndrome with heterogeneous genetic, neurobiological and phenotypic profiles. Currently, no objective biological measures, ie biomarkers, are available to make diagnostic or treatment decisions. Neuroimaging is well positioned for biomarker development in schizophrenia, as it can capture phenotypic variations in brain circuits. Effective biomarkers can validate new treatment targets or pathways, predict response, assist in patient selection for treatment, identify treatment regimens, and provide a rationale for personalized treatments.

Similar to the other disorders, the first papers on deep learning for schizophrenia classification appeared in 2016 and in the last 3 years many papers have followed. In contrast to ASD, there was a variety in datasets used as MCIC and COBRE. The important studies of (Yan, 2017; Yan et al., 2019) with a cohort of 1100 subjects achieved with 80% accuracy. Yet, the SZ sample could be more homogeneous and a model on FC matrices of group independent component analysis (ICA) was achieved. The first model on the FC matrices using an MLP outperformed a Convolutional Recurrent Network on timeseries with 84.8% vs 83.2% accuracy values.Some s-MRI modal features including cortical thickness, surface area, volume, white matter volume and intensity measures from cortical parcellation and fMRI features were used with ICA with 99.3% accuracy on the COBRE dataset (Qureshi et al., 2017). In a second study the performance decreased to 98.1% (Qureshi et al., 2019) when applying 3D convolution neural networks on 3D images of the same group via ICA method. There were two other studies applying a convolutional network, both reporting accuracies over 80% (Lei et al., 2020; Oh et al., 2019) with different approaches. Lei et al. (2020) used different inputs and obtained the highest results with a 2D CNN on FC matrices. Oh et al. (2019) used a 3D convolution autoencoder based on contrast images of f-fMRI.

Seven studies was achieved with using the COBRE dataset and the highest accuracies were obtained from (Qureshi et al., 2017, 2019b), followed by Patel et al. (2016) with an accuracy of 92%. Chyzhyk et al. (2015) obtained a similarly high accuracy of 91% with a different approach; they used an algorithm for feature selection with homotopic connectivity maps. Yang et al. (2019) also used an ensemble of networks to identify the multiple image features with 82.8% accuracy. Indeed, Zeng et al. (2018) used discriminative features from correlation matrices using an autoencoder for SVM classification.

1.3. Review Of Attention Deficit Hyperactivity Disorder (ADHD)

Attention deficit/hyperactivity disorder (ADHD) is among the most commonly diagnosed neurodevelopmental disorders, affecting approximately 8-12% of children worldwide, and up to 65% continue to experience ADHD symptoms and neuropsychological disorders into adulthood.

The diagnosis of ADHD is typically made by a clinician based on the number, severity, and duration of behavioral symptoms observed by parents/caregivers and teachers. Currently, the diagnosis of ADHD is characterized by age-inappropriate inattention and/or hyperactivity-impulsivity symptoms, categorized into three presentations: predominantly inattentive, predominantly hyperactive/impulsive, and combined presentation

ADHD is often accompanied by comorbid disorders such as oppositional defiant disorder and conduct disorder. At the neuropsychological level, children with ADHD are known to perform worse than their typically developing peers in measures of reaction time variability, intelligence/achievement, alertness, working memory, and response inhibition.

Several major neural networks have been associated with ADHD, including the default mode network (DMN), dorsal and ventral attention networks, salience networks, and frontostriatal and mesocorticolimbic circuits (or dopaminergic mesolimbic system), although neuroimaging findings are not yet conclusive in diagnosis. Functional neuroimaging studies have shown reduced connectivity in the DMN of children aged 6-17 years with ADHD, a pattern suggestive of delayed DMN neuromaturation, consistent with previous structural MRI studies thought to indicate delayed maturation of the cerebral cortex.

Early recognition and treatment of ADHD and its comorbidities have the potential to alter the course of psychiatric morbidity later in life.Children with ADHD have a high risk of accompanying depression, anxiety disorders, and substance use disorders in adult life if they are not properly diagnosed and treated.

Currently, there is no neural biomarker that can be used in the diagnosis, but neuroimaging studies aimed to characterize the structural and functional brain correlates of ADHD, and it is thought that this will help clinicians.

Some studies were given for ADHD classification. Three studies have achieved classification of the ADHD with accuracies ranging from 27 to 65 (for 4 different groups). The highest performance was reported by Hao et al. (2015) that achieved 64.7% via Bayesian network on rs-fMRI data. For bivariate classification of ADHD the highest accuracy was reported by Deshpande et al. (2015). They used a fully connected cascade neural network and obtained 90% accuracy.

Wang et al. (2019) applied 3D convolutions and obtained an accuracy of 77.6%. They also tested their model on SZ data and obtained an accuracy of 82.2%. Sen et al. (2018) achieved the model that was tested on two psychiatric disorders; they developed an autoencoder to learn features from s-MRI and ICA from fMRI. These learned features were classified by an SVM classifier and obtain accuricies of 68% and 63%.

Three other studies used convolutions for classification (Wang and Kamata, 2019; Zou et al., 2017), all with different inputs: AAL timeseries (Riaz, et al., 2018), a combination of ReHo, fALFF and VHMC (Zou et al., 2017) or 3D structural maps 68.

2.REVIEW OF DEEP LEARNING AND COMMON MACHINE LEARNING STUDIES

In this review some important studies were analyzed and some DL models against standard machine learning methods were compared. The results of these studies are given as a graph form in Fig. 1.

Among the higher performance metrics of DL, only three studies had lower performance for DL (Lei et al., 2020; Miholca and Onicas¸, 2017; Vyskovsky et al., 2019): Lei et al. (2020) compared many different models of SVM. In Vyskovsky et al. (2019) was achieved an ensemble of MLPs with ensemble SVMs for schizophrenia classification. Finally, in Miholca and Onicas¸ (2017) a new ML technique was achieved and better accuracy score was obtained than a MLP.

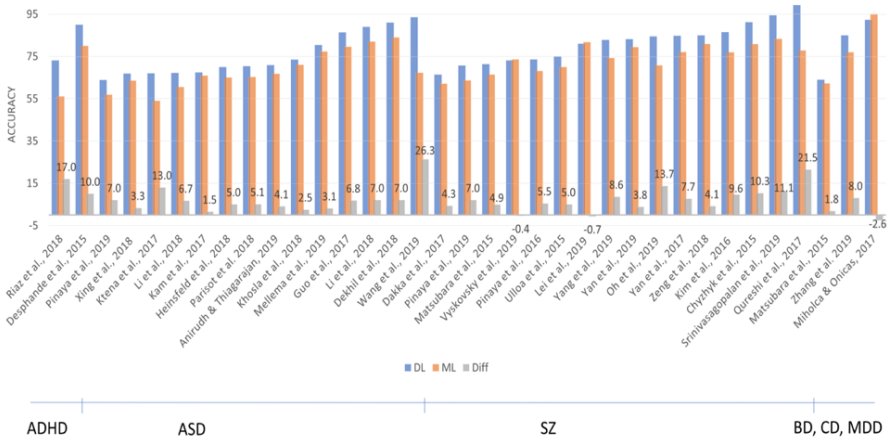

Figure 1: Performance Metrics Of Some Important Studies Of DL and ML (Quakk et al. (2021))

3. BIG AND SMALL DATA ANALYSIS IN PSYCHIATRY

3.1. Big And Small Data Analysis Via Trend Statistics, ML and DL Models In Psychiatry

Clinical psychiatry is generally based on self-observation and self-report which are sometimes subjective. There are not any specifical boundaries available for anable objective diagnosis in psychiatry. Today, the helathy and diseased brain can be captured by using specific neuroimaging models such as structural and functional MRI. With the advent of novel efficient methods such as ML and DL models, making predictions on new data are developed by mathemtical models and algorithms. An important advantage of ML and DL methods is their ability to give a chanve for enabling detection of distributed effects in the brain and also allowing statistical inference for individual diagnostic or prognostic decision processes.

Such pattern analysis methods (LDA, SVM etc.) can be expressed as well-designed methods, and generally applied to psychiatric and neuroimaging data to detect psychiatric disease with a remarkable success rate. Classification and interpretation studies mainly and usually require some pre-processing parts involving data normalization, feature extraction and feature selection to eliminate/reduce the input dimensions for obtaining more accurate results. With developing the DL methods, the models can be

explained as specific models that achieve higher complexity by using nonlinear transformations. This specific ability makes DL more suitable for neuroimaging such as psychiatric disorders/problems are sometimes characterised by different complex patterns. Indeed, an important difference between ML and DL is that learning process of optimal feature representation from the raw data is achieved in DL. The whole results are more objective and less bias susceptible process in DL.

However, there are different techniques and processing steps for analyzing psychiatric disorders within DL studies. A majör challange of DL in this area is the high dimensionalty of data. Variety of studies showed that using hand crafted input features with different feature extraction steps to reduce the input dimensionality.

Given the popularity of ML and DL methods within the psychiatry and some approaches, this review aims to give an ultimate overview of methods and models that have applied ML and DL to neuroimaging data fort he classification of psychiatric disorders.

Such methods of imaging are widely chosen in laboratories of experimental psychology and for research in neuroscience. The Electroencephalography (EEG) is much cheaper and common method than other methods. Indeed, this method can be defined as a practically non-invasive technique. EEG and its methods have been developed for many years. Recently, there has been an advance in the use of Brain-Computer interfaces in which the acquisition of electrical activity of the specifically selected areas of brain cortex. Today, development of the neurocomputing, AI and its subbranches have gained more popularity. The computational approach can express some behaviour characteristic of complex systems.

In current psychiatry, the common tool for diagnosing is still the clinical interview progress. This process allows psychiatristt to choose the optimal method of treatment. There are variety of EEG signal representation, but one of the oldest method is its characteristics in frequency bands that describes the case of its waves. Indeed, there are some different bands that in the literature (δ—delta band (< 4 Hz), θ—theta (4–7 Hz), α—alpha (8–15 Hz), β—beta (16– 31 Hz), γ —gamma (> 31 Hz) and sometimes μ—mu (8–12 Hz).

In general, neuroimaging data classification may not be an easy try. Accordingly, Deep Neural Networks (DNNs) have shown important results in detecting psychiatric disorders. Most studies have focused on investigating dementia and attention deficit hyperactivity disorder with using large publically available neuroimaging data sets (OASIS, ADHD-200 databases etc.). Notably, a few of these studies also investigated the ability to identify Alzheimer's disease (AD), which is essential to detect disease at an early stage. Studies classifying other mental disorders such as schizophrenia, autism, Parkinson's disease, depression, substance abuse disorder, and epilepsy are slowly investigating as well.

Sometimes psychiatric symtomps cause from multiple processes and also more traditional classifiers like Suuport Vector Machines (SVMs) and Linear Discriminant Analysis (LDA) have been fed with multiple features with modalities in the studies. However, it is too early to say how DL model and data modality affect classification performance.

According to the low sample size issues and multi-modal integration, the data is usually used as high-dimensional data in neurostudies. For a single imaging modality, current sample sizes are in the modest range of 10^2–10^4. Training models in DL with some parameters on small sample sizes create a severe challenge to find solutions fort he population.

Apart from the customized SVM and other classifiers, Deep Learning technologies, which are increasingly popular, have been used as another step in the classification approach and this technology has been followed in software development. For Deep Learning methods, a specific n-layer convolutional neural network can be prepared and based on the parameters mentioned above, the psychiatric disease can be estimated and interpreted as a preliminary diagnosis. One advantage of Deep Learning methods is that they increase interface rendering rate by minimizing the attribution data extraction step for audience regions.

For instance, Convolutional Neural Networks (CNNs) which are particularly suited for processing raw imaging data eliminate the number of parameters through "weight sharing" and pooling of unit responses. Trials indicate that CNNs could be achieved with different architectures when predicting mental health related aspects from raw imaging data. Other studies have reduced the dimensionality of the input data. While some approaches

may be less effective for clinical applications, they obtain acceptable results for small samples (of n < 100).

CNN is a deep learning model that has continued and evolved over the past decade. The CNN structure can automatically learn features from the input dataset, especially images. Convolutional layers are used to bend the input image with weights to obtain a feature map. The weights of the kernels can link the feature map units to the previous layer. Convolutional Neural Networks consist of neurons with learnable weights and pre-states. Each neuron takes some input, performs an inner product, and optionally follows it non-linearly.

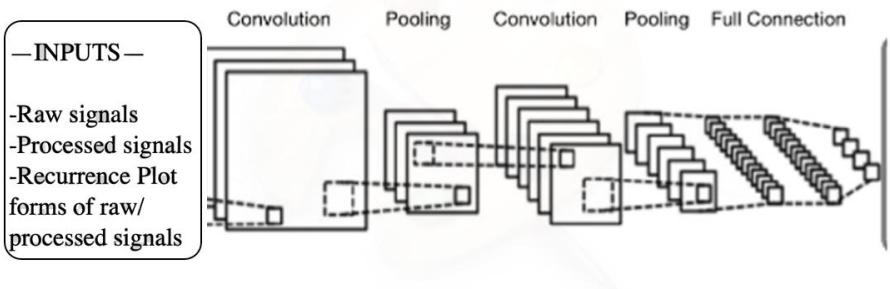

Figure 2. A Common CNN Architecture

Convolution is the first layer that extracts features from an input image. Convolution preserves the relationship between pixels by learning image features using small squares input data. It is a mathematical operation that takes two inputs, such as an image matrix and a filter or kernel.

The pooling layers section reduces the number of parameters when images are very large. Spatial pooling is also called downsampling and reduces the dimensionality of each map but preserves important information. Spatial pooling can be of different types:

- Maximum Pooling
- Average Pooling
- Total Docking

Maximum pooling takes the largest item from the adjusted feature map. Getting the largest element can also take the average pooling. The sum of all items in the feature map is called the aggregate pooling.

According to the diagram given above, the process was followed by applying the special pooling method covering the maximum, average and total pooling variations. In this approach, the mean pooling method was chosen and applied due to its effectiveness. Average pooling generally reduced the dimensions of the feature map while keeping the most significant feature values by shifting the kernels on the corrected map and capturing the mean values. Pooling has been implemented to make the data highly manageable with size reduction.

In the fully connected layer, the matrix is flattened to vector and fed into a fully connected layer, such as a neural network, where the feature map matrix will be converted into vector (x1, x2, x3, etc.). In the last part, there is the activation function.

There are mainly two types of CNN based structures that are frequently used in the MATLAB environment: AlexNet and Visual Geometry Group (VGG) were chosen for the classification and interpretation stages. The AlexNet model was chosen because of its useful modification situations and its ability to finish faster than other simple models.

Typically, Deep Learning is a sub-branch of machine learning like the human brain. In recent years, Deep Learning field and methods have gained popularity in many fields of study. The use of Artificial Intelligence and Deep Learning is very common in medicine, and with their use, medical data can become more meaningful to scientists and doctors.

There are many studies on Deep Learning in the literature. On the contrary, the biggest problem in analyzing medical dataset is that there is a limited number of datasets available to doctors. Unlike Artificial Intelligence, Deep Learning methods and models require a particularly large amount of data. Labeling these data one by one is very laborious and time consuming. The biggest alternative of Transfer Learning to using Deep Learning models is that it allows the training process with less data.

With new versions and versions of MATLAB, AlexNet has become increasingly important and it is an improved version of the KSA model. AlexNet has 5 convolutional and 3 fully connected layers. In addition, it is

also referred to as the model that used the Redirected Activation Function (ReLU) for the first time.

Additionally, the ResNet-50 model is a more advanced version of CNN and AlexNet. When the network deepens and grows; this model avoids diffuse distortion [51]. ResNet solves this problem by not only connecting the previous layer to the current layer, but also connecting the layer behind the previous layer. By including this, each layer can now see more than the previous layer's observations. In this model, the process connects the input layer to a 2D convolution (Conv2D) layer with specified filters and then adds a BatchNormalization layer to which a Rectified Activation (ReLU) layer is added and then another Conv2D layer is stacked. This stacked output is then added to the first input, but the first input is transformed by passing it through a Conv2D layer of the given filters. This step is done to match the output sizes of both layers to be added. Then, having a MaxPooling2D layer, that layer is added, and if any Dropout value is also given, a Dropout layer is also added to the network, and finally a BatchNormalization layer and Activation layer are added. Overall, ResNet50 is a complex 50-layer network trained on an ImageNet database. The models input has an image size of 255x255 (x3) and the output is mainly disease classes.

As given in previous section, psychiatric researches need to achieve a variety of challanges, including the identification for robust diagnosis and the interpretation of disease types of patients.

For a classification problem, predicting responses or symptom severity or to distinguish problems between diagnosed with psychiatric disorders and healthy individuals. Fundamentally, the input variables come from these situations given above and the maight come from several modalities. If we assume that the outputs are class labels (clinical diagnoses), this is called a regression/classification problem and also a training-set.

Generally, when the model training or in statistical terms, models estimation/interpretation, such a loss function can be. Instead of this, the Mean-Squared Error (MSE), the average sum of squared deviations between true phenomenon and predicted results etc. In supervised case, a loss function may be type of measure that defines the structure in the data.

Moreover, when we investigate similarities or differences between Hypothesis testing versus Prediction parts, there are not any differences

between statistical models and ML&DL. The main discrimination between hypothesis testing and prediction consists from important cases. While common statistics has been more concerned with testing, ML or DL softwares have been more interested in the prediction/interpretation processes.

In classical hypothesis testing part, a probabilistic situation of the data has been evaluated and sometimes this has been formulated in term of the parameters of the model and the main purpose is to obtain a probability for how likely a case which is related to the hypothesis holds in the whole population according to the given the model assumptions (finite or infinite).

Other important issue can be defined as the stated models may be probabilistic or deterministic. For hypothesis testing progress, there may be some random variables and probability distributions involved. Sometimes, the relationships between input and output variables are formulated with the probability functions. According to the modern ML and DL models, they can provide a hybrid sense of the uncertainty related to the predictions. However, this makes formal testing is fundamental, these models given above and their probability distributions are generally difficult to handle.

3.2. Big And Small Data Analysis Via Trend AI Models In Psychiatry

After image processing, generally, pattern recognition and binarization processes, Feature Extraction has begun and the features have been used as the inputs in AI models. For this part, generally, Feature Extraction has been achieved via graycomatrix, grayprops, Wavelet Transform etc.

In the part of identification and interpretation of data, firstly, a two-stage cyclical system is taken as reference in the interpretation of psychological signals. Feature extraction step includes obtaining numerical data for the problem regions determined according to medical and image/signal processing regions (Contrast, Correlation, Homogeneity, Variance, Energy, Entropy, Mean, Standard Deviation, etc.) and analyzing parametric variables. The output of the feature extraction step is a numeric matrix containing the features listed above.

All these calculated numerical features form a separate feature vector for the data. These vectors were first given as an input to the SVM, which is a classical artificial intelligence method, and it was learned by the system.

Classification can generally be defined as distinguishing and identifying situations or objects with similar characteristics from those with other different characteristics. Although classification takes place in many parts of the computer and medicine fields, the purpose of the classification process in this study is to determine which class the attribute/feature data obtained from the images belong to with a decision support mechanism.

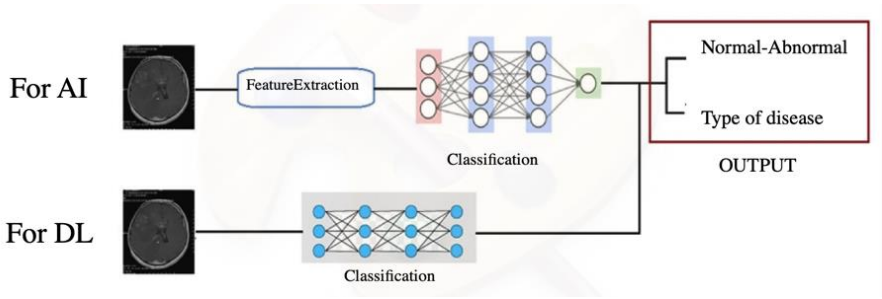

Figure 3: Differences Between AI and DL Processes

The Support Vector Machine (SVM) algorithm is an important and effective classifier that is frequently used in the literature. SVM is basically included in the literature as an effective machine learning method for pattern recognition, decision making and classification processes. The SVM algorithm, which allows to work on large data sets in order to extract important information from data sets, is an algorithm based on mapping the input space into the high-dimensional feature space with the kernel method. SVM is a method based on inherent risk minimization rather than error minimization. The main goal in the SVM algorithm is to create a learning task with a given finite amount of training data. The SVM learning method is implemented with an optimally separated hyperplane that maximizes the margin. The term margin used here means the shortest distance to the data point in said hyperplane. If the training set cannot be linearly separated by a separator plane in SVM, these examples are performed by passing from the input space to the multidimensional feature space.

If the x_i (i=1, 2, …, k) data set entries belonging to two classes labeled -1 and +1 in an N-dimensional space can be linearly separated from each other, this separator plane is expressed by Equation (1).

$$f(x)=wx_i+b \tag{1}$$

If $f(x)>1$, $y_i=1$;
If $f(x)<1$, $y_i=-1$

In the equation given above, w is the n-dimensional weight vector and b is a scalar coefficient. With this equation, there are maximum decision range limits to distinguish between positive and negative classes. This interval is the sum of the closest distances of both classes from the separating hyperplane. The plane where this sum is maximum represents the optimum plane. The decision interval boundaries are here determined only by support vectors.

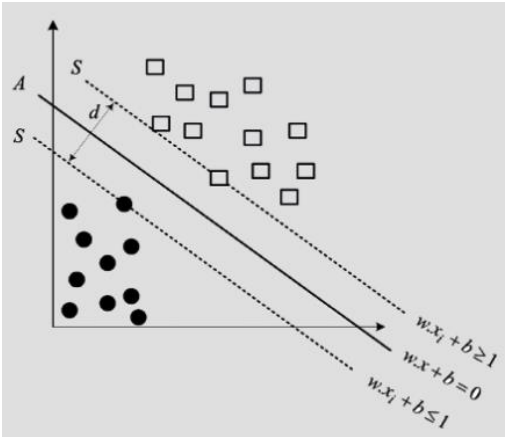

Figure 4: The Process Of Separating The Data Of Two Classes With SVM

The distance d in the figure above is denoted by 2/norm(w).

For an optimal state extreme plane, the distance d should be maximized and in this case the norm value should be minimized. In this case, the Lagrange multipliers method is applied mathematically.

Indeed, k-Nearest-Neighbour classifier is basically a non-parametric learning algorithm (no assumptions are made on the data distribution). Many cases in theory and in the literature do not fit the Gaussian and linearly separable case. In addition, this algorithm does not use the points of the training data to introduce a generalization case. The training phase is a highly unlikely situation.

The k-NN is used to perform a basic classification based on the distance, and the mentioned neighborhood determination is based on the minimum distance from the test samples to the training samples. The class of test samples is determined by the majority of the nearest neighbors. In this algorithm, it is based on deciding that the class of test samples will be the same as the nearest neighbor. The situation that the data observed close to each other will have the same class is seen as a highly compatible choice.

Commonly, Euclidean distance is used in this algorithm as the measure distance. Euclidean distance in N-dimensional space is given in Equation (2).

$$d(a,b) = \sqrt{\sum_{i=1}^{N}(a_i - b_i)^2} \qquad (2)$$

In this equation, pi, qi and i are coordinates, and the k parameter should be chosen very carefully in classification with this algorithm. It is not clear which one will be used and work best at distance based on learning.

For each type of disease, signals of patients were used in the classification stage with the k-NN mentioned above. As required by the k-NN structure, the attribute matrices of features of the disease types in a network cluster and their related names were recorded as tags, and the interpretation of a population detected in a different test image uploaded to the system was made according to these data.

AdaBoost, short for Adaptive Boosting, is a machine learning meta-algorithm formulated by Yoav Freund and Robert Schapire, whose work won the 2003 Gödel Prize. AdaBoost is a collective learning method (also known as "meta-learning") that was originally created to increase the efficiency of binary classifiers. AdaBoost uses an iterative approach to learn from the

mistakes of weak classifiers and transform them into strong ones. Every learning algorithm tends to suit some types of problems better than others and typically has many different parameters and configurations to adjust before reaching optimum performance on a dataset. In general, Adaboost is referred to as the best classifier. When used with decision tree learning, information about the relative 'hardness' of each training sample collected at each stage of the AdaBoost algorithm is fed into the tree-growing algorithm, so later trees tend to focus on examples that are more difficult to classify.

AdaBoost refers to a specific method of training a powered classifier and its classifier form is given in Equation (3).

$$f(x) = \sum_{t=1}^{T} f_i(x) \tag{3}$$

$x_1 \in R^n,\ y_1 \in \{-1, 1\}$

Here, n is the size of the real numbers or the number of features in the dataset. “x” is the set of data points. “y” is the target variable that is -1 or 1.

AdaBoost assigns weights to each training sample to determine its importance in the training dataset. When the assigned weights are high, this set of training data points is likely to have more say in the training set.

$$w = \frac{1}{N} \in [0, 1] \tag{4}$$

In Equation (4), N is the total number of data points. The sum of the weighted samples is always 1, so the value of each weight will always be between 0 and 1. After that, the calculation of the actual effect on the classification of the data points for this classifier is provided by Equation (5).

$$\alpha = \frac{1}{2} ln \frac{1 - toplam\ hata}{toplam\ hata} \tag{5}$$

After entering the actual values of the total error for each data, the process of updating the sample weights, which we initially took as 1/N for each data point, is performed with Equation (6).

$$w = w_{i-1} * e^{\pm a} \quad (6)$$

Two states (positive or negative) for alpha indicate:

Alpha is positive when the predicted and actual output match (meaning the sample has been correctly classified).

Alpha is negative when the predicted output does not match the actual class (meaning the sample was misclassified). In this case, it is necessary to increase the sample weight for achieve-ing the misclassification.

In the above-mentioned Adaboost classification stage, signal of psychiatric patients were used for each type of disease. As required by the structure of the Adaboost algorithm, the attribute matrices of defined attributes of the disease types in a network cluster and their related names were recorded as labels, and the interpretation of a disease detected in a different test signals/images uploaded to the system was made according to these data.

4. TRAINING ALGORITHM OF MODELS

There are some steps that DL models can take to improve finding an acceptable solution. The first main progress can be defined as initialization. Then the next progress is called model/parameter selection. In this step, user of DL has to be alter parameters to obtain a better model. Indeed, the loss function is gradually adaptized or modified after training process. For this case, model complexity and sample size are crucial fort he parts given above. The most aspects of a training part are the scaling with data size and parameters and steps for taking to escape local minima value and dealing with regions of slope in the loss function. According to the literature, the popular/trend approach of DNNs is stochastic gradient descent (SGD) via moving a local minimum of a function.

Moreoever, there are some extra ways to alleviate on the model side and improve solutions that obtain better results. One of these is reducing the dimensionality of the raw data or using the data adter pre-processing step. However, there may be cons of the preprocessing and feature selection parts, selection according to domain knowledge would be important and highly

predictive. For achieving this dilemma, DL models can be used to find useful data representations and features.

Sometimes, reducing the input dimension may not give better results, so we can also increase the sample size and variation within the sample. This approach is called data augmentation. For the data set there are several ways to do this; rotations, translations, rescaling, flipping, adding noise to data etc. To sum up, the sample size needed to succesfully train a AI, ML or DL model will depend on some factors such as type of data, size of network model, the of stochasticity in the data set, dimension parameters of the feature space, regularization cases etc.

5. CONCLUSION

Accurate diagnosis of psychiatric disorders is crucial for initiation and case of effective treatment. This review confirms that AI, ML and DL on neuroimaging are promising tools for development of biological diagnostic models for diagnosis. Despite still in its early stages, the application of DL in neuroimaging for psychiatric disorders has given important results. Moreoever, several improvements are needed before the full potential of DL in psychiatric neuroimaging can be achieved.

In conclusion, neuroimaging research in psychiatry using AI, ML and DL is still evolving to achieve better performance. While there are important challenges to overcome, our findings provide preliminary evidence supporting the promising role of DL in the future development for psychiatric disorders.

REFERENCES

Aghdam, M.A., Sharifi, A., Pedram, M.M. (2019). Diagnosis of Autism Spectrum Disorders in Young Children Based on Resting-State Functional Magnetic Resonance Imaging Data Using Convolutional Neural Networks. J Digit Imaging, 32 (6), 899–918.

Albajara Sáenz, A., Villemonteix, T., & Massat, I. (2019). Structural and functional neuroimaging in attention-deficit/hyperactivity disorder. Developmental Medicine & Child Neurology, 61(4), 399-405.

Bourgeron, T. (2016). Current knowledge on the genetics of autism and propositions for future research. Comptes rendus biologies, 339(7-8), 300-307.

Chyzhyk, D., Savio, A., Gran˜a, M. (2015). Computer aided diagnosis of schizophrenia on resting state fMRI data by ensembles of ELM. Neural Networks, 68, 23–33.

Correll, C. U., & Schooler, N. R. (2020). Negative symptoms in schizophrenia: a review and clinical guide for recognition, assessment, and treatment. Neuropsychiatric disease and treatment, 16, 519.

Deshpande, G., Wang, P., Rangaprakash, D., Wilamowski, B. (2015). Fully Connected Cascade Artificial Neural Network Architecture for Attention Deficit Hyperactivity Disorder Classification From Functional Magnetic Resonance Imaging Data. IEEE Trans. Cybern, 45, 2668–2679.

Durstewitz, D. (2017). Advanced data analysis in neuroscience: integrating statistical and computational models, NY, USA: Springer.

Durstewitz, D., Koppe, G., Toutounji, H. (2016). Computational models as statistical tools. Curr Opin Behav Sci, 11:93–99.

Edition, F. (2013). Diagnostic and statistical manual of mental disorders. Am Psychiatric Assoc, 21.

Huys, Q. J. M., Maia, T. V., Frank, M. J. (2016). Computational psychiatry as a bridge from neuroscience to clinical applications. Nat Neurosci, 19:404–13.

Katzman, M. A., Bilkey, T. S., Chokka, P. R., Fallu, A., & Klassen, L. J. (2017). Adult ADHD and comorbid disorders: clinical implications of a dimensional approach. BMC psychiatry, 17(1), 1-15.

Keepers, G. A., Fochtmann, L. J., Anzia, J. M., et al. (2020). The American Psychiatric Association practice guideline for the treatment of patients with schizophrenia. American Journal of Psychiatry, 177(9), 868-872.

Khosla, M., Jamison, K., Kuceyeski, A., Sabuncu, M.R. (2019). Ensemble learning with 3D convolutional neural networks for functional connectome-based prediction. NeuroImage, 199, 651–662.

Koppe, G., Meyer-Lindenberg, A., Dursewitz, D. (2021). Deep Learning for Small and Big Data In Psychiatry, Neuropsychopharmacology Reviews, 46:176-190.

Kraguljac, N. V., McDonald, W. M., Widge, A. S., Rodriguez, C. I., Tohen, M., & Nemeroff, C. B. (2021). Neuroimaging biomarkers in schizophrenia. American Journal of Psychiatry, appi-ajp.

Lei, D., et al. (2020). Detecting schizophrenia at the level of the individual: relative diagnostic value of whole-brain images, connectome-wide functional connectivity and graph-based metrics. Psychol. Med, 50 (11), 1852–1861.

Li X. et al. (2018). 2-Channel convolutional 3D deep neural network (2CC3D) for fMRI analysis: ASD classification and feature learning. In: 2018 IEEE 15th International Symposium on Biomedical Imaging (ISBI 2018), 1252–1255.

Li, G., Liu, M., Sun, Q., Shen, D., Wang, L. (2018). Early Diagnosis of Autism Disease by Multi-channel CNNs. Mach. Learn. Med. İmaging (MLMI), 11046, 303–309.

Lord, C., Charman, T., Cusack, J., Guillaume, D., Frazier, et al. (2020). Autism spectrum disorder (Primer). Nature Reviews: Disease Primers, 6(1).

Luo, Y., Weibman, D., Halperin, J. M., & Li, X. (2019). A review of heterogeneity in attention deficit/hyperactivity disorder (ADHD). Frontiers in human neuroscience, 13, 42.

Mellema, C., Treacher, A., Nguyen, K. & Montillo, A. (2019). Multiple Deep Learning Architectures Achieve Superior Performance Diagnosing Autism Spectrum Disorder Using Features Previously Extracted From Structural And Functional MRI. in 2019 IEEE 16th International Symposium on Biomedical Imaging (ISBI 2019).

Miholca, D., Onicas¸ A. (2017). Detecting depression from fMRI using relational association rules and artificial neural networks. In: 2017 13th IEEE International Conference on Intelligent Computer Communication and Processing (ICCP), pp. 85–92.

Oh, K., Kim, W., Shen, G., Piao, Y., Kang, N.-I., Oh, I.-S., Chung, Y.C. (2019). Classification of schizophrenia and normal controls using 3D convolutional neural network and outcome visualization. Schizophr. Res, 212, 186–195.

Owen, M. J., Sawa, A., & Mortensen, P. B. (2016). Schizophrenia. Lancet (London, England), 388(10039), 86–97.

Patel, P., Aggarwal, P., Gupta, A. (2016). Classification of schizophrenia versus normal subjects using deep learning. In: ACM International Conference Proceeding Series (Association for Computing Machinery).

Pinaya, W.H., Mechelli, A., Sato, J. R. (2019). Using deep autoencoders to identify abnormal brain structural patterns in neuropsychiatric disorders: A large scale multi sample study. Hum Brain Mapp. 40:944–54.

Posner, J., Polanczyk, G. V., & Sonuga-Barke, E. (2020). Attention-deficit hyperactivity disorder. The Lancet, 395(10222), 450-462.

Sen, B., Borle, N.C., Greiner, R., Brown, M.R.G., Bernhardt, B.C. (2018). A general prediction model for the detection of ADHD and Autism using structural and functional MRI. PLoS ONE 13, e0194856.

Ural, A. B. (2017). A Computer-Based Brain Tumor Detection Approach With Image Processing And Probabilistic Neural Network. Journal of Medical and Biological Engineering, 19 December 2017.

Ural, A. B., Özışık, P. & Hardalaç, F. (2019). An improved computer based diagnosis system for early detection of abnormal lesions in the brain tissues with using magnetic resonance and computerized tomography images, Multimed Tools Appl (2019).

Ural, A. B., Özışık, P., Hardalaç, F. (2021). Early Diagnosis System For Common Brain Masses, PhD Thesis, Gazi University, Electrical Electronics Engineering, Biomedical.

Quakk, M., Mortel, L. van de, Thomas, R. M., Wingen, G. Van (2021). Deep Learning Applications For the Classification Of Psychiatric Disorders Using Neuroimaging Data: Systematic Review and Meta-analysis, NeuroImage: Clinical, 30, 102584.

Qureshi, M.N.I., Oh, J., Cho, D., Jo, H.J., Lee, B. (2017). Multimodal discrimination of schizophrenia using hybrid weighted feature concatenation of brain functional connectivity and anatomical features with an extreme learning machine. Front. Neuroinform, 11, 1–14.

Qureshi, M.N.I., Oh, J., Lee, B. (2019). 3D-CNN based discrimination of schizophrenia using resting-state fMRI. Artif. Intell. Med, 98, 10–17.

Wang, T., Kamata, S. (2019). Classification of Structural MRI Images in Adhd Using 3D Fractal Dimension Complexity Map. In: 2019 IEEE International Conference on Image Processing (ICIP), pp. 215–219.

Yan, W., et al. (2017). Discriminating schizophrenia from normal controls using resting state functional network connectivity: A deep neural network and layer-wise relevance propagation method. In: 2017 IEEE 27th International Workshop on Machine Learning for Signal Processing (MLSP), pp. 1–6.

Wang, Z., Sun, Y., Shen, Q., Cao, L. (2019). Dilated 3D Convolutional Neural Networks for Brain MRI Data Classification. IEEE Access 7, 134388–134398.

Yan, W., et al. (2019). Discriminating schizophrenia using recurrent neural network applied on time courses of multi-site FMRI data. EBioMedicine, 47, 543–552.

Zou, L., Zheng, J., Miao, C., Mckeown, M.J., Wang, Z.J. (2017). 3D CNN Based Automatic Diagnosis of Attention Deficit Hyperactivity Disorder Using Functional and Structural MRI. IEEE Access 5, 23626–23636.



ISBN: 978-625-8405-09-5