EVALUATION OF CLINICAL TREATMENT METHODS IN NASAL BONE INJURIES

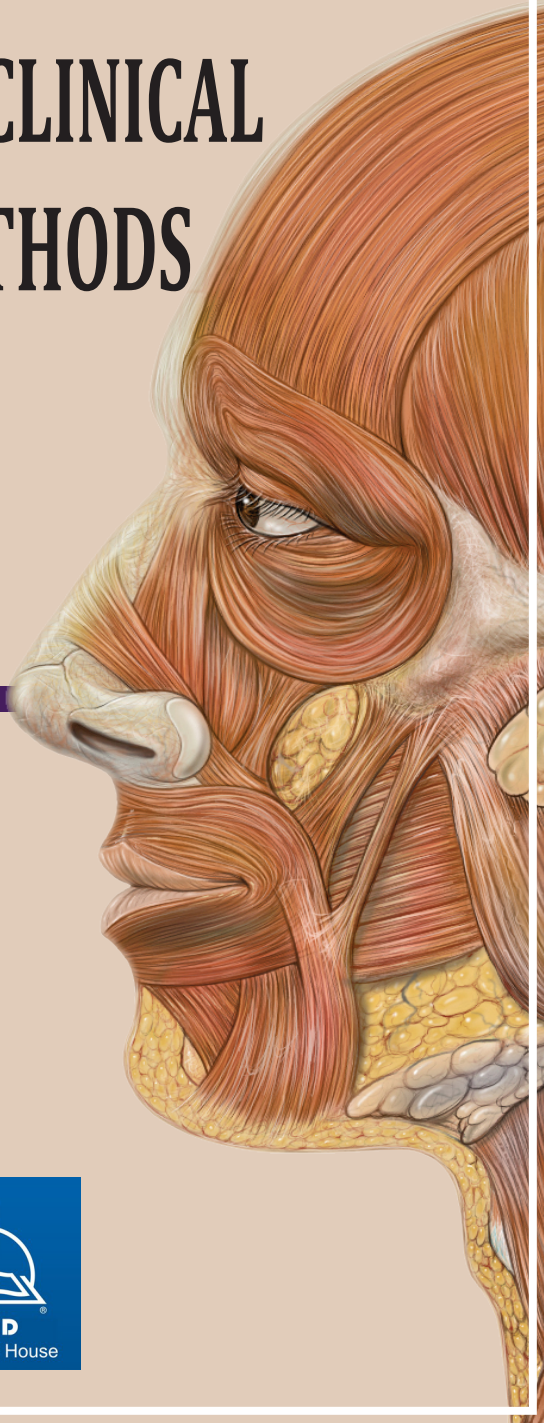

Berzan HAZNEDAR
İlhan ÖZDEMİR
Engin DEVECİ
Işılay Sezen ERMİŞ

İKSAD
Publishing House

EVALUATION OF CLINICAL TREATMENT METHODS IN NASAL BONE INJURIES

Berzan HAZNEDAR[1]

İlhan ÖZDEMİR[2]

Engin DEVECİ[3]

Işılay Sezen ERMİŞ[4]

İKSAD Publishing House

[1] Gazi Yaşargil Training and Research Hospital, KBB Clinic, Diyarbakır, Turkey., 0000-0002-4990-5260, drberzanhaznedar@gmail.com

[2] Atatürk University Faculty of Medicine, Department of Obstetrics and Gynecology,Erzurum,Turkey. 0000-0001-9957-0211, ilhanozdemir25@yandex.com

[3] Dicle University Faculty of Medicine Histology and Embryology Department,Diyarbakır, Turkey. 0000-0002-23531184 engindeveci64@gmail.com

[4] Harran University Faculty of Medicine, Department of Obstetrics and Gynecology, Şanlıurfa, Turkey. 000-00029714-4670 sezenermis@msn.com

(The Licence Number of Publicator: 2014/31220)
TURKEY TR: +90 342 606 06 75
USA: +1 631 685 0 853
E mail: iksadyayinevi@gmail.com
www.iksadyayinevi.com

ISBN: 978-625-8323-10-8
Cover Design: İbrahim KAYA
June / 2022
Ankara / Turkey
Size: 14,8x21 cm

Preface

The technology that has developed as a result of our studies and research has made a great contribution to the development of techniques in the treatment of rhinoplasty and nasal fractures, as in many areas. Thus, patients with nasal fractures receive much better treatment. Although there are simple procedures, some obstacles are inevitable. Today, nasal fractures are of great importance, and various methods have been developed to serve the patient better, especially in terms of aesthetics. Especially among age groups, responses to treatment come to the fore. The success rates in the treatment of nasal fractures in the elderly, adolescents and children differ. In addition, the classification and timing of any nasal injury greatly influences the approach to intervention and treatment outcomes.

This research that we have done here is to explain clinically how it can be treated better in the future and how it can be reflected more positively to the patient. Thus, better treatment models can be created as research and studies continue.

Contents

Introduction

Since the nose is prominently located in the center of the face, nasal bone fractures are the most common facial bone fractures and the third most common fracture in the body (1). Regardless of the different characteristics and types of such fractures among the traditional treatment options, simple manipulation and closed reduction have been accepted as the common treatment option for all of them. However, it is reported that the incidence of post-traumatic nasal deformities is still high, even with adequate closed reduction therapy, which does not satisfy some investigators. Therefore, among the treatment options, the methods that will ensure the integrity of the nose and allow the best healing of the fractures are still being discussed (2). Since most nasal bone reduction surgeries traditionally performed in the past were made with local anesthesia, simpler closed reduction was applied. Today, since the majority of nasal bone reduction surgeries are made under general anesthesia which is possible to perform more effective and efficient protocols. Another study, Burm and Oh used an endonasal incisional

approach known as indirect open reduction (IOR) to properly reduce the nasal bone with their technique. This method is presented as a more direct technique for nasal bone reduction. In addition, the endonasal incisional IOR technique has been shown to be a useful method for more accurate and optimum reduction of the nasal bone. Since there is no gold standard in nasal bone reduction, it is necessary to investigate the effectiveness of the techniques used, and to evaluate the postoperative results in terms of patient and physician satisfaction scores, the risk of nasal mucosal injury, and the cosmetic benefits of simultaneous dorsal augmentation rhinoplasty.

In terms of its anatomical formation, since the nasal bone is the most protruding bone structure in terms of the bones that make up the facial skeleton, it is more open and sensitive to impacts than other bones. Therefore, it is the most common facial bone fracture, ranking third among all bone fractures, as nasal fractures account for approximately 40% of all facial bone fractures. The reason for this is not only that it is the most protruding facial bone, but also that the structure of the bone is composed of thin

membranous bone and the fracture stress is low (3). Discussions on optimal treatment for nasal fractures continue. However, Hwang et al. stated that the noninvasive reduction technique can be used effectively in the treatment of nasal bone fractures (4). According to the results of many studies, it has been reported that the satisfaction level of patients after nasal bone fractures is lower when compared to other facial bones. In addition, it is emphasized that deficiencies such as the epidemiology of nasal bone fractures, which have a very high incidence, the development of the most appropriate surgical technique to be applied in the treatment, and the postoperative complications should be eliminated with systematic studies. Although there are many studies on the types of nasal bone fractures and related fractures based on the causes of injury and demographic data, more research and techniques are needed on the types or complications of fractures that will develop depending on their severity.

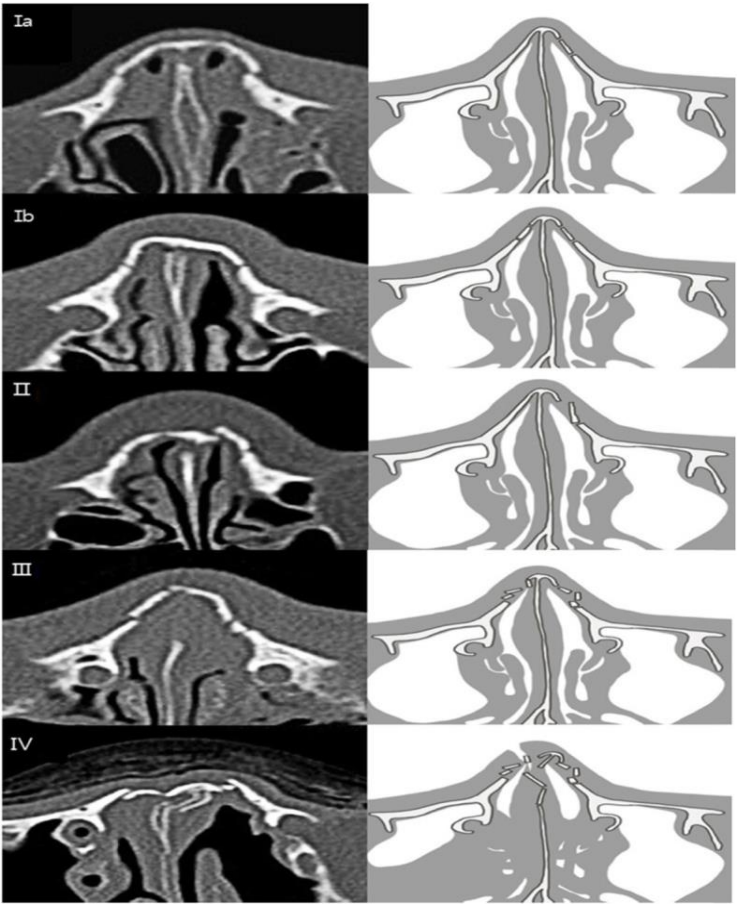

Figure 1. Types of nasal bone fractures. Ia Unilateral fracture, bone not displaced. Ib Bilateral fracture and bone not displaced. II Simple fracture but bone replacement. III Closed fracture but comminuted bone. IV, Open comminuted fracture or complex fracture*(5).

The symmetry and flexibility of the nose have been considered features of facial beauty and aesthetic appearance since ancient times. Thanks to their prominence in the facial skeleton, the nasal bones are exposed to more trauma and the incidence of fractures at this level is high. The etiology and epidemiology of nasal bone fractures vary considerably depending on the geographic region, living environment, and social, cultural, educational, and economic context of the population analyzed. Given these inconsistencies, periodic epidemiological studies are needed to implement the necessary tools to prevent this pathology, redistribute financial resources in healthcare, and ensure high-quality public health (6). The complexity of the cases depends on the etiology of the trauma, the kinetic energy of the injuring agent, the shape of the fracture lines, the involvement of the nasal septum, the number and trajectory of the associated fracture lines. and the presence of concomitant soft tissue injuries. Knowing the relationship between the fracture pattern and overlying soft tissue injuries is extremely important for clinical diagnosis, triage, and complementary imaging

examination, which should lead to an appropriate treatment approach. The management of nasal bone fractures varies depending on the fracture pattern, involvement of the nasal septum, age, or associated pathology of patients, including both closed nasal reduction (CNR) and open reduction and internal fixation (ORIF). with septoplasty. [7] Although nasal bone reduction may seem easy in general, postoperative complication rates (14-62%) and patient dissatisfaction (29%) are quite high. Secondary septoplasty or rhinoseptoplasty has an increased incidence in these cases, with reintervention rates reported between 14% and 50%.

Nasal fractures account for approximately 40 percent of injuries in facial trauma cases. The first treatment in such cases begins with the assessment of the severity of the injury, the correct understanding of the situation where the injury occurred, and the determination of the shape and functions of the face and nose before the injury occurred. After severe and severe injuries, nasal examination and palpation should be performed by evaluating airway patency, mucosal rupture and septal deformity, and

treatment should be started. Nose and surrounding structures; A comprehensive examination of the bony structures found in all orbits, including the mandible and cervical spine, should be performed. Fractures of the face or mandible should be looked at using imaging techniques. Patients with septal hematoma, malocclusion or extraocular movement disorders, and cerebrospinal fluid rhinorrhea require referral to a subspecialist. The first step of treatment consists of assessment, pain and infection management, minimal debridement and closed reduction by a trained specialist. If there is no indication for an emergency referral, close follow-up by a subspecialist within approximately three to five days of injury is recommended. Nasal injuries are relatively common in cases of facial trauma. Product fractures constitute almost half of bone fractures. Fight and sport injuries constitute the majority of fractures in adults. These are followed by falls and vehicle collisions. Plays are responsible for the sources of nasal fractures in children. From violent banter of children and women should be avoided and treated appropriately. Nasal fractures are mostly alone, but they can sometimes occur in conjunction with other facial

injuries. In addition, some patients are not diagnosed and treated because they do not seek medical care in many cases of nasal fractures (7). Although it is occasionally seen in family medicine, it is reported that the majority of patients with nasal fractures apply to emergency services. Old fractures that have been on for more than two days have a marked edema and require immediate referral for lateral branch evaluation.

Anatomy

Since the nose is a protruding formation at the very front of the face, it is easily exposed to trauma. It is surrounded by supporting cartilages in front of the nose and supporting bones from behind and above (Figure 1). The double nasal bones form a framework that supports the frontal to nasal process and the maxilla and cartilaginous skeleton. Although the majority of the nasal structure is cartilaginous, fractures are usually seen in the nasal bones as a result of injuries.

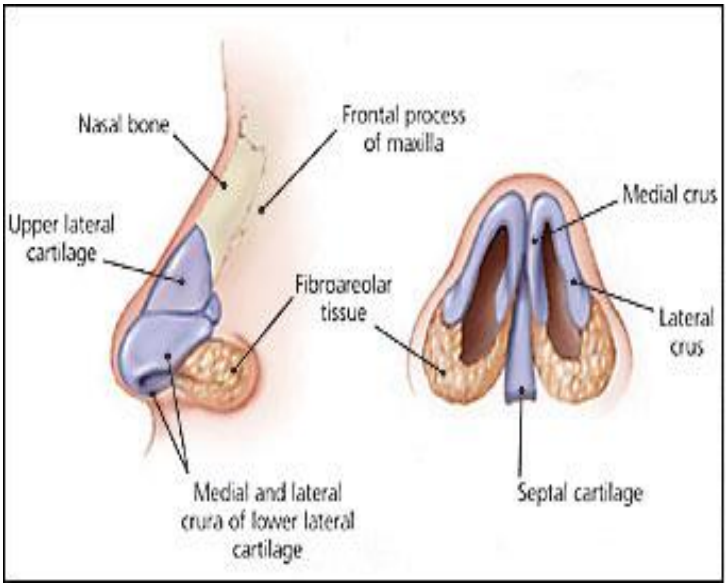

Figure 2. Anatomical relationship between nasal bones, cartilage and septum (7).

Above this bone and cartilage framework are softer and more flexible tissues responsible for the sensory and respiratory function of the nose, glands that secrete mucus, and muscles and nerves that control the opening and closing of the nostrils. Since the supporting nasal septum, which shows an anatomically natural narrowing, gradually becomes thinner, it becomes prone to fracture towards the tip of the nose and can be broken easily. Nose bleeding

occurs relatively easily in minor traumas, which is explained by the vascular network of the nose that provides nutrition. The vascular plexus, known as the Kiesselbach area, forms the region responsible for the vast majority of normal epistaxis. However, the source of bleeding that occurs in a nasal fracture is usually from other vascular networks in the nose. For example, excessive anterior hemorrhages most often originate from the anterior ethmoid artery (also a branch of the ophthalmic artery), while posterior hemorrhages may originate from a branch of the sphenopalatine artery. Arterial ligation may be necessary if bleeding cannot be controlled by clotting. Early consultation with an otolaryngologist is important in similar indications (8).

Understanding the mechanism that causes traumas helps the doctor to diagnose and determine the extent of the injury and to treat it effectively. It is helpful to know the object causing the injury, the direction it came from, and the force the nose exerts against it. For example, direct blows from the front may cause the broken bones to pass to the back by applying pressure to the nasal dorsum.

Similarly, lateral impacts can cause a depression on the impact side and usually on the opposite side of the nose, with orientation. Injuries based on pulling and torsion, although rare, can cause deterioration in cartilage. First of all, if there is bleeding from the injury, the patient should be asked questions about the onset time and extent of the bleeding. In addition, if any, previous nose surgeries and injuries should be asked, and basic nasal function and appearance evaluation should be performed. Finally, he or she may want to determine if he or she has been drinking alcohol as this type of trauma is often associated with alcohol use. This point is important because it can have implications from the choice of pain medication, the potential for repetitive injury, and the ability to assess mental status changes due to head injury.

Physical Examination

The majority of nasal fractures occur as a result of minor trauma such as a fist or elbow. However, when evaluating a patient with acute nasal injury, the physician should not focus solely on the apparently traumatized nose. This is especially important if there has been a serious traumatic

event after a motor vehicle accident or assault. Severe blows to the midface area may result in cervical spine injury. Therefore, the doctor should take appropriate precautions until cervical spine injury is ruled out. The point to be considered in the first evaluation is to check whether the patient's airway is open enough. Be sure to ventilate properly. Sometimes nasal injuries can be associated with trauma to the head and neck that can compromise the patency of the trachea. In addition, considering the region of the nose and its neighborhood, the doctor must consider the possibility of a nose-related facial or mandible fracture. Therefore, all bones that make up the face should be examined and every structure including the eye corners, zygomatic arches, malar elevations, lower jawbone and overlying teeth should be palpated for irregularity or tenderness. Cuts, swellings and deformities on the face should be noted, and the eye should be examined for symmetry and gaze mobility. If a fracture of the facial bones or mandible is suspected, evaluation with computed tomography, which is one of the radiological imaging, should be performed.

Generally, deformities in the nose become evident after a nasal fracture. However, deformity may not occur after every nasal fracture. It has been reported that nose bleeding may be the only clinical finding, although there is no significant nasal deformity in some nasal fractures. It is known that edema and ecchymosis are present in the structures around the nose and eyes, especially in the examinations performed a few hours after the injury. Palpation of nasal structures should be performed to identify and correct any crepitation, indentation, or irregularity in the nasal bone. Uncommon findings such as clear nasal discharge, mental status changes, subcutaneous emphysema, malocclusion, and leakage of cerebrospinal fluid appearing as extraocular movement require immediate specialist referral. In injuries, treatment by evaluating only the injured nose structure can sometimes give wrong results. For this reason, knowing the shape and appearance of the nose before the fracture of the patient with a broken nose is important in terms of understanding the severity of the nose injury. This is best accomplished by viewing a quality photograph of the patient taken before the nasal fracture. In cases where the photo is not

available, it can be used in a document with a photo, such as a driver's license or identity card. In addition, photographs of the broken nose can be taken by the doctor for legal purposes and to evaluate the success of the treatment. Especially in nasal injuries, one of the biggest limitations occurs if more than three hours have passed since the fracture and external and internal examination is difficult due to ecchymosis, edema and dried blood. If this is the case in a patient with an uncomplicated acute nasal fracture, it is appropriate to administer analgesics and release the patient with instructions to rest, apply a cold pack, and hold the head up. Fracture reduction can be safely planned within 3-5 days after swelling resolves with follow-up evaluation and management, when there is no clinical evidence to warrant early fracture. The reduction process takes 5-10 days without injury. It should be done between days and days before the nasal bones begin to fuse. However, it is very important that the septal hematomas of the patient with any nasal trauma are removed before discharge. In the nasal septum, unilateral or bilateral areas of white or purple fluctuation may appear slightly (Figure 2). Failure to identify and treat these

hematomas may result in saddle deformity of the septum requiring surgical repair.

Figure 3. Bilateral septal hematomas associated with nasal fracture.

Aspiration, anesthetic, and vasoconstrictive nasal sprays play a good illuminating role to facilitate a thorough internal examination. A nasal speculum and a headlight, as well as tools such as a fiberoptic endoscope, facilitate viewing. The first examination to be performed is removal

of large blood clots with warm saline, aspiration, and cotton-tipped applicators (2).

Adequate anesthesia and vasoconstriction should be achieved before a detailed internal examination is performed. Nasal sprays, cotton-tipped applicators, or locally applied topical agents are best for this situation. For a single and highly effective treatment, 5-10% cocaine solution, which is very difficult to obtain, has both vasoconstriction and analgesia properties. Alternative anesthetics include topical lidocaine, bupivacaine, and speries containing pontocaine. In addition, topical vasoconstrictors such as oxymetazoline and phenylephrine hydrochloride are useful adjuncts to control bleeding and reduce intranasal edema (3). Studies report that another form of administration as effective as cocaine is a 1:1 mixture of topical decongestants (oxymetazoline or phenylephrine) and 4% lidocaine. First, the physician should evaluate the airway patency during the internal examination and determine whether there is epistaxis or septal deformity. Moreover, the turbinates and inferior meatus should be viewed bilaterally and the septum should

be carefully examined for hematomas. Finally, the presence of a mucosal tear should be checked because it may indicate an underlying fracture. Plain radiography is rarely requested when an uncomplicated nasal fracture is suspected. Plain radiography can actually cause confusion in some clinical pictures. Because it has poor sensitivity and specificity (4). Plain radiography can mislead doctors, especially in cartilage fractures. As a result, normal suture lines may be misinterpreted as non-displaced fractures, as cartilage disruptions become difficult to identify. However, CT, one of the radiological imaging techniques, is used to evaluate facial and mandible fractures when signs such as CSF rhinorrhea, extraocular movement abnormalities, or malocclusion are seen. After providing airway patency, adequate air inflow and patient stability, the physician can turn his attention to a detailed evaluation of the nasal fracture. Treatment begins with the repair of bleeding-prone and sensitive external soft tissue injuries. If an open wound and foreign body contamination is visible, the open area is thoroughly washed with plenty of water. Some debridements may also be necessary in such injuries. Furthermore, when the wound area is large,

debridement becomes even more important because tissue will necessarily be needed to cover any exposed cartilage. Closed reduction of mild unilateral fractures is largely preferred for the reduction of acute nasal fractures in primary care. However, in rare cases, open reduction with surgical intervention is required. Although there is no treatment that determines how closed reduction of nasal fracture is performed in family medicine procedure, it is useful for family physicians to understand closed reduction treatment. Doctors who decide on open or closed reduction need absolute experience and training before trying these methods. The aim of closed reduction is to relieve the discomfort caused by the damage and to restore the cartilage and bone structures to their pre-injury positions that will optimize airway patency. Aesthetic results in closed reduction are often less than optimal and patients should be informed that nasal reconstruction may be necessary in the future. Pretreatment with anxiolytics and pain relievers should be considered when anxiety and pain associated with reduction occur. The Boies elevator offers greater precision than the forceps mentioned (Figure 3). When the Boies elevator is used correctly, it is inserted

deep into the nostril through the fracture in the nose, internally or externally. The knife on the elevator meets the doctor's thumb outside the nose. The misaligned broken parts are then returned to their original configuration or pushed into place. A reduction may be felt as the broken bone finds its place. The space formed by the blood accumulating between the septal cartilage and its perichondrium is called a septal hematoma. If not treated quickly, the blood that collects in these pockets easily becomes infected. Necrosis of this tissue underlying the cartilage support can cause chronic saddle nose deformity. When a septal hematoma is noticed or observed, it should be aspirated immediately or local anesthesia blood flow should be interrupted (Figure 4). A sterile drainage may be provided to this area to prevent re-accumulation of blood. But despite all these recommendations, there is conflicting evidence that using a drain is beneficial. A splint or suture can be applied to apply pressure and support to both sides of the septum, or a tampon can be used to the front of the nose (Figure 5). Incorrect interventions and management during treatment may result in disaster of septal hematoma. Therefore, the

doctor should start the treatment with the help of an otolaryngologist or plastic surgeon, if possible.

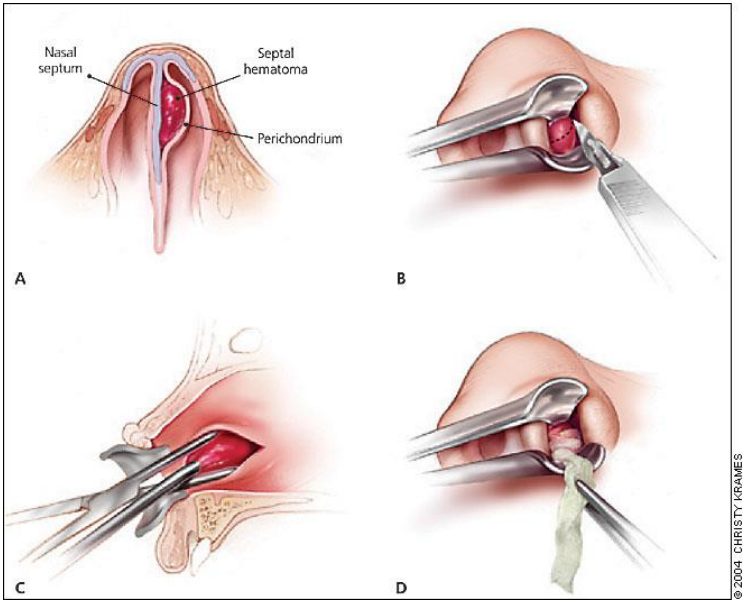

Figure 4. Septal hematoma. (A) Cross-section of septal hematoma showing blood accumulating in the space between the septum and perichondrium. In the treatment, first anesthesia followed by (B) incision with a hemostat, (C) drainage of the hematoma and (D) prevention of blood accumulation by placing sterile gauze (7).

The easiest and most common fracture of the facial bones is the nasal bone fracture. The primary treatment method in such fractures was closed reduction using general or local anesthesia. Both time and cost increase in closed reductions performed under general anesthesia. Especially hospital admission and hospitalization, pre-operative tests for general anesthesia and additional costs are in question. Comorbidities associated with the use of general anesthesia should also be considered. Boies elevators, Asch and Walsham forceps, and knife handles are routinely used in the reduction of nasal bone fractures. However, in closed reductions made with these instruments, corrections are insufficient, as they are usually performed blindly, new fractures may occur, mucosal damage and nosebleeds may occur. The best results in nasal bone fractures were obtained with digital reduction under general anesthesia (8). However, there are only a few studies on the efficacy of manual reductions with local anesthetics, and they do not have detailed reports on pain ratings and satisfaction with patient response. For this reason, there is a need for cohort studies that include the evaluation of postoperative functional and

aesthetic results and patient satisfaction of reductions performed under local anesthesia.

The nasal bone, which forms a protruding area in the center of the face, is one of the most frequently broken facial bones when exposed to trauma. Effective treatments for nasal bone fractures include surgical closed reduction, open reduction and rhinoplasty, among which closed reduction is the standard treatment as it allows for a simple and effective reduction that is both safe. However, in some cases it is difficult to completely correct nasal bone fractures using closed reduction. Fractures with septal cartilage damage often lead to postoperative secondary deformities. For this reason, patients often do not look favorably on treatment with this surgical method. Previous studies investigating patient satisfaction after closed reduction of nasal bone fractures have addressed various approaches to increase satisfaction; However, in these studies, satisfaction with aesthetic and functional competence could not be differentiated and their long-term (> 6 months) satisfaction could not be evaluated.

Various criteria have been established to classify the modification according to the fracture type, known as the Murray classification (9, 10): These are Am; septal fracture or unilateral fracture without significant septal deviation; Septal fracture or unilateral fracture causing severe septal deviation; Bm, septal fracture or bilateral fracture without significant septal deviation; BS, septal fracture or bilateral fracture with severe septal deviation; C, comminuted fracture.

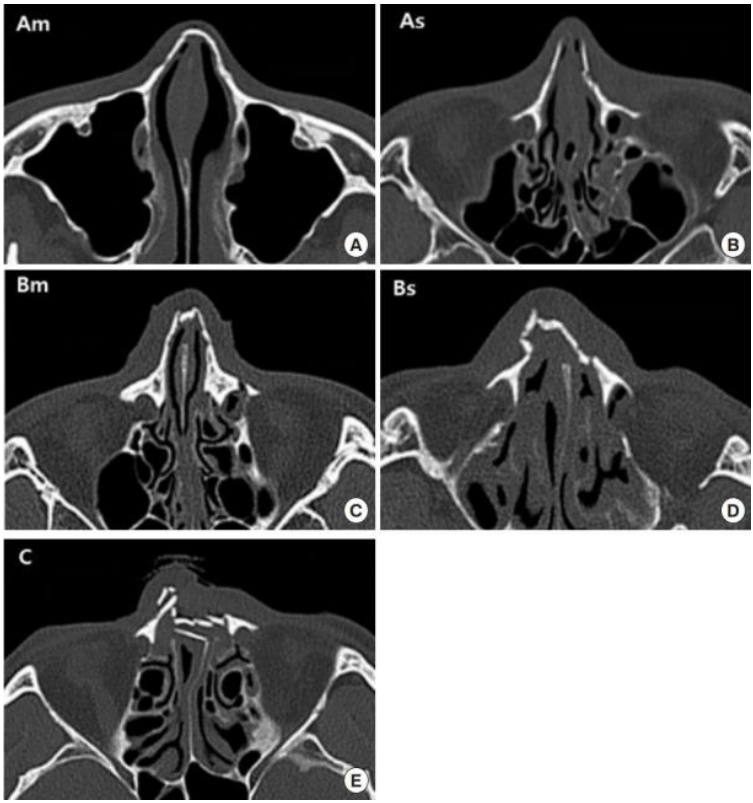

Figure 5. These are Am; septal fracture or unilateral fracture without significant septal deviation; Septal fracture or unilateral fracture causing severe septal deviation; Bm, septal fracture or bilateral fracture without significant septal deviation; BS, septal fracture or bilateral fracture with severe septal deviation; C, comminuted fracture.

Evaluation methods

Nasal bone fracture classification used by Stranc and Robertson (9) to characterize the fracture type:

Type I (FI) due to frontal impacts: lower end of nasal bones only.

Type II (FII) due to frontal impact: proximal of the nasal bone and anterior process of the maxilla.

Type I (LI) due to side impacts: collapse and unilateral displacement of the nasal bone into the nasal cavity.

Type II (LII) side-effect-related: moderate inward displacement of the ipsilateral nasal bone and outward protrusion of the contralateral nasal bone.

Segmented fracture (C): Multiple segmental fracture with telescopic and depression.

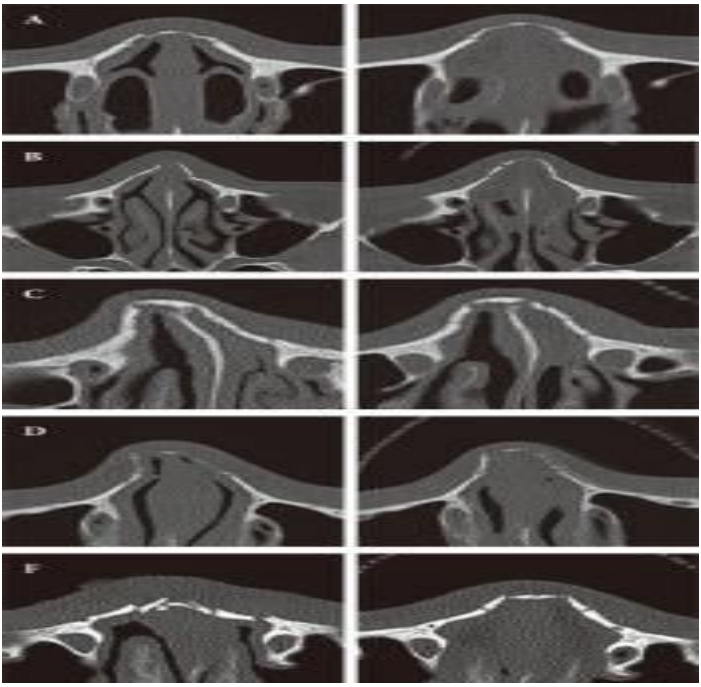

Figure 6. Preoperative and post reduction CT images of five different types of nasal bone fractures. (A) Frontal impact type I (FI) preoperative and post reduction CT. (B) Frontal impact type II (FII) preoperative and post reduction CT. (C) Type I (LI) preoperative and post-reduction CT due to side impact. (D) Side impact type II (LII) preoperative and post reduction CT. (E) Preoperative and post-reduction CT images of the comminuted fracture group (C) (10).

All most common causes of injuries to the facial bones are blunt trauma to the nose area, usually caused by traffic accidents, sports injuries or physical fights. The natural projection and fragility of distal structures make them prone to injury. Nasal bones and cartilages, structures forming the center of the face, provide both aesthetic and structural support to the respiratory tract; therefore, nasal deformities and airway compliances gain more importance. Proper assessment and management is required to prevent damage. There are many unresolved problems in classical approaches. No matter how skilled the nasal surgeon is, if there is a bleeding injury, most nasal fractures are not immediately identified due to edema. In addition for septal deformities and collapsed internal nasal structures, high recurrence rates and the need for reoperational rhinoplasty are common, although closed treatment may be sufficient to achieve temporary repositioning of the structures. It has been reported that nasal deformities requiring reoperation after trauma are up to 50%. The current consensus is that fragmented nasal bones and secondary collapse of the septum are caused by scars at the wound site failing to provide adequate

structural support against contractile forces. Nose fractures now require an individual approach to these injuries, as there is no satisfactory common procedure or technique for all patients. The situation is slightly different in pediatrics, especially in children who have not completed the age of 5, bone and cartilage injuries are less common. Possible reasons for this include not being exposed to too much facial trauma. However, the incidence of fractures increases with age. The childhood period with the highest incidence of nasal fractures is seen in boys between the ages of 16-20 (11). As in adults, fractures in children are often caused by motor vehicle or sports-related trauma, but falls and physical child abuse are other causes. In all patients, regardless of age, conservative selection is necessary to distinguish patients requiring acute treatment from patients requiring delayed treatment. With the developed algorithm, patients with prominent septal and nasal deviation present with nasal airway obstruction and require acute treatment with open reduction (Figure 1). In patients in whom primary reduction is not performed or possible, delayed reduction may be sufficient once the edema has subsided. Treatment

requires a traditional approach for complicated rhinoplasty such as correction of airway obstruction, septal deviation and malposition. Scattered grafts may also be required for more precise and smooth trimming. As a result, the goal of treatment should be an aesthetic and functional repair of the nasal passages with any reduction.

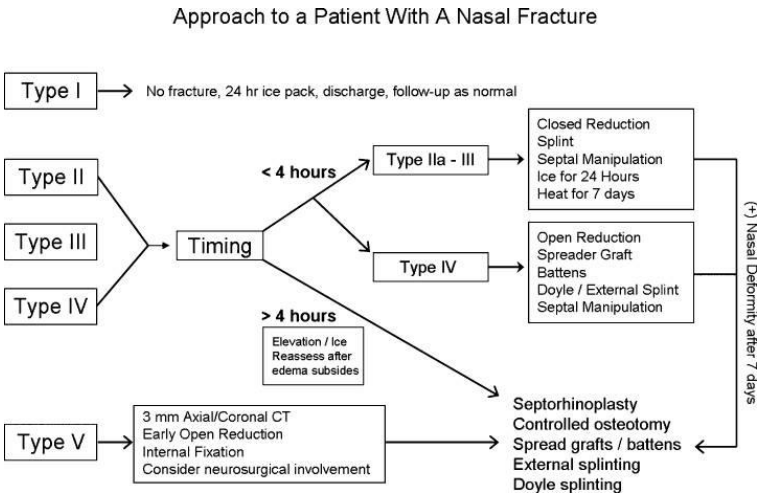

Figure 7. The ideal management of nasal trauma, which differs according to the type of injury and timing of admission (12).

Detailed anatomical knowledge of the nose (including bone, cartilage, septal and vascular support) is required to understand the pathophysiology of injury, the resulting deformity, and appropriate treatment. Nasal bone components consist of maxilla, vomer, and ethmoid below, and frontal and nasal bones above. Nasal fractures occur mostly in the distal parts and these parts are thinner and wider (13). Cases associated with proximal nasal bones, such as the anterior portion of the cribriform plate, constitute more complicated injuries and have pathology that requires extra attention. Fractures in these areas are referred to as nasoorbitoethmoid fractures. Nasal cartilages are located in pairs forming the upper and lower lateral and midline septum. Bilateral upper lateral cartilage holds the septal cartilage in its midline position (14). The lower lateral cartilages contribute to the aesthetic contour of the nose. Cartilage fractures usually occur infrequently because damaging the distal cartilage, which can be comfortable to deform, requires much more force than damaging the nasal bones and septum.

The cartilage forming the nasal septum is mostly quadrangular in shape. The posterior septal cartilage is thicker and acts as a protective home, as a support wall that supports the upper roof of the nose and the ridge of the nose. However, the septal cartilage begins to thin as it goes caudally (15). In children, the septum is further developed with its contribution to the face as a major growth center. The growth of the nasal septum continues until the age of 12-13, and septal traumas affect the development of the midface. In all age groups, the midline structure is supported by the medial legs of the bilateral cartilage. The lower support is provided by the vomer, the upper and posterior support is provided by the ethmoid bone plate.

Nasal blood flow is provided by branches of the internal and external carotid arteries; The majority of the arteries arise from the infraorbital and sphenopalatine branches of the maxillary artery. Later, the branch of the facial artery feeding the upper lip provides additional vascularity to the region. The inferior and medial concha are supplied with blood by the ethmoidal branches of the internal carotid artery and the branches arising from the external carotid

artery. In nasal injuries, epistaxis indicates mucosal damage, usually anteriorly, the Kiesselbach's plexus in the anteroinferior septum appears to be the cause of the hemorrhage. It is known that both sphenopalatine and anterior ethmoidal arteries cause posterior bleeding. Anterior epistaxis can be effectively stopped by direct external pressure. Posterior epistaxis can often be cut spontaneously. Although rare, posterior bleeding may require urgent intervention as serious bleeding (balloon catheterization, interventional embolization). Finally, the innervation of the muscles in the nasal region is provided by the trigeminal nerve. Both the ophthalmic and maxillary branches control the neural excitation of the nasal muscles. In the infratrochlear nerve, it provides sensation to the skin covering the upper and lateral walls of the nasal dorsum, and in the anterior ethmoidal branch, it stimulates the lower and tip of the dorsum.

Clinical evaluation is very important in the diagnosis of nasal trauma. A detailed patient history and examination are important to determine the appropriate patient selection and timing of treatment. The extent of the injury

mechanism, the type of wound (open or closed), the time elapsed since the injury, and the age of the casualty are very important in distinguishing patients who need acute reduction. Bone and facial deformities caused by acute trauma should be differentiated from chronic or pre-existing defects.

The actual mechanism of facial injuries such as nasal fractures should be clearly identified (accident, fall, or armed/unarmed fight). Different formation mechanisms also cause different types of trauma by mimicking the direction and speed of the impact. In fights with nasal trauma after the attack, it is characteristically exposed to low-energy force transmission from the side of the nose. In such common nasal injuries, ipsilateral internal fracture of the bone, an external fracture on the contralateral side, and typical septal deformation accompanying these fractures can be seen. Frontal impact is a common form of injury in motor vehicle and gun injuries. Because these are high-energy movements, more nasal bone fragmentation and septal deformation are typically seen. Crushes are also common injuries, especially as a result of blows from the

front. The timing of the injury is very important in terms of treatment. Because patients can apply sometimes hours or weeks after injury, and such delays change the way and course of optimal management. The first hours after the injury are important because the complete visualization of the newly formed deformities before edema occurs and the nasal cavity is swollen and closed, affects the efficiency of the treatment. If the deformities are clearly identified, a closed reduction is the ideal choice in such cases. However, there are very few patients coming in this profile. The swelling obscures the physical details of the nose and makes accurate diagnosis limited. This causes the reduction to be delayed 3-5 times, and then evaluation is made when the swelling subsides (2). In conclusion, previous nasal trauma or procedures performed should be taken into account, if the patient has a history. It is important to compare the post-traumatic nose with a pre-traumatic photograph (if there is an acute situation, an ID photograph is also used). In addition, if the patient has a history of breathing difficulties, sleep apnea, nasal discharge or congestion, and snoring should be addressed in a more detailed historical study. Moreover, the frequent

use of allergy medications or inhalers available over the counter in pharmacies should also be taken into account. As a result, it should be kept in mind that minimizing the damage, deformity and especially airway obstruction in the patient is the best effect of the surgical treatment only when the previous deformities are considered. Physical examinations should be a joint examination with both internal and external components. External examination should focus more on esthetic nose appearance, malposition and laceration, and soft tissue injuries such as bleeding or edema (Fig. 2). For this reason, nasal palpation plays a critical role in external examination. If there are physical findings such as crepitation in the palpable nose, nasal shortening, hypersensitivity, difficulty in walking, depression or enlargement of the nasal base, there is a high probability of nasal fracture. However, any injury that does not bleed to a certain degree is unlikely to have a serious fracture. Nasoorbital ethmoid fractures, especially associated with high-energy frontal or subnasal injuries, can be excluded with intercantal measurements. In addition, in case of CSF leakage, rhinorrhea can be evaluated by testing glucose or β-transferrin levels. If CSF

leakage is suspected, neurosurgical consultation may be necessary. It is recommended that patients keep their head elevated and avoid lying on their back in order to accelerate recovery. If the leak persists for more than 2 weeks, try to prevent the fluid leak with lumbar drainage.

Figure 8. The most common findings in nasal bone fractures are loss of nasal dorsum projection, loss of aesthetic lines, and periorbital ecchymosis (12).

For internal examination of the nose, patients are given a decogestant spray or topical vasoconstrictive medication. The endoscope and Frazier tip aspiration, nasal speculum,

head lamp, and cotton-tipped applicators are then used to facilitate internal imaging with minimal preparation and equipment. Oxymetazoline with 4% lidocaine or phenylephrine hydrochloride, which are commonly used as local anesthetic agents, are preferred. The way of examination is to keep the patient in a sitting position and if the endoscope is used, it is pushed under the inferior turbinate to get a clear image. Attention should be paid to the ethmoid plate, inferior meatus, turbinates, and septum. Because the connection between them is important. Septal mucosa is ruptured or examined for rupture. Treatment should be started immediately to minimize septal hematoma, pressure-induced necrosis, and cartilage damage. Hematomas can be treated by drainage, followed by detailed treatment with local and systemic antibiotics. If hematomas are small in diameter, they can be aspirated with close monitoring. The complexity of the nasal cavity and the difficulty of examining it make the examination more difficult in pediatric patients. Although the probability of fracture is lower in children, septal injuries are common in this population (16). Septal necroses that cannot be noticed in children may affect the nasal growth

centers and may cause a nasal structure that is prone to deformities in the future. Therefore, it is important to pay attention to nasal traumas in children.

Since most of the diagnoses are clinical, imaging is rarely necessary and it is one of the costly methods in nasal fractures (17). However, computed tomography scanning, intracranial injuries of a NOE fracture and other associated periorbital fractures, and other associated periorbital fractures should be utilized when suspected to avoid serious complications. CT is particularly useful to identify and correct the septal deviation of the posterior ethmoid.

Nasal Fractures and Preoperative Management

There are many parameters for the health management of a nasal trauma. The first is the age of the patient, the second is the time after injury, the third is the need for acute or delayed reduction, the fourth is the type of anesthesia, and the fifth is the open or closed reduction approach. First of all, the fracture must be carefully diagnosed and classified before attempting any treatment.

Age-Specific Concerns

Nose surgery may bring additional difficulties in children and elderly people. In elderly patients with brittle and short nasal bones, conservative reduction and osteotomy can be performed with the use of grafts. However, the patient's post-operative nose image should be explained in the last realistic way by counseling. Considering the age-related changes in anatomical structures, facial growth centers and age-related wound healing, rhinoplasty in children should be approached with special care (18). It may be unwise to treat children as “little adults” and to use safe and effective adult surgical interventions for children. If septal surgery is to be performed in children, the best timing is between the ages of 13-14, when growth in this area is complete. If the shape, orientation and placement of the septum is incorrect and will affect normal bone growth without intervention, surgery can be performed with caution. Generally, in simple rhinoplasty, the treatment is completed by careful reduction of the broken segments with postoperative nasal packing. Very young

children should be carefully monitored for a tendency to compulsive nasal breathing.

Considerations for Anesthesia

There are many studies on local and general anesthesia in nasal fractures. The use of local anesthesia and general anesthesia in the reduction of nasal fractures is compared. Priority concerns regarding patient safety should be evaluated in collaboration with the patient prior to surgery. Other considerations include what the cost will be, differences in outcomes, and the patient's overall health. Reduction of pediatric patients under anesthesia presents additional challenges and typically requires reduction under general anaesthesia. However, in most adults with type IIa to type IV fractures, a combination of topical and infiltrative local anesthetics can be administered if the assessment is accurate and timed. Infiltrative anesthesia can be applied externally in the nasal dorsum and is better tolerated when compared with bilateral internal blocks (19).

Management of Topical and Infitrative Anesthesia

Local anesthesia is divided into two as topical and infiltrative according to the place and form of use. Generally, phenylephrine hydrochloride or oxymetazoline can be used with 4% lidocaine and applied with a tampon. If tampons are to be applied, the most preferred method is to apply three tampons to each nostril for 8-10 minutes. Specific focus areas should be particularly well defined. Packing should be performed near the ethmoid nerve and artery (along the dorsal septum), along the middle turbinate (proximal to the pterygopalatine ganglion), and along the base of the nose (adjacent to the nasopalatine nerve and sphenopalatine artery). Epinephrine may be preferred for internal and external infiltrative anesthesia. The volume of infiltrative anesthesia should be kept to a minimum in order not to disrupt the nasal anatomy and prevent the planned reduction. Infiltration into the septal submucosa should be provided both on the lower surfaces of the nasal bones and bilaterally. If necessary, infiltrative blocks can be applied to the dorsonasal and infraorbital nerves.

Closed Reduction

Although there are exceptions, closed reduction is usually performed for simple nasal fractures without bone fragmentation (Figure 9). The basic principle in this technique is to create a force opposite to the trauma-inducing vector in order to achieve the best possible fracture reduction. After anesthesia, it is necessary to pay attention to the bony nose pyramid structure. It is necessary to prevent this area from being damaged by excessive force. Bones can be manually repositioned with tools such as the Goldman lifter. It is important to note the use of this technique on the cribriform plate if injury is suspected. The Goldman lever provides bilateral manipulation of the external nasal bones, allowing upward/outward force to be applied.

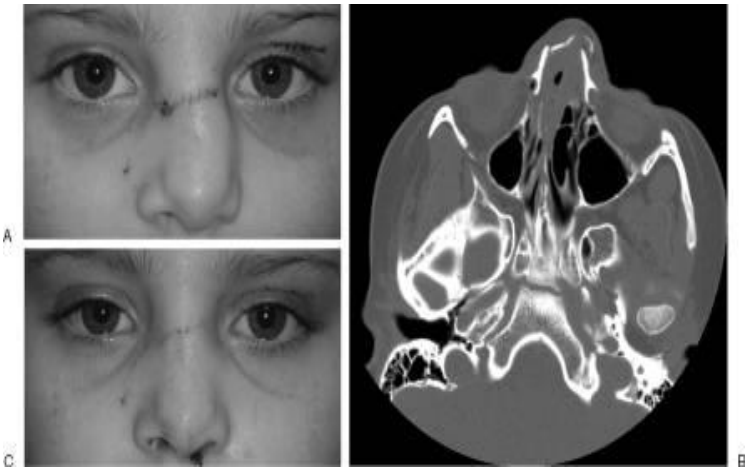

Figure 9. A young female patient with a blow to the back of the nose. (A) The patient's nasal dorsal enlargement and flattening occurred. (B) CT imaging findings showed severely fragmented and collapsed nasal bone fracture. Nasal bone fractures were treated with closed reduction. (C) Postoperative view, nasal bone position, dorsal projection and width.

Nasal bone deformities are particularly important to the nasal septum as they will typically recur if septal injuries are overlooked. Straightening of the septum is accomplished by simultaneous upward pull of the nasal pyramid with blunt pressure in the opposite direction of

deviation using the Goldman lever. The Boies lift can be used as an alternative for blunt repositioning of the septa. Consequently, the base of the septa should be repositioned as much as possible over the groove of the vomer. Effective results can be obtained if closed reduction is applied on the appropriate patient. Therefore, the role of a properly selected patient is great. However, in some cases, in the closed approach, especially in some areas, it should be applied more carefully after surgery. In partial nasal fractures, osteotomy may be required for mobility and appropriate reduction. Again, the patient should be interviewed and informed before the operation. The patient's expectation of perfectionist results may not always be met, and it should be explained that the primary goal is to correct deformity and functional impairment. In addition, since the rate of recurrence and surgery for closed reductions varies between 9-17%, patients should be prepared for the possibility of needing open septorhinoplasty in the future.

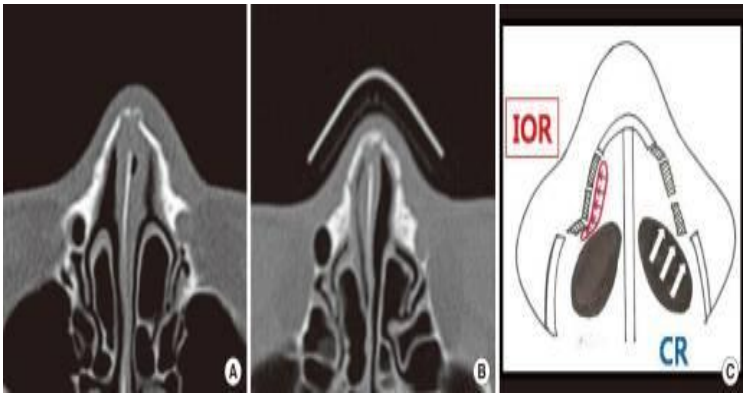

Figure 10. Pressure-induced lateral nasal bone fracture. Preoperative view of nasal bone fracture, CT scan image. (B) Postoperative view of nasal bone fracture. CT scan image of nasal bone fracture. (C) Comparison of closed reduction and open reduction (IOR) for reduction of compression fractured lateral nasal bone fracture. Cross-sectional view showing the superiority of open reduction (20).

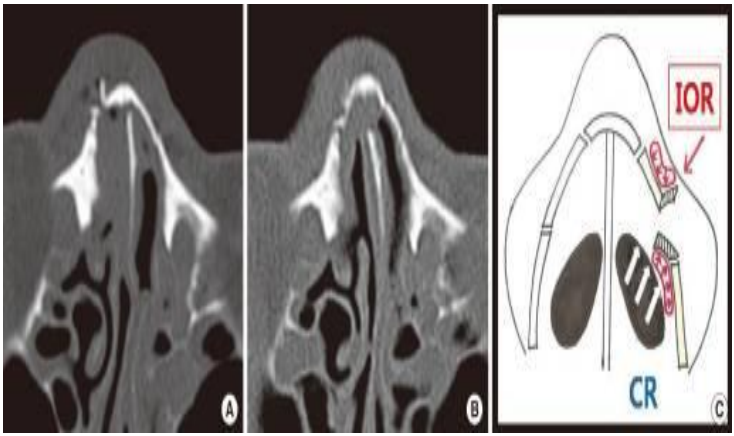

Figure 11. A case with local fracture of the right lateral wall. (A) Preoperative view of the right lateral wall local fracture of the nose. CT scan image. (B) Postoperative view of the right lateral wall local fracture of the nose. CT scan image. (C) Nasal bone focal sprain fracture comparing closed reduction and open reduction. Cross-sectional illustration showing the superiority of open reduction (20).

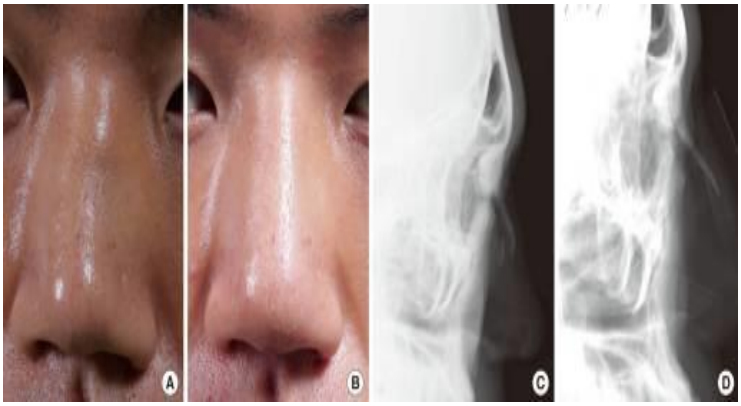

Figure 12. Simultaneous dorsal augmentation rhinoplasty (A) The patient is a 25-year-old male, who applied because his nasal dorsum fell due to a nasal bone fracture. Due to nasal bone fracture, indirect open reduction (IOR) and dorsal augmentation rhinoplasty with simultaneous Alloderm graft were performed. Operation image without postoperative complications and showing satisfaction after 1-year follow-up (B). Image 1 year after surgery. (C). X-ray image taken before surgery. (D) X-ray image taken after surgery (20).

In general, closed reduction is widely used as a treatment method in nasal fractures. This is a relatively simple and easy method to perform under local or general anesthesia.

However, many authors reported that numerous results did not meet expectations. Rohrich and Adams report that post-traumatic nasal deformity requiring subsequent rhinoplasty or septorhinoplasty remains in 50% of cases (21). The thin nasal bone, which has a three-dimensional structure as a feature of the nose structure, tends to break into many parts when the nasal bone is broken, making it difficult to restore each part to its original three-dimensional structure. using simple closed reduction. In 1966, Fry (22) reported that stress clamping on cartilage after traumatic injury makes nasal deformity more severe. Therefore, recollapse of the fractured segment and nasal deformity are not uncommon after reduction of the nasal bone. In particular, there is a limit to CR in cases of focally displaced fragment fracture or midline end fracture. In addition, attempts to overuse the CR may result in nasal bleeding due to nasal mucous membrane damage or mucosal synechiae that may occur after wound healing (23). After IOR of the broken bone sections, the surgeons gently CR for the finishing touch. Since there is no need for excessive force in these reduction processes, the risk of nose bleeding caused by damage to the nasal mucous

membrane is almost non-existent when compared to CR alone. Generally, the appropriate time for reduction of a nasal bone fracture is 7 days after the trauma. Since callus formation and bone fusion become difficult after this period, it is difficult to reduce the displaced fracture segments after this period. On the other hand, the IOR directly powers the broken bone itself; therefore, it is possible to return the fracture to its original location even after 1 or 2 weeks (24). To keep the reduced nasal bone in its proper position, the authors applied intranasal petrolatum and Multicel sponge padding or K-wire fixation to preserve the restored fragments. More detailed studies are needed to compare the effects of the two detection methods.

In different studies, intranasal petrolatum and Multicel sponge filling or K-wire fixation were applied with restored fragments to keep the reduced nasal bone in the proper position after fracture. In order to determine the pros and cons of these methods, their effects should be compared and more detailed studies should be done. It is possible to see the advantages of IOR surgery unlike other

methods. The biggest advantage is that both fracture reduction and aesthetic rhinoplasty can be performed from the same incision in patients who want to enlarge the lower back of the nose. Since there is irregularity and instability of the fractured side with rhinoplasty in dorsal augmentation, Alloderm, Surederm or more flexible cartilage grafts taken from the nasal septum are used instead of rigid silastic implants. Since the clinical picture in nasal bone fractures is an acute trauma injury, detailed and sensitive rhinoplasty becomes difficult at the same time. Generally, other rhinoplasty interventions such as nasal tip aesthetics are avoided in studies against the risk of infection and inflammation. Preoperative procedures are determined and depending on the severity of the nasal bone fracture, simultaneous augmentation rhinoplasty can be performed in patients with back depression. In patients with comminuted nasal bone fractures (with septal fractures or severe septal deviations), simultaneous dorsal augmentation rhinoplasty is removed in the procedure, even if they have requests. To avoid graft deflection after graft-reinforced insertions, extensive examination should not be made for growth of graft material. Also, graft

placements are not made on the nasal bone, but in subcutaneous pockets with better circulation.

The nose, which is located most prominently in the center of the face and the face, is the most important part that allows us to distinguish individuals from each other (25). Due to its shape and structure, it is highly susceptible to injury. In addition, fractures or deformations in the cartilage or bone of the nose affect the general aesthetics of the face, even if they are very small. However, nasal bone fractures are among the most common facial fractures. Changing lifestyles and increasing traffic accidents have increased the incidence of nasal fractures, so epidemiological studies are needed to guide effective treatment modalities (26). The incidence of nasal bone fractures by gender varies according to studies. Marco et al. (27) It is seen four times more in men than in women, Turvey et al. (28) three times more in men, and Nishioka et al. (29) showed that it was seen slightly more than twice in men. The results of all these studies indicate that nasal fractures are more common in men than in women. Another study reported that the incidence of fractures in

men was approximately seven times higher. In the fracture incidence studies conducted according to age groups; Hwang et al. (4) observed that the most common age of nasal bone fractures was 20 (approximately 32%), during adolescence (22%), in their 30s (20%) and 40s (16%). Also, in another study, Ah et al. reported that nasal bone fractures were most common in the 20s, and the lowest rate was after the 40s.

Although most nasal bone fractures can be treated with closed reduction, there are differing opinions depending on the physician when the appropriate time for reduction. Rohrich et al. (2) stated that reduction should be done within 7 days following the fracture, and within 10 days in adults. However, Harrison claims that the appropriate time for reduction is 3-7 days for children and 5-10 days for adults. Goode and Spooner (30) suggested that the appropriate time for reduction is 2-3 days after the fracture, when edema disappears. Han claims that reduction in nasal bone fractures with multiple fracture segments after 2 weeks may work best. In this study, reduction was achieved within a mean of 7.7 days (range,

0-33 days) after the fracture. Reduction was not performed for small fractures that did not affect the appearance of the face. In these cases, a precise assessment of facial appearance is required. Therefore, it is advantageous to decide whether to perform a surgical procedure after the edema has dissipated after injury. Regarding complications after reduction of nasal bone fractures, Hwang et al. (31) reported that 10.4% of the patients had nasal deformity. In addition, 10.0% had septal deviation, 10.5% had nasal obstruction, 3.1% had epiphora, 3.1% had diplopia, and 37.7% of patients had olfactory disturbances. In this study, nasal obstruction was seen in 11 (6.1%) patients, postoperative deformity in 20 (11.2%) patients, and olfactory impairment in 2 (1.1%) patients. Anatomically, olfactory epithelial cells are distributed in the upper part of the nasal cavity and bilaterally between the septum and the medial part of the superior nasal concha (32). In addition, the olfactory epithelium can be found superiorly on the middle turbinate and inferiorly under the cribriform plate. The high rates of olfactory disorders after reduction of nasal bone fractures are due to the fact that olfactory epithelial cells located on the superior nasal

concha or superior nasal concha may be damaged during a procedure (33). In this study, olfactory impairment was observed in only 2 patients. Therefore, it can be concluded that the closed reduction is performed with precision.

Reduction

The key role in nose surgeries is the inability of closed reduction to use adequate treatment in certain nasal injuries. Open reduction has many advantages in severe segmented fractures, septal injuries and soft tissue injuries in the important support mechanisms of the nose, so it should be handled with full exposure (Fig. 1) (4). Further intervention is essential, particularly in cases of nasal tip distortion, to visualize the position and shape of the displaced structures and to precisely determine the region to relocate. In addition, transfixation or hemitransfixation incision in the membranous septum largely allows caudal, inferior, and posterior imaging of the septum and accelerates healing (34). Surgical intervention should be performed early to avoid significant disruption of the injured area before secondary healing and remodeling occurs. However, if appropriate post-injury care is taken

after the procedures applied, serious reduction of edema can be achieved after 5-7 days.

Consideratıons For Septal Repair

In the anterior maxilla, there are multiple options to elevate the perichondrium and periosteum at the junction of the septum. According to denier studies, a single mucopericoperiosteal tunnel brought from the back to the front and from the bottom is recommended. This approach reduces the risk of perforation and provides excellent visibility of the vomer and base of the septum. Careful dissection of the extramucosal tissue in the dorsal septum preserves the supporting skeleton and allows separation of the inner and outer nose. In case of perforation, mobilization and closure are recommended. In addition, the possibility of septum deformation should not be forgotten without permanent and appropriate fixation.

Quadrangular Cartilage

Manipulation of the quadrilateral cartilage is necessary to reconstruct the nasal midline and permanently position the septum. A minimum of 10-15 mm wide dorsal and caudal

cartilage support should always be provided. Septal alignment of the midline is supported by removing the lower horizontal portion of the septum. If necessary, the vertical plate of the ethmoid bone is removed to maintain attachment to the underlying mucoperichondrium.

Bony septum

Bony septal deformities contribute to airway obstruction and mechanical midline malposition; however, malposition of the bony septum is an indication of green rod fracture or resection to avoid airway obstruction, as little nasal support is obtained from this structure. A 2 mm osteotome can be used to reposition the bony septum in the midline, but care should be taken for spurs or broken bones as these may play a role in the obstruction. If malposition of the premaxillary ridge or nasal spine is evident, resection of the 3 to 4 mm lower septal cartilage strip may allow repositioning of the midline. Fixation of the caudal septum to the premaxillary periosteum can be accomplished with 4-0 nylon sutures.

Caudal septum

Weakening or destruction of the caudal septum can result in loss of nasal tip care, and subsequent repair of this structure represents a difficult surgical challenge. The structural support can be reconstructed with 4-0 clear nylon or autogenous cartilage secured in place with PDS (Ethicon Inc., Somerville, NJ) suture.

Dorsal septum

The cartilaginous dorsum should be approached after all other septal abnormalities have been addressed. If the septum remains crooked despite caudal, inferior, and posterior cartilage reconstruction, a dorsal cartilage incision may be attempted. Vertical incisions in intact dorsal cartilage should be made within 2 to 3 mm of total transection. If continuity is interrupted, care should be taken not to displace the mobilized septal components posteriorly. It is very important to reconstruct the support with an invasive graft to keep distortion to a minimum. Prior to a successful dorsal septum dissection (1) trans-septal mattress sutures under the dorsum buttress of cartilage or bone to prevent posterior displacement, (2)

stabilization of the caudal cartilage support and septum by internal splinting, and (3) reposition of the skeleton with lateral osteotomies. Finally, if a humpback resection is not used, the upper lateral cartilages must be released from the septum via submucosal tunnels for exposure and access.

Removal of the hump

After septal repair and fixation, hump removal should be attempted and can be simplified using preformed submucosal tunnels. Any cartilage asymmetry should be evaluated visually as well as digitally with a wet gloved finger. Any resection should be approached conservatively. A chisel or rasp can be used to carefully remove the cartilage gradually. Extra care should be taken with a curved nose due to the frequent occurrence of skeletal asymmetry. Cases involving wide nasal bridges are at risk of developing an open roof deformity. This can be avoided by using osteotomies or onlay cartilage grafts.

Osteotomies

Nasal osteotomies can be performed to shape the dorsum of the nasal bone and the bony dome, but must be used in

addition to nasal bracing repair for septal alignment to be successful. Without proper and proper positioning of the dorsal septum, the lateral cartilage deviation of the upper back will remain bilaterally displaced. When repair and mobilization with osteotomy are performed alone, usually only temporary correction of the deviation is achieved and results in recurrence (16). Asymmetry and irregularity in the natural bone shape of the nasal bones may present unexpected intraoperative difficulties. In addition, there may be serious curvatures in both the nasal bones and the maxilla. In the disturbingly crooked nose, paramedian or double osteotomies can help reposition broken bones. If the fragments in the nasal bone are very small and crumbly, grafts larger than the skull cartilages can be used to prevent the bone from collapsing.

Patients should be informed preoperatively that restoration of pre-traumatic nasal appearance may not be a realistic outcome. Follow-up should be extended to 6 to 12 weeks postoperatively, during which the structural integrity of the nose should be evaluated. If mid-dome nasal collapse has occurred, the surgeon should understand that support

has been lost and future septorhinoplasty may be required. In these cases, a large, cartilaginous diffuse graft may make sense. Large cadaveric or autologous rib-shaped grafts placed medial to the nasal bones and just lateral to the septum can be used to sustain comminuted nasal fracture reduction. Similarly, if the end support is lost, the rib graft can act as a stronger columellar suture graft to heal and maintain protrusion. Thinner cartilage grafts can be used to fix a deviated septum after appropriate release and can be secured with multiple sutures. The septum stem can be harvested without dire consequences in adults for use as grafting material, whereas auricular cartilage is generally unsuitable in this area due to its natural curve. Centered at the point of maximum weakness and concavity of the alar sidewall, leta grafts can be used to straighten the septum as opposed to simple reduction and dissection. Bilateral slat grafts are becoming more common in contemporary repair and may be valuable for maintaining nasal straightness. however, ear cartilage is often not suitable in this region due to its natural curve. Centered at the point of maximum weakness and concavity of the alar sidewall, leta grafts can be used to

straighten the septum as opposed to simple reduction and dissection. Bilateral slat grafts are becoming more common in contemporary repair and may be valuable for maintaining nasal straightness. however, ear cartilage is often not suitable in this region due to its natural curve. Centered at the point of maximum weakness and concavity of the alar sidewall, leta grafts can be used to straighten the septum as opposed to simple reduction and dissection. Bilateral slat grafts are becoming more common in contemporary repair and may be valuable for maintaining nasal straightness.

Conclusion

Developing technology has enabled the development of techniques in the treatment of rhinoplasty and nasal fractures, as in many other areas. Patients with nasal fractures can now access treatments with better results. Although there are simple procedures, some obstacles are inevitable. Responses to treatment, especially among age groups, come to the fore. As the elderly, adolescents and children, the success rates in the treatment of nasal fractures differ. In addition, the classification and timing

of any nasal injury greatly influence the approach to intervention and treatment outcomes.

Many surgeons miss the opportunities offered by the treatment in nasal repair and post-traumatic procedures can be performed inappropriately. Proper management of any nasal injury begins with excellent preoperative screening and accurate diagnosis. Although surgeons expect long-term aesthetic and functional results, damaged septal and cartilage structures may not support this expectation. Given the frequency and difficulty of these reconstructions, surgeons should begin to take these injuries as seriously as other serious conditions in facial trauma.

References

1. Murray JA, Maran AG, Mackenzie IJ, Raab G. Open v closed reduction of the fractured nose. Arch Otolaryngol. 1984;110(12):797-802.
2. Rohrich RJ, Adams WP, Jr. Nasal fracture management: minimizing secondary nasal deformities. Plast Reconstr Surg. 2000;106(2):266-73.
3. Muraoka M, Nakai Y. Twenty years of statistics and observation of facial bone fracture. Acta Otolaryngol Suppl. 1998;538:261-5.
4. Hwang K, You SH, Kim SG, Lee SI. Analysis of nasal bone fractures; a six-year study of 503 patients. J Craniofac Surg. 2006;17(2):261-4.
5. Kang BH, Kang HS, Han JJ, Jung S, Park HJ, Oh HK, et al. A retrospective clinical investigation for the effectiveness of closed reduction on nasal bone fracture. Maxillofac Plast Reconstr Surg. 2019;41(1):53.
6. Andrades P, Pereira N, Rodriguez D, Borel C, Hernández R, Villalobos R. A Five-Year

Retrospective Cohort Study Analyzing Factors Influencing Complications after Nasal Trauma. Craniomaxillofac Trauma Reconstr. 2019;12(3): 175-82.

7. Kucik CJ, Clenney T, Phelan J. Management of acute nasal fractures. Am Fam Physician. 2004;70(7):1315-20.
8. Rubinstein B, Strong EB. Management of nasal fractures. Arch Fam Med. 2000;9(8):738-42.
9. Stranc MF, Robertson GA. A classification of injuries of the nasal skeleton. Ann Plast Surg. 1979;2(6):468-74.
10. Kang CM, Han DG. Objective Outcomes of Closed Reduction According to the Type of Nasal Bone Fracture. Arch Craniofac Surg. 2017;18(1):30-6.
11. Azevedo AB, Trent RB, Ellis A. Population-based analysis of 10,766 hospitalizations for mandibular fractures in California, 1991 to 1993. J Trauma. 1998;45(6):1084-7.
12. Kelley BP, Downey CR, Stal S. Evaluation and reduction of nasal trauma. Semin Plast Surg. 2010;24(4):339-47.

13. Fry H. Nasal skeletal trauma and the interlocked stresses of the nasal septal cartilage. Br J Plast Surg. 1967;20(2):146-58.
14. Vora NM, Fedok FG. Management of the central nasal support complex in naso-orbital ethmoid fractures. Facial Plast Surg. 2000;16(2):181-91.
15. Verwoerd CD. Present day treatment of nasal fractures: closed versus open reduction. Facial Plast Surg. 1992;8(4):220-3.
16. Hinderer KH. Nasal problems in children. Pediatr Ann. 1976;5(8):499-509.
17. Logan M, O'Driscoll K, Masterson J. The utility of nasal bone radiographs in nasal trauma. Clin Radiol. 1994;49(3):192-4.
18. Verwoerd CD, Verwoerd-Verhoef HL. Rhinosurgery in children: basic concepts. Facial Plast Surg. 2007;23(4):219-30.
19. Cook JA, Murrant NJ, Evans K, Lavelle RJ. Manipulation of the fractured nose under local anaesthesia. Clin Otolaryngol Allied Sci. 1992;17(4):337-40.

20. Kim HS, Suh HW, Ha KY, Kim BY, Kim TY. The usefulness of the endonasal incisional approach for the treatment of nasal bone fracture. Arch Plast Surg. 2012;39(3):209-15.
21. Kim NY, Lee SH, Choi HG, Kim SH, Shin DH, Uhm KI. Simultaneous rhinoplasty with fracture reduction in nasal bone fracture. Archives of Plastic Surgery. 2008;35(5):589-96.
22. Fry HJ. Interlocked stresses in human nasal septal cartilage. Br J Plast Surg. 1966;19(3):276-8.
23. Higuera S, Lee EI, Cole P, Hollier LH, Jr., Stal S. Nasal trauma and the deviated nose. Plast Reconstr Surg. 2007;120(7 Suppl 2):64s-75s.
24. KIM J-H, PARK S-H, CHU H-H, CHO J-W, BANG Y-H. The postoperative analysis of closed reducted nasal bone fracture. Journal of the Korean Society of Plastic and Reconstructive Surgeons. 1997:1343-51.
25. Jazbi B. Subluxation of the nasal septum in the newborn: etiology, diagnosis, and treatment. Otolaryngol Clin North Am. 1977;10(1):125-38.
26. Oh H-K, Park Y-J, Kim H-S, Ryu J-Y, Kook M-S, Park H-J, et al. A recent 5-year retrospective study

on nasal bone fracture. Journal of the Korean Association of Oral and Maxillofacial Surgeons. 2008;34(2):230-6.

27. Fornazieri MA, Yamaguti HY, Moreira JH, Navarro PdL, Heshiki RE, Takemoto LE. Fracture of nasal bones: an epidemiologic analysis. Int Arch Otorhinolaryngol. 2008;12(4):498-501.
28. Turvey TA. Midfacial fractures: a retrospective analysis of 593 cases. J Oral Surg. 1977;35(11):887-91.
29. Nishioka H, Kondoh S, Yuzuriha S. Convex bone deformity after closed reduction of nasal bone fracture. J Plast Reconstr Aesthet Surg. 2018;71(1): 85-9.
30. Goode RL, Spooner TR. Management of nasal fractures in children. A review of current practices. Clin Pediatr (Phila). 1972;11(9):526-9.
31. Hwang K, Yeom SH, Hwang SH. Complications of Nasal Bone Fractures. J Craniofac Surg. 2017;28(3):803-5.

32. Escada P. [Localization and distribution of human olfactory mucosa in the nasal cavities]. Acta Med Port. 2013;26(3):200-7.
33. Wrobel BB, Leopold DA. Olfactory and sensory attributes of the nose. Otolaryngol Clin North Am. 2005;38(6):1163-70.
34. Anderson JR. A personal technique of rhinoplasty. Otolaryngol Clin North Am. 1975;8(3):559-62.

İKSAD
Publishing House

ISBN: 978-625-8323-10-8